



PATIENT

Bofors McLamb

SPECIES

Canine

BREED

German Shepherd

SEX

Neutered Male

AGE

3 Years

WEIGHT

83 Pounds

INTERPRETED BY

Eric Lindquist, DMV

DABVP, Cert. IVUSS

IMAGING PERFORMED BY

Dr. Aaron Deml

HOSPITAL NAME

Craig Road AH

REFERRING VET

Dr. Cameron Johnson

INVOICE

46006

DATE

3/17/23

PRESENTING CLINICAL SIGNS

Presenting on Emergency for acute vomiting and diarrhea today. O states that P had D+ a few days ago but it resolved without intervention only to return today. O states that when he returned home this evening P had a pile of vomitus (small amount of food and bile) in his kennel. O let P outside and P drank a good amount of water and then vomited 2x. O immediately brought P in to be seen. O notes P also vomited (bile) during the care ride. P ate normally this morning and is still active/otherwise normal. O states that otherwise P is doing well. Eating, drinking, and urinating within normal limits. No coughing or sneezing noted by owner. No known allergies to vaccines/ medication. P has no recent travel history. Current medications: none

Abnormal PE/Chem/CBC/UA Results: Physical Exam: T - 103.1 F rectal CBC, Chem: - Thrombocytopenia (137x1000/UL)- Ref range 170-400x1000/UL Radiologist report (2-view abdominal radiographs): Assessment: Diffuse splenomegaly. Differentials would include splenitis, splenic infarction, splenic torsion and less likely infiltrative neoplasia. The possibility of a focal splenic mass cannot be totally ruled out. Splenic mass lesions can be associated with benign or malignant disease. Malignant splenic disease would be considered less likely based on the age of the patient. Gastroenterocolitis of undetermined etiology. Gastritis can be associated with splenic abnormality. No identifiable gastrointestinal foreign material is observed. No evidence of gastrointestinal obstruction is observed. The remaining observable intra-abdominal structures are normal. The observable intrathoracic structures are normal. Evidence of degenerative joint disease of the coxofemoral joints based on a partial VD view. A well-positioned VD pelvic legs extended OFA type radiograph would be necessary for more definitive evaluation of the coxofemoral joints. The remaining observable skeletal structures are normal. Comments: The size of the spleen is larger than typically observed with sedation or normal variation. An abdominal ultrasound examination with Doppler examination of the spleen could be utilized for more definitive evaluation.

ULTRASONOGRAPHIC EXAMINATION OF THE ABDOMEN

Urinary System

The **urinary bladder**, trigone, and pelvic urethra presented normal thicknesses and normal tone. The ureters were not visible which is normal. No uroliths or sediment were visualized and anechoic urine was present. No evidence of inflammatory or neoplastic changes were noted. Ureteral papillae were normal.

The **kidneys** revealed normal size and structure, corticomedullary definition and ratio for this age. The cortices presented largely uniform texture with normal echogenic relationship to liver and spleen. Medullary structure differed distinctly from the cortex and no evidence of pelvic dilation was present. The capsules were acceptably uniform without significant irregularities. The left kidney measured 8.1 cm. The right kidney measured 8.1 cm.

Adrenal Glands

The **left adrenal gland** was visualized and recognized as having normal shape, size, position and echogenicity for this breed. The phrenic vasculature, glandular echogenicity and detail were unremarkable. Capsule, cortex, and medullary definition were normal for this age patient. The left adrenal gland measured 0.50 cm.

The region of the **right adrenal gland** was imaged, no evident pathology.

Spleen

The **spleen** was mildly enlarged, uniform. Normal vascularity. No evidence of torsion. The spleen was folded upon itself cranially and caudally. Blood flow to the spleen appeared to be normal.



PATIENT

Liver

Bofors McLamb

The **liver** images submitted revealed subjectively normal liver size, contour, and structure. Parenchymal echogenicity was naturally coarse and hypoechoic to the spleen. Vascular and biliary tracts were of normal volume with no evidence of congestion. Minor gallbladder debris present.

SPECIES

Canine

Gastrointestinal

BREED

German Shepherd

Examination of the **gastrointestinal tract** revealed a stomach and intestine free of stasis, of normal wall thickness, acceptable curvilinear mural detail, and peristaltic activity. Small and large intestine demonstrated normal luminal chyme and stool consistency respectively. No obstructive or overt infiltrative disease was noted. No associated abnormal lymphatic activity was noted.

SEX

Neutered Male

Pancreas

AGE

3 Years

The base and limbs of the **pancreas** were observed to be largely isoechoic to surrounding omental fat. Pancreatic duct and capsular contour were acceptably normal and parenchyma respected normal curvilinear patterns. No overt evidence of active inflammatory or neoplastic disease was noted.

WEIGHT

83 Pounds

ULTRASONOGRAPHIC FINDINGS

- Folded spleen and German Shepherd hypersplenism – This is typical for the breed, however, underlying immune stimulating issue. No evidence of torsion.

INTERPRETATION OF THE FINDINGS & FURTHER RECOMMENDATIONS

INTERPRETED BY

Eric Lindquist, DMV

If the patient is painful upon palpation, consideration for proactive splenectomy could be considered. This may be a pre-torsion state. Cause of immune stimulation such as tick borne disease should be considered. Otherwise, no evidence of pathology.

DABVP, Cert. IVUSS

IMAGING PERFORMED BY

Dr. Aaron Deml

HOSPITAL NAME

Craig Road AH

REFERRING VET

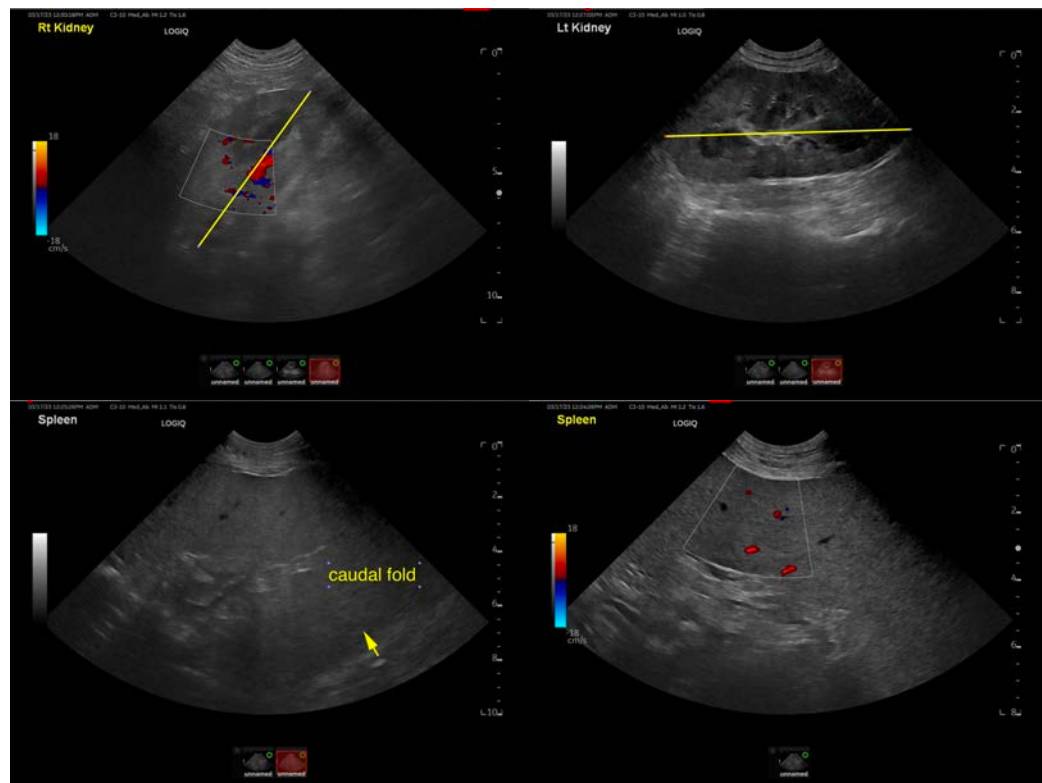
Dr. Cameron Johnson

INVOICE

46006

DATE

3/17/23





PATIENT

Bofors McLamb

SPECIES

Canine

BREED

German Shepherd

SEX

Neutered Male

AGE

3 Years

WEIGHT

83 Pounds

INTERPRETED BY

Eric Lindquist, DMV

DABVP, Cert. IVUSS

IMAGING PERFORMED BY

Dr. Aaron Deml

HOSPITAL NAME

Craig Road AH

REFERRING VET

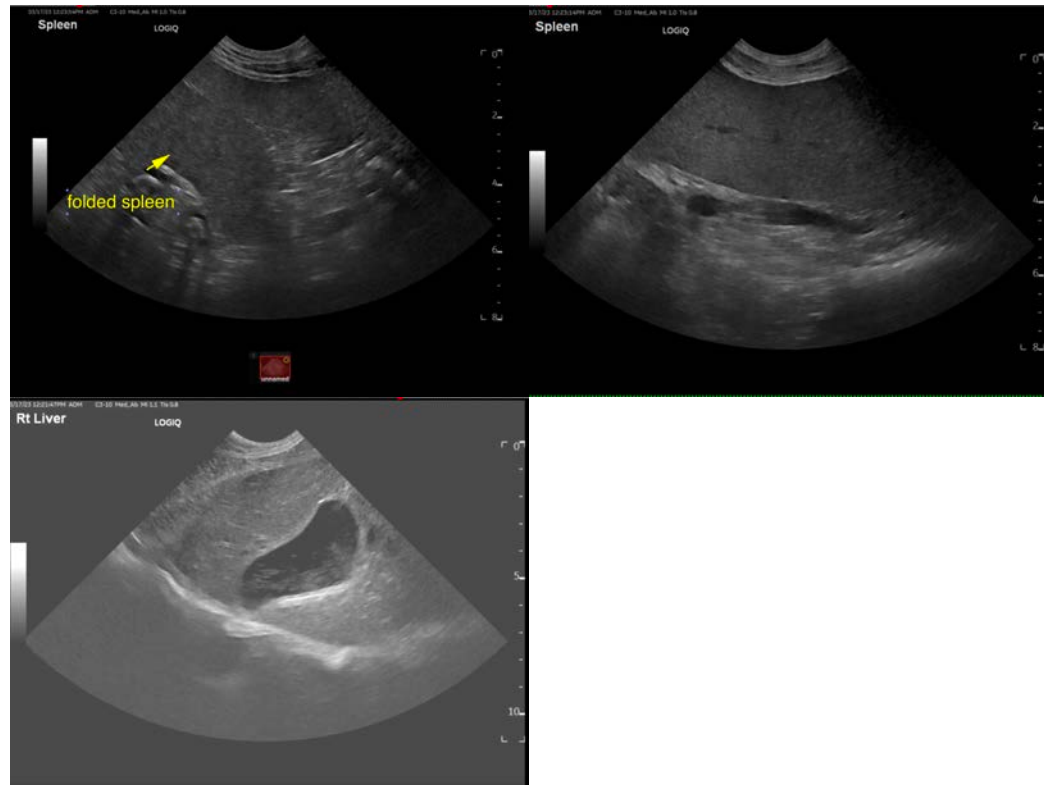
Dr. Cameron Johnson

INVOICE

46006

DATE

3/17/23



The information and recommendations provided are based on the images presented by the referring veterinarian/sonographer. No evaluation can be communicated regarding pathology that was not visible in the image/video clips provided.

Thank you for this referral. If the clinical or image interpretation does not parallel your findings or if I can be of any further assistance please contact me.

Eric Lindquist, DMV, DABVP, Cert. IVUSS, CEO of SonoPath.com

info@SonoPath.com