



PATIENT

Marvin Rosales

SPECIES

Feline

BREED

Russian Blue

SEX

Neutered Male

AGE

12 Years

WEIGHT

12.8 Pounds

PRESENTING CLINICAL SIGNS

Ow states that Marvin was doing well until last night when he suddenly was unable to use both his hind legs. Patient is BAR at presentation, vocalizing a lot, normal bilateral femoral pulses but unable to stand on her pelvic limbs. During PE, patient urinates and defecates on himself. Decreased anal tone. Abnormal PE/Chem/CBC/UA Results: FIV: negative FeLV: negative

ULTRASONOGRAPHIC EXAMINATION OF THE HEART

FELINE CARDIAC PARAMETERS	BODY WEIGHT (kg)	HR (BPM)	IVSd (cm)	LVIDd (cm)	LVWd (cm)	FS (%)	EF (%)
NORMAL PARAMETER	-----	150-240	0.3-0.6	1.0-2.1	0.25-0.6	35-67	80-100
PATIENT		NM	0.8	1.01	0.75	33	68
FELINE CARDIAC PARAMETERS	LA/AO (Boon)	LA/AO HEART BASE (Sisson)	LA 2D 4-chamber long axis AS to FW (Sisson) (cm)		LVOT VEL. (m/s)	RVOT VEL. (m/s)	IVRT (m/)
NORMAL PARAMETER	<1.5	0.88-1.79	0.7-1.7		<1.6	<1.3	40-60
PATIENT	1.2	1.4			1.4		NM
Adapted from June Boon, Veterinary Echocardiography, 1998 Sisson D et al. JVIM 1991; 5: 232, Jacobs et al. Am J Vet Res 1985; 46:1705							

INTERPRETED BY

Eric Lindquist, DMV

DABVP, Cert. IVUSS

IMAGING PERFORMED BY

Dr. Kim

HOSPITAL NAME

Ridgefield Park AH

REFERRING VET

Dr. Kim

INVOICE

36254

DATE

3/17/22

Cardiac Presentation

The echocardiogram in this patient demonstrated normal **left atrial** size based on 3 separate LA measurements. The cranial and caudal **mitral** valve leaflets presented normal linear structure and kinetics. The **left ventricle** presented normal volume and contractility. Minor septal and free wall thickening noted, yet this is not a clinical issue. The **myocardium** presented normal echogenicity without subjective evidence of significant fibrotic or ischemic disease. **Contractility** of the ventricular walls was adequate and in normal range for this patient evidenced by the fractional shortening measurement and subjective evaluation of the different regions and angles of the myocardium. The **left ventricular outflow** tract demonstrated normal laminar flow and subjective structural integrity. The **right atrium** and auricle revealed normal size, structure and content. No evidence of masses was noted or chamber overload. **Tricuspid** valvular assessment demonstrated adequate linear morphology and kinetics. The **right ventricle** was of normal size (1/3 diameter of LV), chordae structure, myocardial echogenicity and thickness. **Pulmonic** tract assessment revealed normal valve structure, laminar flow, and diameter (approx. 1:1 pa/ao ratio). No visible **pericardial** or free pleura fluid was noted or extra cardiac pathology in the visible planes. The cranial **mediastinum** and **pericardial** regions were free of masses in the visible window.

The iliac trifurcation was imaged with normal flow.

ULTRASONOGRAPHIC FINDINGS

- Essentially normal heart with minor left ventricular hypertrophy, consistent with pseudohypertrophy owing to volume contraction, systemic hypertension, hyperthyroid induced cardiomyopathy, yet the left ventricle is only slightly thickened and not a clinical issue.



PATIENT

Marvin Rosales

INTERPRETATION OF THE FINDINGS & FURTHER RECOMMENDATIONS

No evidence of cardiac failure. No evidence of volume overload. Assessment for spinal/neuropathic disease recommended. CT with contrast would be ideal.

SPECIES

Feline

SonoPath CT Services are offered at the Blainstown Animal Hospital. Blainstown animal hospital is just a 30-minute drive west on route 80 from the route 80/287 interchange/Parsippany, New Jersey. More information can be found at:

BREED

Russian Blue

<https://sonopath.com/resources/sonopaths-teleconsultation-services-and-sdep-certification/sonopath-ct-services>

SEX

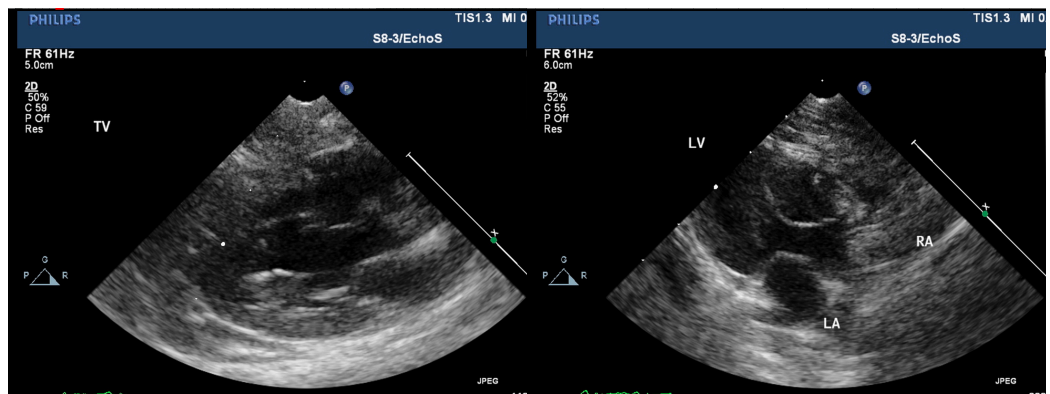
Neutered Male

AGE

12 Years

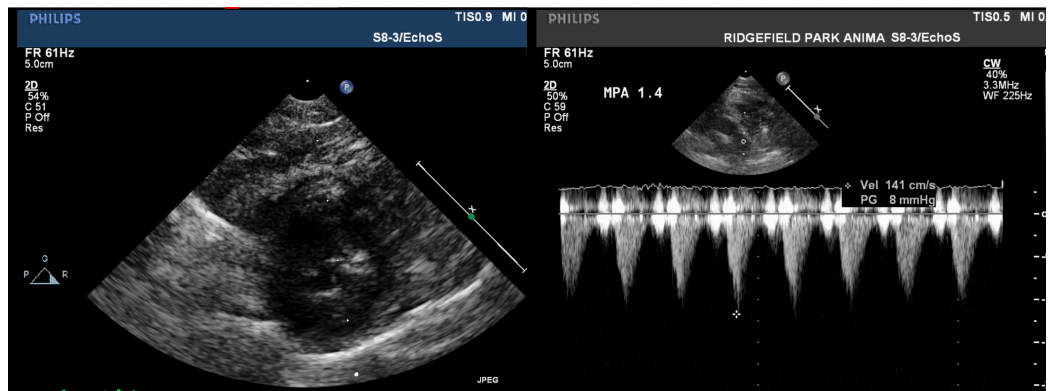
WEIGHT

12.8 Pounds



INTERPRETED BY

Eric Lindquist, DMV



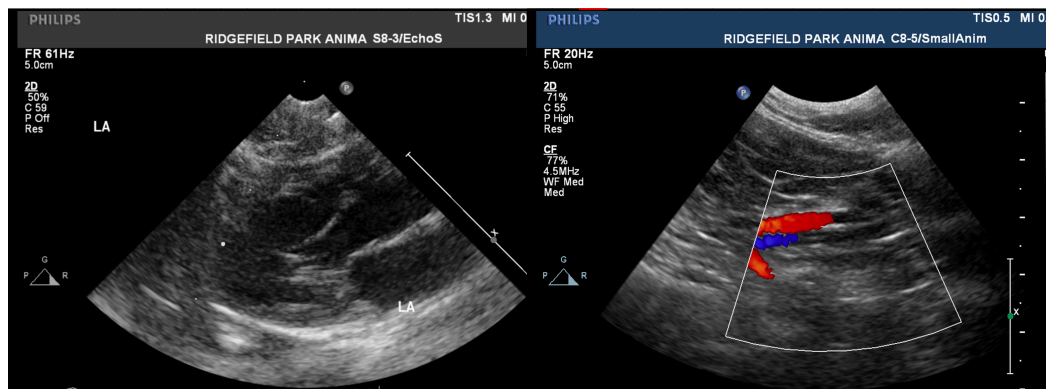
DABVP, Cert. IVUSS

IMAGING PERFORMED BY

Dr. Kim

HOSPITAL NAME

Ridgefield Park AH



REFERRING VET

Dr. Kim

INVOICE

36254

DATE

3/17/22



PATIENT

Marvin Rosales

SPECIES

Feline

BREED

Russian Blue

SEX

Neutered Male

AGE

12 Years

WEIGHT

12.8 Pounds

INTERPRETED BY

Eric Lindquist, DMV

DABVP, Cert. IVUSS

IMAGING PERFORMED BY

Dr. Kim

HOSPITAL NAME

Ridgefield Park AH

REFERRING VET

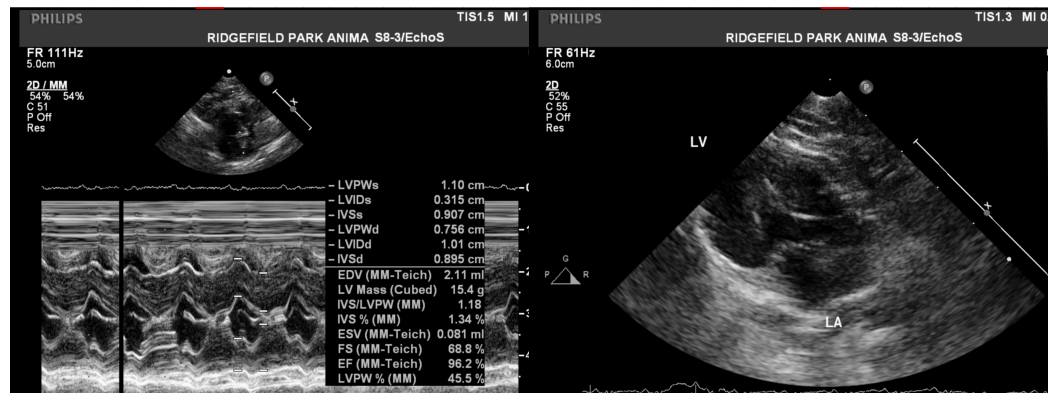
Dr. Kim

INVOICE

36254

DATE

3/17/22



The information and recommendations provided are based on the images presented by the referring veterinarian/sonographer. No evaluation can be communicated regarding pathology that was not visible in the image/video clips provided.

Thank you for this referral. If the clinical or image interpretation does not parallel your findings or if I can be of any further assistance please contact me.

Eric Lindquist, DMV, DABVP, Cert. IVUSS, CEO of SonoPath.com

info@SonoPath.com