

PATIENT PRESENTING CLINICAL SIGNS

Luci Holt Heart Murmur Noted during exam - 2/6 HR - 160

SPECIES ULTRASONOGRAPHIC EXAMINATION OF THE HEART

Feline	FELINE CARDIAC PARAMETERS	BODY WEIGHT (kg)	HR (BPM)	IVSd (cm)	LVIDd (cm)	LVWd (cm)	FS (%)	EF (%)
BREED	NORMAL PARAMETER	-----	150-240	0.3-0.6	1.0-2.1	0.25-0.6	35-67	80-100
DSH	PATIENT		NM	0.5	1.2	0.5	50	
SEX	FELINE CARDIAC PARAMETERS	LA/AO (Boon)	LA/AO HEART BASE (Sisson)	LA 2D 4-chamber long axis AS to FW (Sisson) (cm)		LVOT VEL. (m/s)	RVOT VEL. (m/s)	IVRT (m/)
Intact Male	NORMAL PARAMETER	<1.5	0.88-1.79	0.7-1.7		<1.6	<1.3	40-60
AGE	PATIENT	1.15	1.1			1.4	1.2	NM
10 Weeks	Adapted from June Boon, Veterinary Echocardiography, 1998 Sisson D et al. JVIM 1991; 5: 232, Jacobs et al. Am J Vet Res 1985; 46:1705							
WEIGHT								
4.38 lbs								

Cardiac Presentation

INTERPRETED BY

Eric Lindquist, DMV
DABVP, Cert. IVUSS

The ventricular septum revealed a small defect measuring approximately 2-3 mm with slight vegetative changes. The right atrium was slightly enlarged with 1:1 ratio with left atrium. Tricuspid insufficiency noted. Bi-directional flow was noted in the ventricular septal defect. However, it appears compensated at this time. Occasional arrhythmia noted in this patient.

Hepatic veins were not dilated, no evidence of passive congestion

IMAGING PERFORMED BY

Andrea Nicastro,
DVM, Diplomate
ACVIM (Small Animal
Internal Medicine)

ULTRASONOGRAPHIC FINDINGS

- Compensated small ventricular septal defect with secondary tricuspid insufficiency
- Minor right atrial enlargement

HOSPITAL NAME

Foxbank Vet Hospital

INTERPRETATION OF THE FINDINGS & FURTHER RECOMMENDATIONS

EKG indicated. Recheck echo at 6 months of age as long as no clinical signs are present. There is a chance that the defect may close over time. No treatment warranted unless EKG warrants anti-arrhythmic therapy.

REFERRING VET

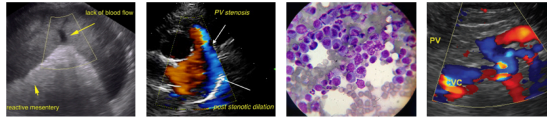
Dr. Winney

INVOICE

36276

DATE

3/17/22



PATIENT

Luci Holt

SPECIES

Feline

BREED

DSH

SEX

Intact Male

AGE

10 Weeks

WEIGHT

4.38 lbs

INTERPRETED BY

Eric Lindquist, DMV

DABVP, Cert. IVUSS

IMAGING PERFORMED BY

Andrea Nicastro,
DVM, Diplomate
ACVIM (Small Animal
Internal Medicine)

HOSPITAL NAME

Foxbank Vet Hospital

REFERRING VET

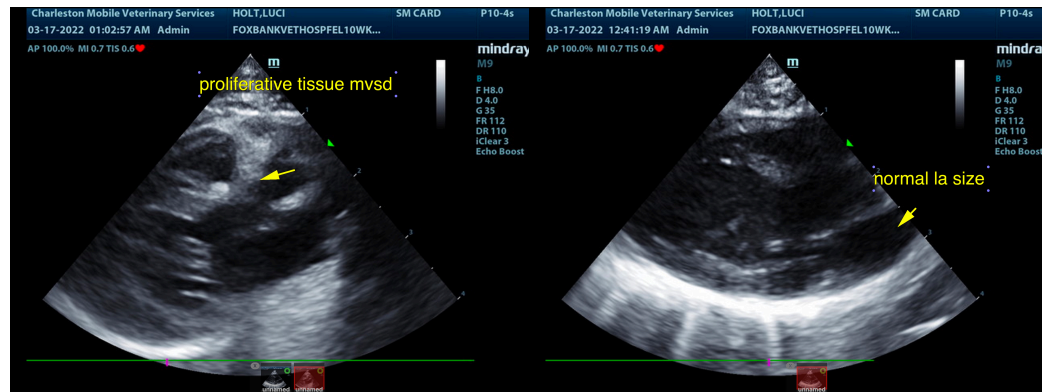
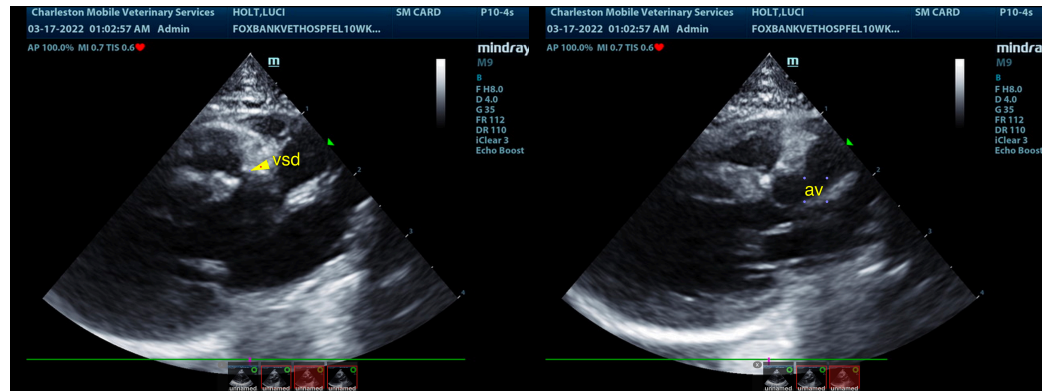
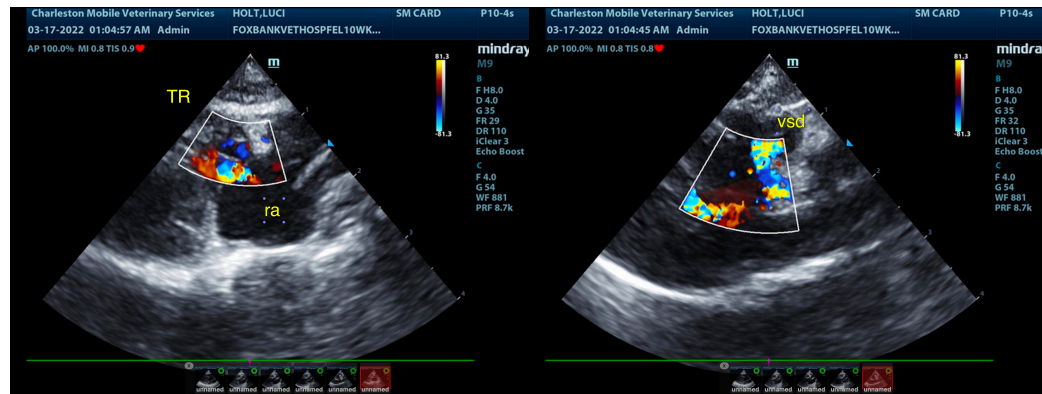
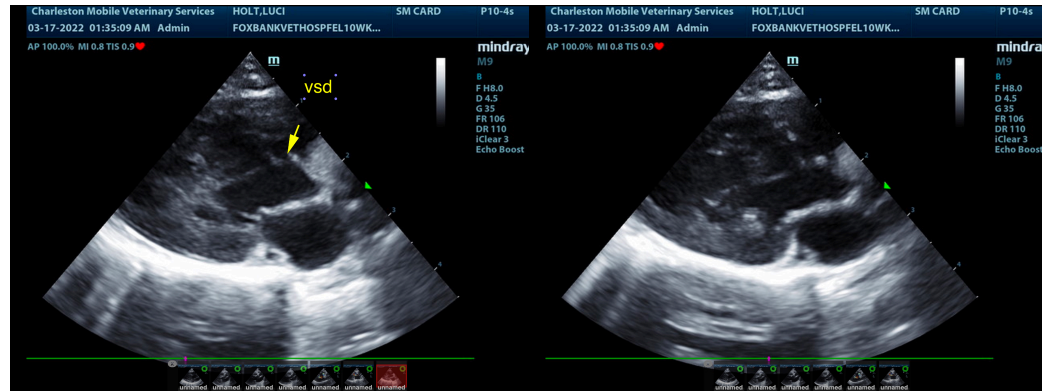
Dr. Winney

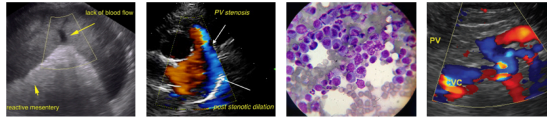
INVOICE

36276

DATE

3/17/22





PATIENT

Luci Holt

SPECIES

Feline

BREED

DSH

SEX

Intact Male

AGE

10 Weeks

WEIGHT

4.38 lbs

INTERPRETED BY

Eric Lindquist, DMV

DABVP, Cert. IVUS

IMAGING PERFORMED BY

Andrea Nicastro,
DVM, Diplomate
ACVIM (Small Animal
Internal Medicine)

HOSPITAL NAME

Foxbank Vet Hospital

REFERRING VET

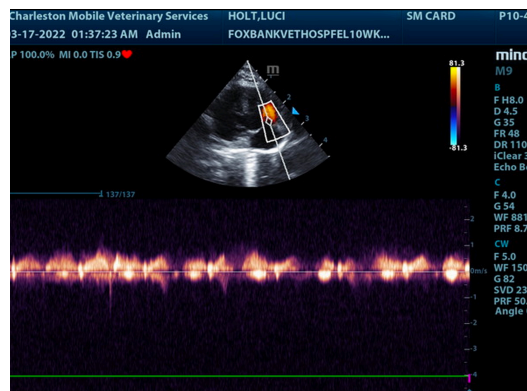
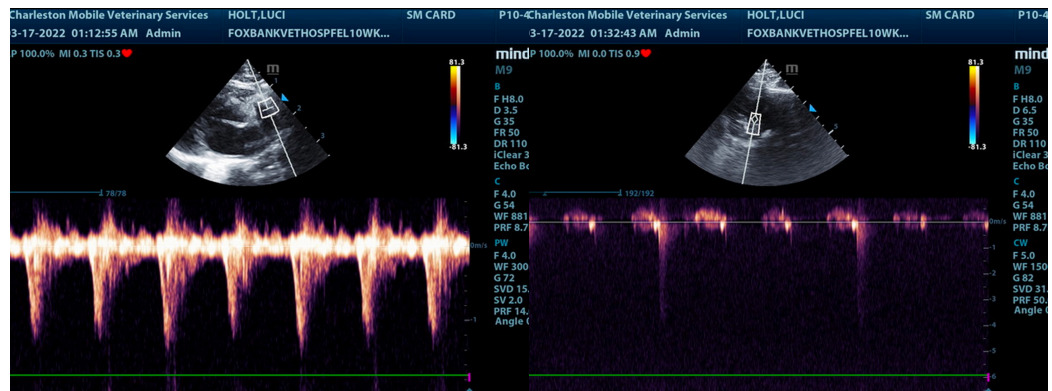
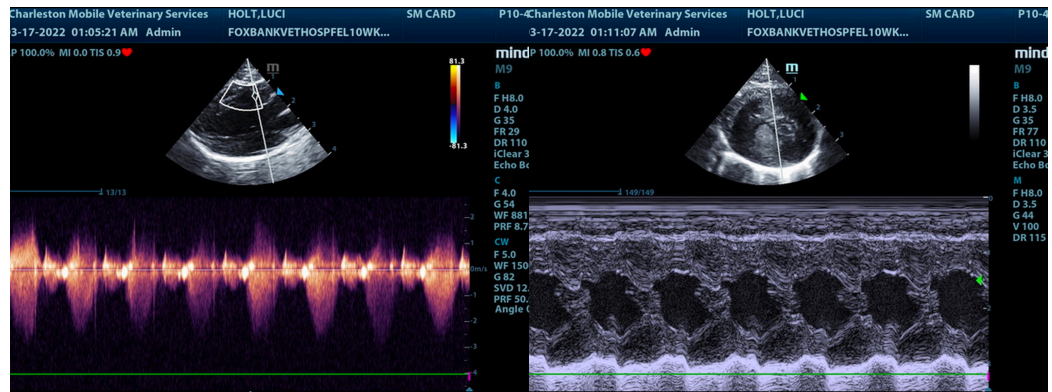
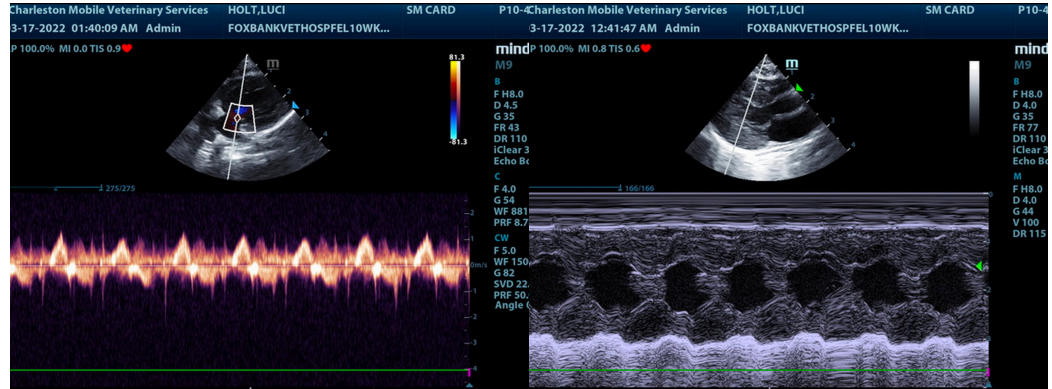
Dr. Winney

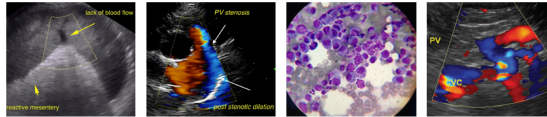
INVOICE

36276

DATE

3/17/22





PATIENT

Luci Holt

The information and recommendations provided are based on the images presented by the referring veterinarian/sonographer. No evaluation can be communicated regarding pathology that was not visible in the image/video clips provided.

SPECIES

Feline

Thank you for this referral. If the clinical or image interpretation does not parallel your findings or if I can be of any further assistance please contact me.

Eric Lindquist, DMV, DABVP, Cert. IVUSS, CEO of SonoPath.com

BREED

DSH

info@SonoPath.com

SEX

Intact Male

AGE

10 Weeks

WEIGHT

4.38 lbs

INTERPRETED BY

Eric Lindquist, DMV

DABVP, Cert. IVUSS

IMAGING PERFORMED BY

Andrea Nicastro,
DVM, Diplomate
ACVIM (Small Animal
Internal Medicine)

HOSPITAL NAME

Foxbank Vet Hospital

REFERRING VET

Dr. Winney

INVOICE

36276

DATE

3/17/22