



PATIENT

Corky Landers

SPECIES

Canine

BREED

Poodle

SEX

Male

AGE

2 years

WEIGHT

5.5 kg

INTERPRETED BY

Eric Lindquist, DMV
DABVP, Cert. IVUSS

IMAGING PERFORMED BY

Dr. Ebert

HOSPITAL NAME

Wilvet Salem

REFERRING VET

Dr. Ebert

INVOICE

96956

DATE

3/17/22

PRESENTING CLINICAL SIGNS

History: Pet has been vomiting for the last 2 days, not eating. Vomited 6 times yesterday and 4 times today. Ate a little yesterday but didn't keep it down. Diarrhea Sunday but none since. Boarded over the weekend. rDVM took rads before transfer - no obvious obstruction/also completed similar episode 1 year ago except diarrhea, checked for Addison's - normal. put on Purina HA hydrolyzed diet, didn't like to eat it, lost some weight. very picky eater at home - different ate new food well but then started vomiting 2 days later, this was 2-3 weeks ago. chicken and rice eating that until yesterday. still drinking. due for Bordetella vax, otherwise up to date.

Abnormal PE/Chem/CBC/UA Results: CBC+Ch10 - PCV 59%, K 6.5*, Na 155_

ULTRASONOGRAPHIC EXAMINATION OF THE ABDOMEN

Urinary System

The **urinary bladder**, trigone, and pelvic urethra presented normal thicknesses and normal tone. The ureters were not visible which is normal. No uroliths or sediment were visualized and anechoic urine was present. No evidence of inflammatory or neoplastic changes was noted. Ureteral papillae were normal.

The **kidneys** revealed normal size and structure, corticomedullary definition and ratio for this age. The cortices presented largely uniform texture with normal echogenic relationship to liver and spleen. Medullary structure differed distinctly from the cortex and no evidence of pelvic dilation was present. The capsules were acceptably uniform without significant irregularities. The left kidney measured 4.0 cm. The right kidney measured 4.0 cm.

Adrenal Glands

Both **adrenal glands** were visualized and recognized as having normal shape, size, position and echogenicity for this breed. The phrenic vasculature, glandular echogenicity and detail were unremarkable. Capsule, cortex, and medullary definition were normal for this age patient. The left adrenal gland measured 0.3 cm.

Spleen

The **spleen** presented a smooth homogeneous parenchyma hyperechoic to liver and renal cortical parenchyma. The capsule was smooth without noticeable expansion or deviation from within the spleen or adjacent pathology. The splenic vasculature demonstrated normal volume without signs of congestion or thrombosis. No sonographic evidence of acute or chronic inflammatory, neoplastic, or infarctual changes was noted.

Liver

The **liver** images submitted revealed subjectively normal liver size, contour, and structure. Parenchymal echogenicity was naturally coarse and hypoechoic to the spleen. Vascular and biliary tracts were of normal volume with no evidence of congestion. The gallbladder presented acceptably thin walls with primarily anechoic content. The cystic and common bile ducts were normal. No pathological hepatic



PATIENT

lymphadenopathy was evident. No overt structural evidence of inflammatory, infiltrative or regenerative pathology was evident.

Corky Landers

SPECIES

Gastrointestinal

Canine

The **gastrointestinal tract** revealed an edematous wall and hyperperistalsis with no loss of mural detail. Minor enhanced surrounding fat was noted around the regions of the gastrointestinal serosa. There was no evidence of foreign body or neoplastic criteria. Images from the stomach, small intestine and colon were presented. This is most consistent with gastroenteritis owing to viral, bacterial/endotoxin or possible parasitic disease.

BREED

Poodle

SEX

Pancreas

Male

The base and limbs of the **pancreas** were observed to be largely isoechoic to surrounding omental fat. Pancreatic duct and capsular contour were acceptably normal and parenchyma respected normal curvilinear patterns. No overt evidence of active inflammatory or neoplastic disease was noted.

AGE

2 years

ULTRASONOGRAPHIC FINDINGS

WEIGHT

Gastroenteritis.

5.5 kg

No evidence of foreign bodies.

INTERPRETED BY

INTERPRETATION OF THE FINDINGS & FURTHER RECOMMENDATIONS

Eric Lindquist, DMV
DABVP, Cert. IVUSS

Dietary indiscretion, food intolerance/indiscretion, structurally insignificant inflammatory bowel or occult parasitism and occult Addison's are all potentials.

IMAGING PERFORMED BY

Dr. Ebert

HOSPITAL NAME

Wilvet Salem

REFERRING VET

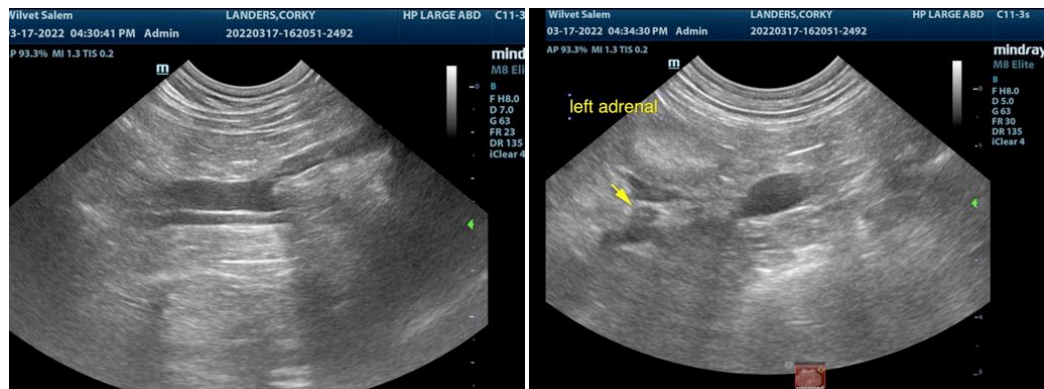
Dr. Ebert

INVOICE

96956

DATE

3/17/22





PATIENT

Corky Landers

SPECIES

Canine

BREED

Poodle

SEX

Male

AGE

2 years

WEIGHT

5.5 kg

INTERPRETED BY

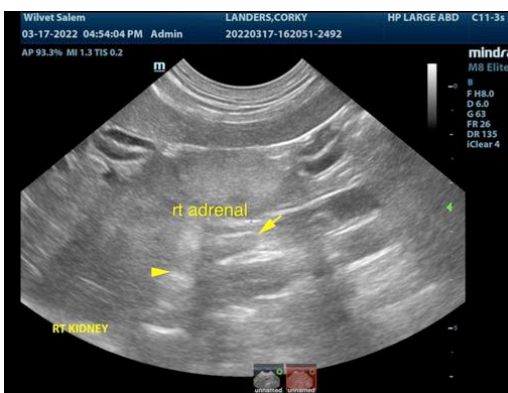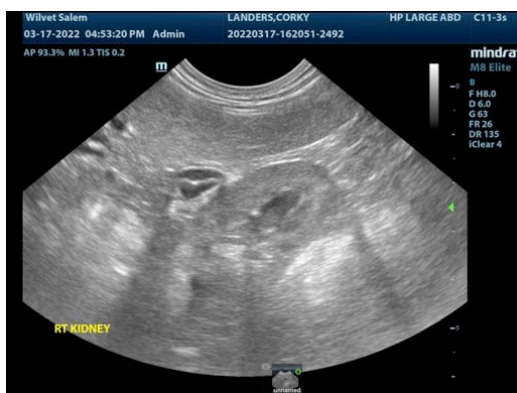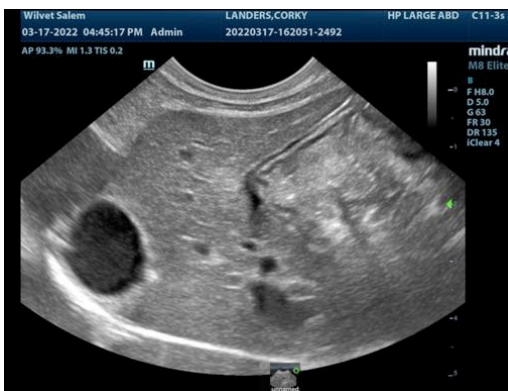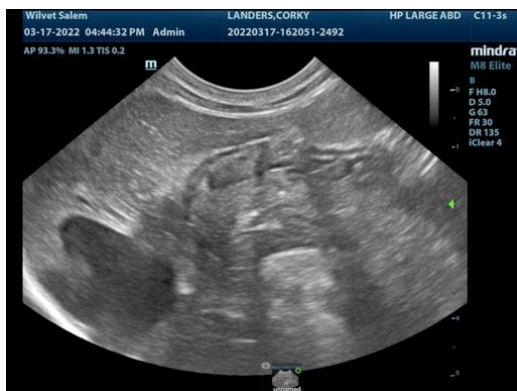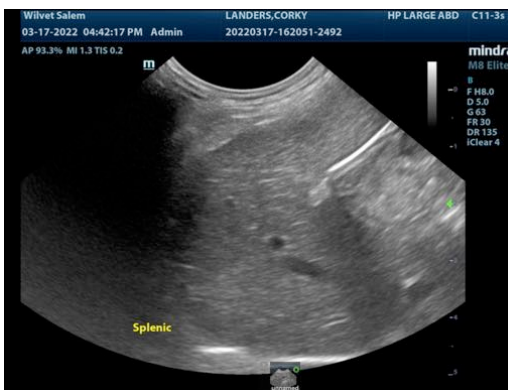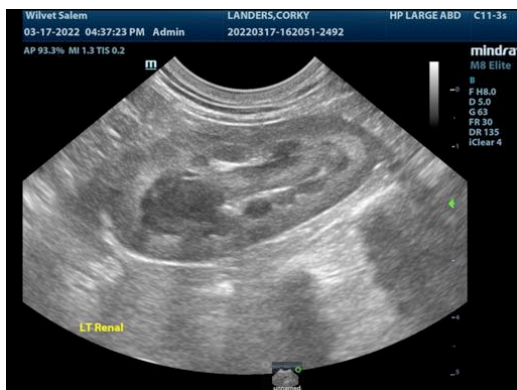Eric Lindquist, DMV
DABVP, Cert. IVUSS

IMAGING PERFORMED BY

Dr. Ebert

HOSPITAL NAME

Wilvet Salem



REFERRING VET

Dr. Ebert

INVOICE

96956

DATE

3/17/22

The information and recommendations provided are based on the images presented by the referring veterinarian/sonographer. No evaluation can be communicated regarding pathology that was not visible in the image/video clips provided.

Thank you for this referral. If the clinical or image interpretation does not parallel your findings or if I can be of any further assistance please contact me.

Eric Lindquist, DMV, DABVP, Cert. IVUSS, CEO of SonoPath.com
info@SonoPath.com