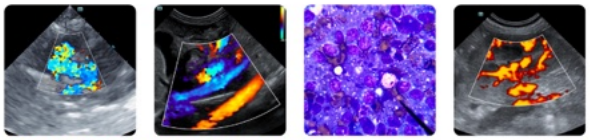

PATIENT
Twilight Mosser

SPECIES
Feline

BREED
Domestic Shorthair

SEX
Spayed female

AGE
15 years

WEIGHT
31.5 lbs

INTERPRETED BY
Eric Lindquist, DMV
DABVP, Cert. IVUSS

IMAGING PERFORMED BY
Dr. Ammeraal

HOSPITAL NAME
Sova

REFERRING VET
Dr. Ammeraal

INVOICE
73447

DATE
3/16/26

PRESENTING CLINICAL SIGNS

Presenting for weight loss and lethargy

Exam,- grade 3/6 murmur. CBC - plt 133 (L but adequate), neuts 8850 (H), monos 2700 (H), eos 1200 (H)
Chem - tbili 1.3 (H), ALP 159 (H), alb 2.4 (H), SDMA 32.4 (H), icteric serum TT4 0.7, UA 1+ bili

ULTRASONOGRAPHIC EXAMINATION OF THE ABDOMEN

Urinary System

The **urinary bladder**, trigone, and pelvic urethra presented normal thicknesses and normal tone. The ureters were not visible which is normal. No uroliths or sediment were visualized and anechoic urine was present. No evidence of inflammatory or neoplastic changes was noted. Ureteral papillae were normal.

The **kidneys** revealed largely normal structure, corticomedullary definition and ratio (cortex 1/3 of medulla) were essentially maintained with some age-related loss of curvilinear patterns regarding the capsule and C/M junction. The cortices presented largely uniform texture with some increased echogenicity expected for this age patient. Medullary structure differed distinctly from that of the cortex and no evidence of pelvic dilation was present. The left kidney was normal in size and measured 3.2 cm. The right kidney was subnormal in size and measured 2.7 cm.

Adrenal Glands

Both **adrenal glands** were visualized and recognized as having normal shape, size, position and echogenicity for this breed. The phrenic vasculature, glandular echogenicity and detail were unremarkable. Capsule, cortex, and medullary definition were normal for this age patient. The left adrenal gland measured 0.4 cm. The right adrenal gland measured

Spleen

The **spleen** was enlarged and hypoechoic with scalloping contour. The spleen measured up to 1.4 cm in width.

Liver

The **liver** was diffusely enlarged with mixed, hyperechoic parenchymal change with coarse architecture. The gallbladder presented acceptably thin walls with primarily anechoic content. The cystic and common bile ducts were normal. No pathological hepatic lymphadenopathy was evident.

PATIENT

Twilight Mosser

SPECIES

Feline

BREED

Domestic Shorthair

SEX

Spayed female

AGE

15 years

WEIGHT

31.5 lbs

INTERPRETED BY

Eric Lindquist, DMV
DABVP, Cert. IVUSS

IMAGING PERFORMED BY

Dr. Ammeraal

HOSPITAL NAME

Sova

REFERRING VET

Dr. Ammeraal

INVOICE

73447

DATE

3/16/26

Gastrointestinal

The **gastrointestinal** presentation revealed mild uniform prominence of the gastric mucosa as well as areas of "ropey" small intestinal wall with slight disruption of the normal 1:3 muscularis/mucosal ratio. The intestinal submucosa was slightly irregular, thickened and hyperechoic suggestive of low grade, chronic disease. Multiple mesenteric lymph nodes were enlarged, rounded and hypoechoic measuring 0.7 cm. The surrounding fat was hyperechoic.

Pancreas

The visible **pancreas** was observed to be largely isoechoic to surrounding omental fat. Pancreatic duct and capsular contour were acceptably normal and parenchyma respected normal curvilinear patterns. No overt evidence of active inflammatory or neoplastic disease was noted.

ULTRASONOGRAPHIC FINDINGS

Splenohepatomegaly with mesenteric lymphadenopathy.

IBD GI pattern with reactive mesentery that obscured portions of the pancreas.

INTERPRETATION OF THE FINDINGS & FURTHER RECOMMENDATIONS

Some level of pancreatic inflammation is likely, yet not a primary issue. There is a strong concern for round cell neoplasia. Coagulation panel and 25-gauge FNA of the spleen, liver and accessible lymph ondes is indicated. Chest radiographs are recommended to assess for metastatic disease.

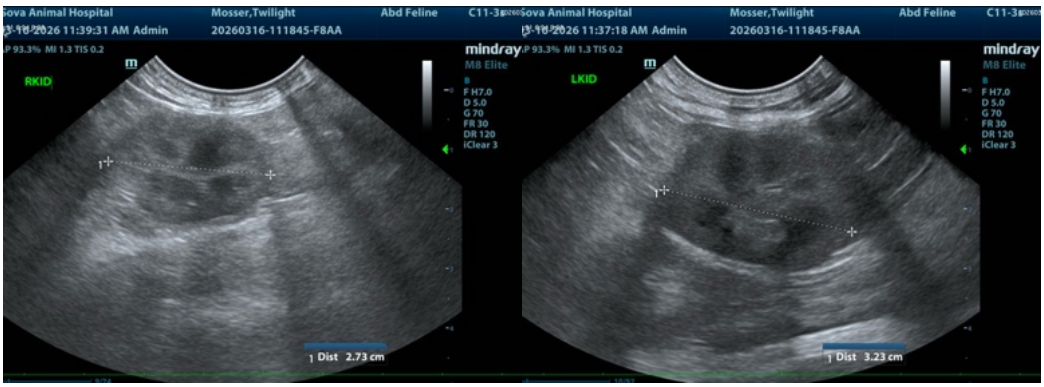

SonoPath

FOSTERING THE ART OF VETERINARY MEDICINE™

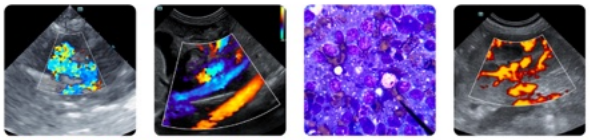

Clinical Sonography & Telecytology

Educational Teleconsultation Services™

SonoPath.com info@sonopath.com 1.800.838.4268

PATIENT

Twilight Mosser

SPECIES

Feline

BREED

Domestic Shorthair

SEX

Spayed female

AGE

15 years

WEIGHT

31.5 lbs

INTERPRETED BY

Eric Lindquist, DMV
DABVP, Cert. IVUSS

IMAGING PERFORMED BY

Dr. Ammeraal

HOSPITAL NAME

Sova

REFERRING VET

Dr. Ammeraal

INVOICE

73447

DATE

3/16/26

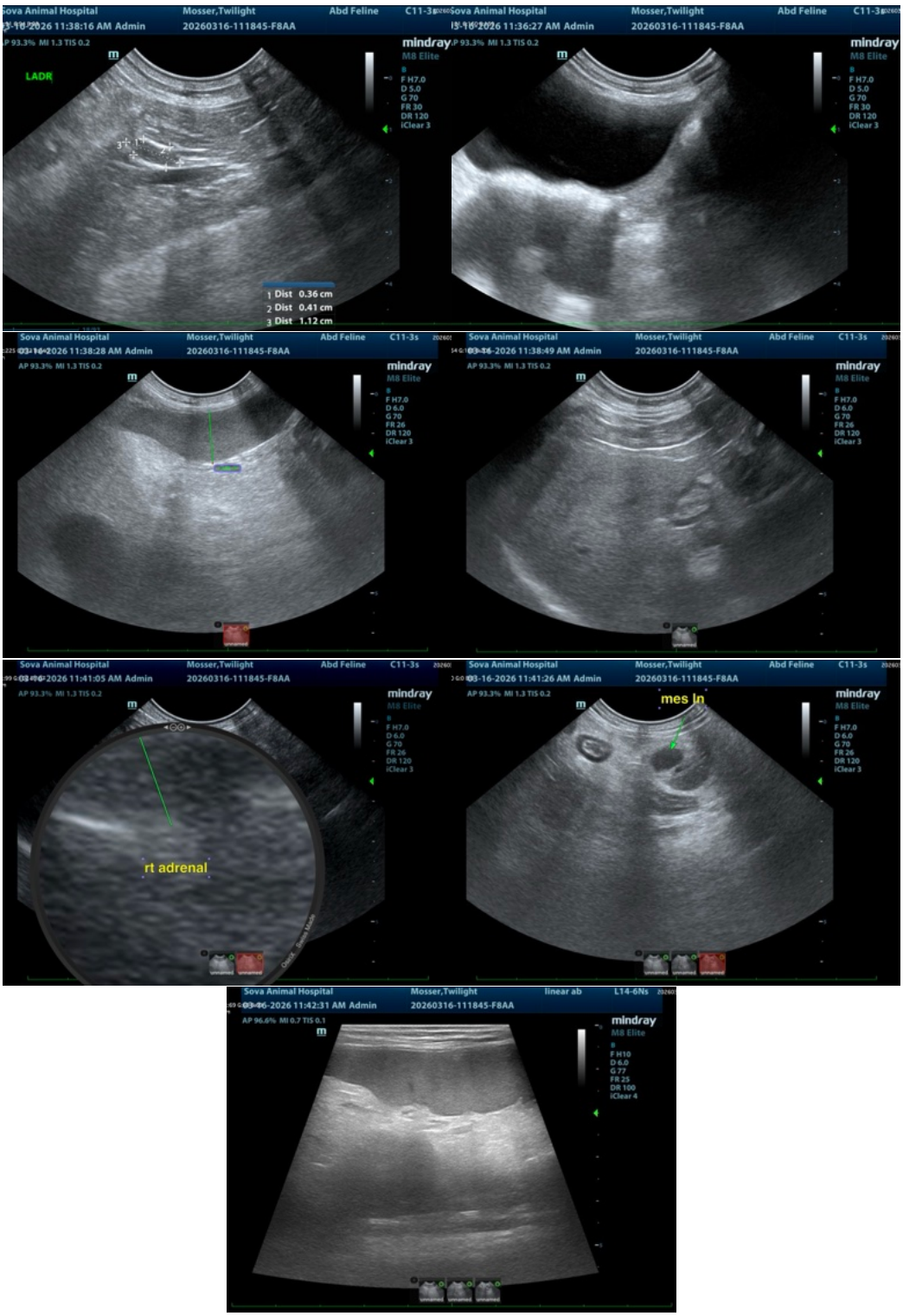

The information and recommendations provided are based on the images presented by the

PATIENT

Twilight Mosser

SPECIES

Feline

BREED

Domestic Shorthair

SEX

Spayed female

AGE

15 years

WEIGHT

31.5 lbs

INTERPRETED BY

Eric Lindquist, DMV
DABVP, Cert. IVUSS

IMAGING PERFORMED BY

Dr. Ammeraal

HOSPITAL NAME

Sova

REFERRING VET

Dr. Ammeraal

INVOICE

73447

DATE

3/16/26

referring veterinarian/sonographer. No evaluation can be communicated regarding pathology that was not visible in the image/video clips provided.

Thank you for this referral. If the clinical or image interpretation does not parallel your findings or if I can be of any further assistance please contact me.

Eric Lindquist, DMV, DABVP (CFM), Cert. IVUSS, CEO of SonoPath.com

info@SonoPath.com