



PATIENT PRESENTING CLINICAL SIGNS

Elsa Dubie History: decreased appetite few weeks, progressed to inappetence
Abnormal PE/Chem/CBC/UA Results: TP 7.9 ALB 2.3 Glob 5.6 ALB:Glob 0.4 Amylase 1620 CK 201
Urine 10-15 WBC/hpf Anaplasma pos. pending maldigestion profile and resting cortisol

SPECIES

Canine

ULTRASONOGRAPHIC EXAMINATION OF THE ABDOMEN

BREED

Golden Doodle

Urinary System

The **urinary bladder**, trigone, and pelvic urethra presented normal thicknesses and normal tone. The ureters were not visible which is normal. No uroliths or sediment were visualized and anechoic urine was present. No evidence of inflammatory or neoplastic changes was noted. Ureteral papillae were normal.

SEX

Spayed female

AGE

9 years

The **kidneys** revealed normal size and structure, corticomedullary definition and ratio for this age. The cortices presented largely uniform texture with normal echogenic relationship to liver and spleen. Medullary structure differed distinctly from the cortex and no evidence of pelvic dilation was present. The capsules were acceptably uniform without significant irregularities. The left kidney measured 6.53 cm. The right kidney measured 7.82 cm with an anechoic cyst in the right kidney measuring

WEIGHT

37.5 lbs

Adrenal Glands

Both **adrenal glands** were visualized and recognized as having normal shape, size, position and echogenicity for this breed. The phrenic vasculature, glandular echogenicity and detail were unremarkable. Capsule, cortex, and medullary definition were normal for this age patient. The left adrenal gland measured 0.5 cm. The right adrenal gland measured 0.8 cm in maximum width.

INTERPRETED BY

Eric Lindquist, DMV
DABVP, Cert. IVUSS

IMAGING PERFORMED BY

Dr. Striano Kaplan

Spleen

The **spleen** was mildly enlarged and folded upon itself cranially with slight scalloping contour.

HOSPITAL NAME

Ramsey VH

Liver

The **liver** was enlarged and irregular in contour with a hypoechoic parenchyma. Increased portal markings were present. The gallbladder and common bile duct were unremarkable.

REFERRING VET

Dr. Striano Kaplan

Gastrointestinal

INVOICE

43328

Examination of the **gastrointestinal tract** revealed a stomach and intestine free of stasis, of normal wall thickness, acceptable curvilinear mural detail, and peristaltic activity. Variable intestinal thickening was noted.

DATE

3/16/23



PATIENT

Pancreas

Elsa Dubie

The base and limbs of the **pancreas** were observed to be largely isoechoic to surrounding omental fat. Pancreatic duct and capsular contour were acceptably normal and parenchyma respected normal curvilinear patterns. No overt evidence of active inflammatory or neoplastic disease was noted.

SPECIES

Canine

Free Abdomen

BREED

Golden Doodle

Free fluid was noted in the cranial abdomen with reactive mesentery. Slight areas of free fluid were noted as well as hypoechoic, nodular changes.

SEX

Spayed female

ULTRASONOGRAPHIC FINDINGS

Splenohepatomegaly with reactive mesentery and free fluid in the cranial abdomen.

Minor intestinal thickening.

AGE

9 years

Right renal cyst.

WEIGHT

37.5 lbs

INTERPRETATION OF THE FINDINGS & FURTHER RECOMMENDATIONS

Strong concern for round cell neoplasia. FNA of the spleen and liver is recommended.

INTERPRETED BY

Eric Lindquist, DMV
DABVP, Cert. IVUSS

IMAGING PERFORMED BY

Dr. Striano Kaplan

HOSPITAL NAME

Ramsey VH

REFERRING VET

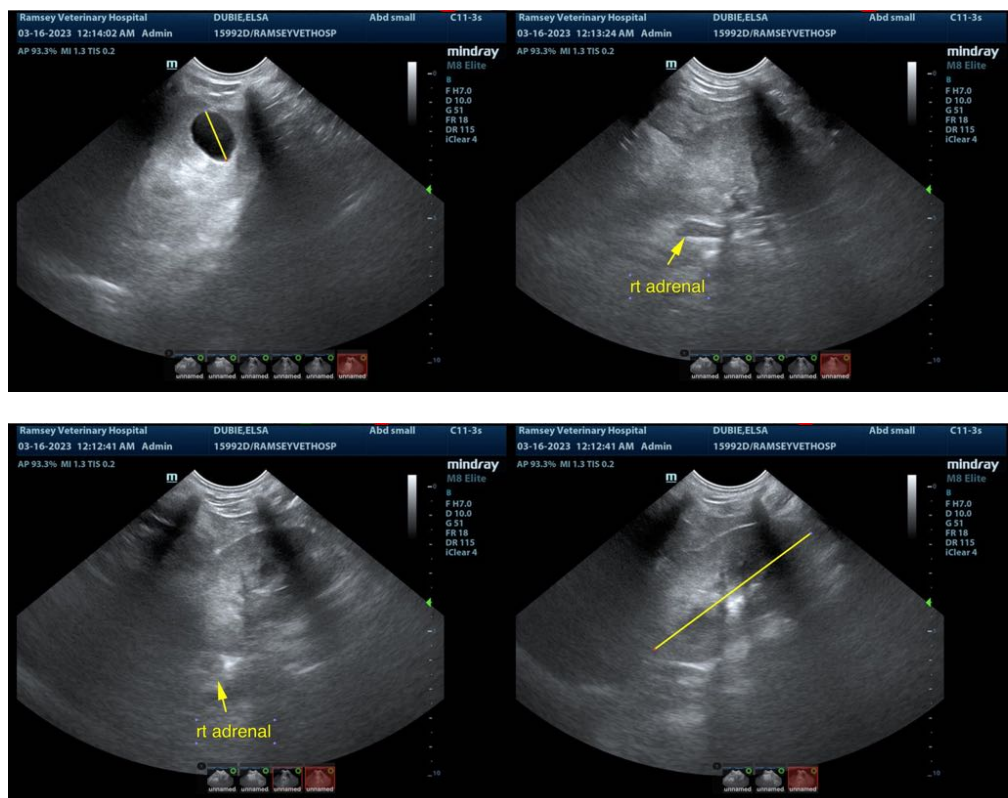
Dr. Striano Kaplan

INVOICE

43328

DATE

3/16/23





PATIENT

Elsa Dubie

SPECIES

Canine

BREED

Golden Doodle

SEX

Spayed female

AGE

9 years

WEIGHT

37.5 lbs

INTERPRETED BY

Eric Lindquist, DMV
DABVP, Cert. IVUS

IMAGING PERFORMED BY

Dr. Striano Kaplan

HOSPITAL NAME

Ramsey VH

REFERRING VET

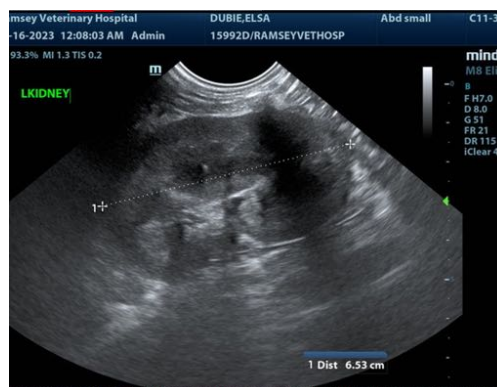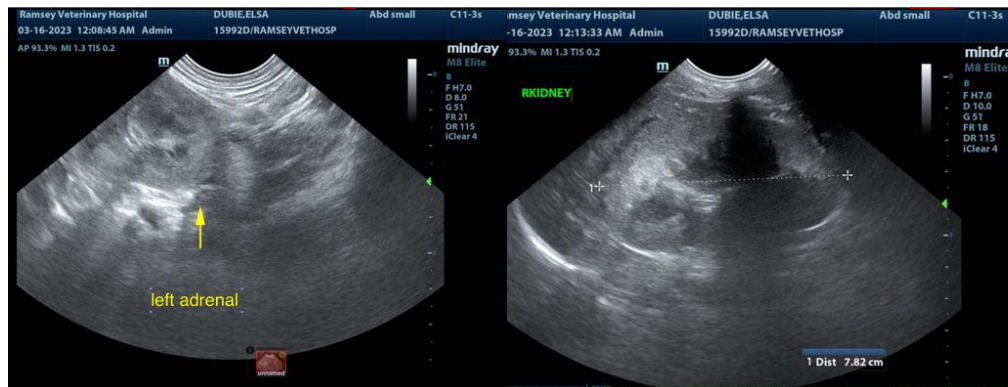
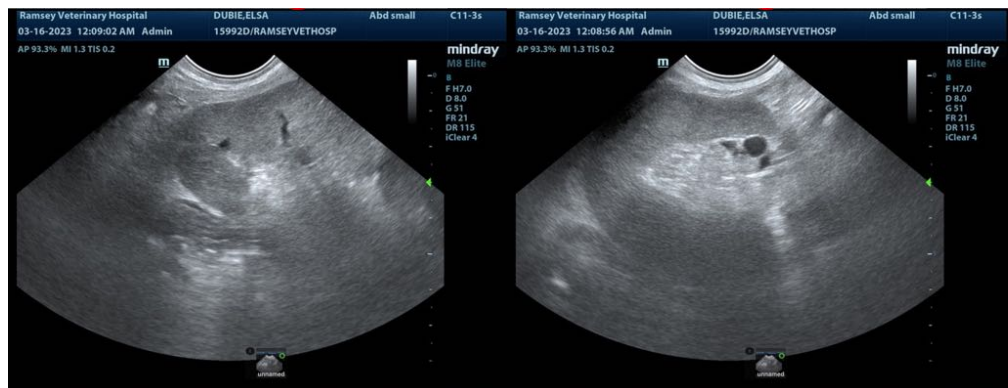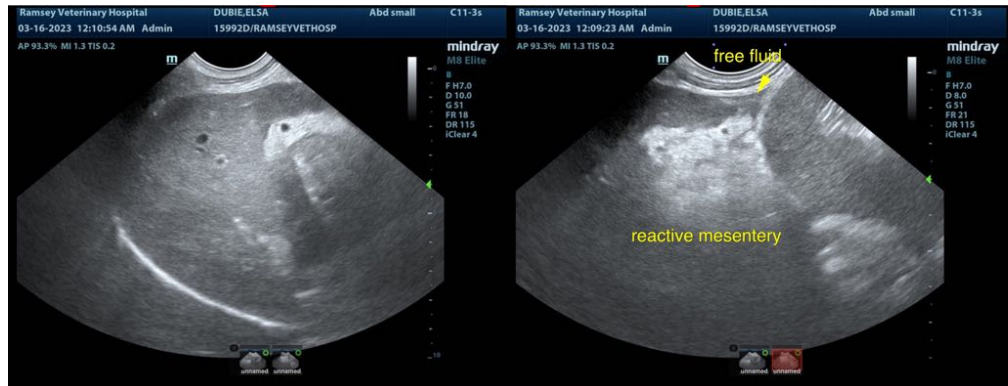
Dr. Striano Kaplan

INVOICE

43328

DATE

3/16/23





PATIENT

Elsa Dubie

The information and recommendations provided are based on the images presented by the referring veterinarian/sonographer. No evaluation can be communicated regarding pathology that was not visible in the image/video clips provided.

SPECIES

Canine

Thank you for this referral. If the clinical or image interpretation does not parallel your findings or if I can be of any further assistance please contact me.

BREED

Golden Doodle

Eric Lindquist, DMV, DABVP, Cert. IVUSS, CEO of SonoPath.com
info@SonoPath.com

SEX

Spayed female

AGE

9 years

WEIGHT

37.5 lbs

INTERPRETED BY

Eric Lindquist, DMV
DABVP, Cert. IVUSS

**IMAGING
PERFORMED BY**

Dr. Striano Kaplan

HOSPITAL NAME

Ramsey VH

REFERRING VET

Dr. Striano Kaplan

INVOICE

43328

DATE

3/16/23