



PATIENT

Zeke Conti

PRESENTING CLINICAL SIGNS

History: evaluation of possible cranial tracheal mass noted on rads vs fat. FNA if warranted. On vetmedin.

SPECIES

Canine

ULTRASONOGRAPHIC EXAMINATION OF THE THORAX

The cranial thorax was imaged in this patient with 5-6 cm lipoma noted. This is a fat density. There was no evidence of underlying pathology. Regional vasculature was unremarkable. The cranial mediastinum was imaged with a large amount of fat noted in this region as well. The regions of the cranial thorax and trachea were imaged in multiple views. There was no evidence of pathology. A large lipoma was noted in the region with only fat densities. The esophagus was imaged and uniform with no evidence of pathology. Acoustic air interference was noted, which is consistent with normal trachea.

BREED

German Shepherd Mix

SEX

Neutered male

ULTRASONOGRAPHIC FINDINGS

Changes on radiographs consistent with lipoma and fat deposits and reflected on the ultrasound.

AGE

13 years

INTERPRETATION OF THE FINDINGS & FURTHER RECOMMENDATIONS

If respiratory or upper esophageal signs are present in this patient then endoscopy would be appropriate or CT of the region, yet there was no evidence of pathology.

WEIGHT

64 lbs

ABOUT SONOPATH CT SERVICES:

SonoPath CT Services are offered at the [Blairstown Animal Hospital](#). Blairstown, New Jersey. More information can be found at

<https://sonopath.com/resources/sonopaths-teleconsultation-services-and-sdep-certification/sonopath-ct-services>

INTERPRETED BY

Eric Lindquist, DMV
DABVP, Cert. IVUSS

IMAGING PERFORMED BY

Diane McFadden, RVT

HOSPITAL NAME

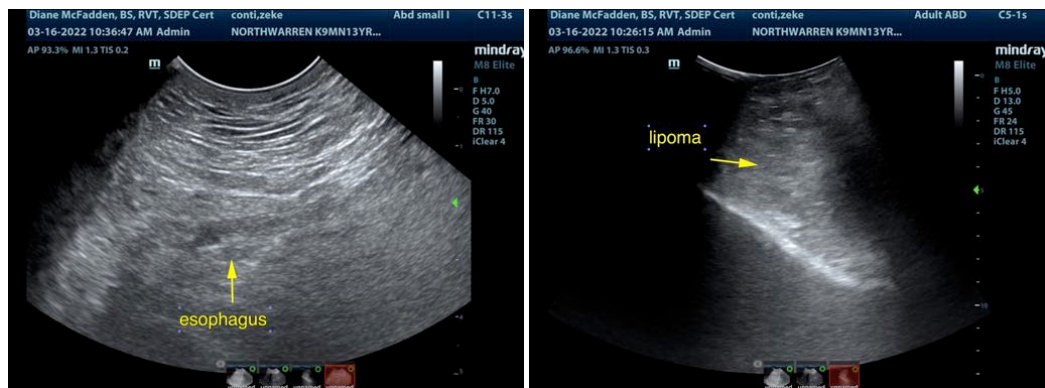
North Warren AH

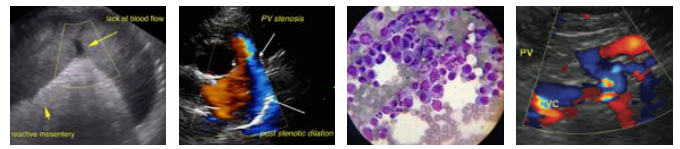
INVOICE

96919

DATE

3/11/22





PATIENT

Zeke Conti

SPECIES

Canine

BREED

German Shepherd Mix

SEX

Neutered male

AGE

13 years

WEIGHT

64 lbs

INTERPRETED BY

Eric Lindquist, DMV
DABVP, Cert. IVUSS

IMAGING PERFORMED BY

Diane McFadden, RVT

HOSPITAL NAME

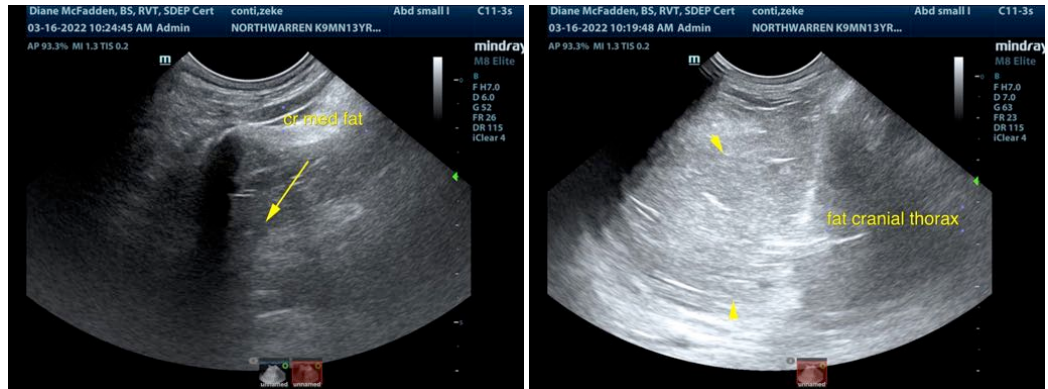
North Warren AH

INVOICE

96919

DATE

3/11/22



The information and recommendations provided are based on the images presented by the referring veterinarian/sonographer. No evaluation can be communicated regarding pathology that was not visible in the image/video clips provided.

Thank you for this referral. If the clinical or image interpretation does not parallel your findings or if I can be of any further assistance please contact me.

Eric Lindquist, DMV, DABVP, Cert. IVUSS, CEO of SonoPath.com
Info@SonoPath.com