



PATIENT

Rhiannon Burley

SPECIES

Canine

BREED

Collie

SEX

Spayed Female

AGE

9 Years

WEIGHT

33.4 kg

INTERPRETED BY

Eric Lindquist, DMV
DABVP, Cert. IVUSS

IMAGING PERFORMED BY

Dr. Trudeau

HOSPITAL NAME

Petworks VH

REFERRING VET

Dr. Trudeau

INVOICE

36220

DATE

3/16/22

PRESENTING CLINICAL SIGNS

hematuria for at least 2 weeks; no pu/pd. no stranguria, no pollakiuria
Abnormal PE/Chem/CBC/UA Results: U/A - unremarkable; USG 1.044; except for RBC blood work - not performed

LIMITED ULTRASONOGRAPHIC EXAMINATION

The **urinary bladder**, trigone, and pelvic urethra presented normal thicknesses and normal tone. The ureters were not visible which is normal. No uroliths or sediment were visualized and anechoic urine was present. No evidence of inflammatory or neoplastic changes were noted. Ureteral papillae were normal. The pelvic urethra was imaged 1.0 cm beyond the cystourethral junction.

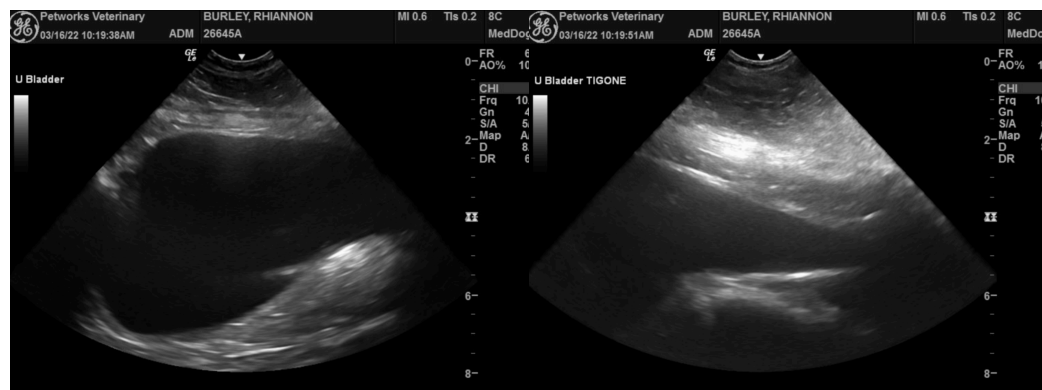
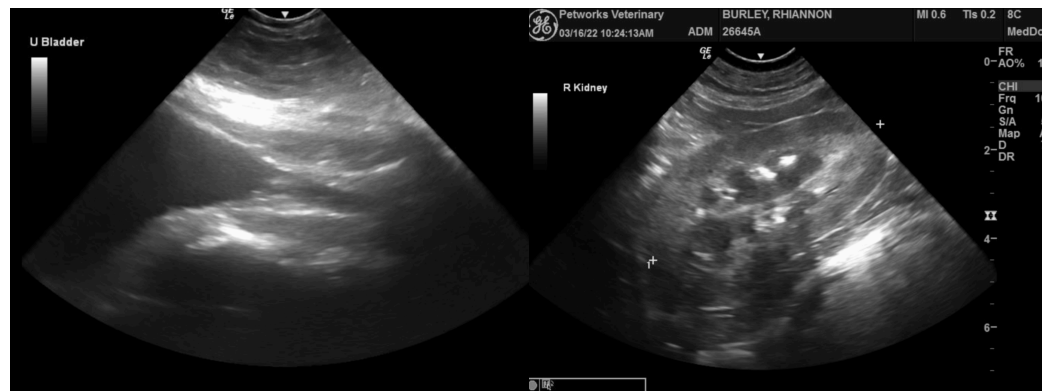
The **kidneys** presented normal size and contour. Corticomedullary calculi noted, non-obstructive, measuring up to 2.0 mm. The patient may be passing calculi periodically, causing the hematuria. However, no obstructive disease noted at the time of the sonogram. The left kidney measured 6.6 cm. The right kidney measured 5.98 cm.

ULTRASONOGRAPHIC FINDINGS

- Minor renal calculi, non-obstructive

INTERPRETATION OF THE FINDINGS & FURTHER RECOMMENDATIONS

Suspect passage of calculi in the patient's history causing the clinical signs.





PATIENT

Rhiannon Burley

SPECIES

Canine

BREED

Collie

SEX

Spayed Female

AGE

9 Years

WEIGHT

33.4 kg

INTERPRETED BY

Eric Lindquist, DMV

DABVP, Cert. IVUSS

IMAGING PERFORMED BY

Dr. Trudeau

HOSPITAL NAME

Petworks VH

REFERRING VET

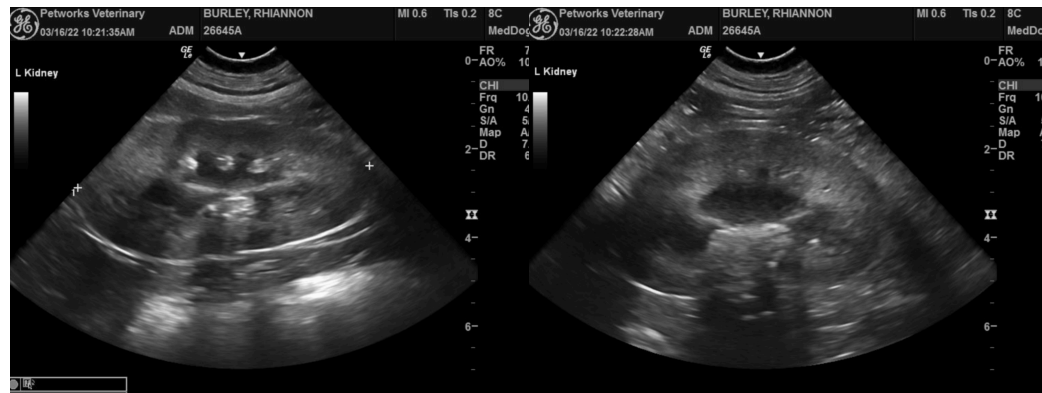
Dr. Trudeau

INVOICE

36220

DATE

3/16/22



The information and recommendations provided are based on the images presented by the referring veterinarian/sonographer. No evaluation can be communicated regarding pathology that was not visible in the image/video clips provided.

Thank you for this referral. If the clinical or image interpretation does not parallel your findings or if I can be of any further assistance please contact me.

Eric Lindquist, DMV, DABVP, Cert. IVUSS, CEO of SonoPath.com

info@SonoPath.com