

PATIENT

Gaia Giuliani

PRESENTING CLINICAL SIGNS

Recheck u/s for history of weight loss and distended stomach. Pt vomited large amount of hair a couple of days ago. Appetite is still good, pt lost 0.1 lb. Pt has been fasted since 8 pm last night

SPECIES

Feline

ULTRASONOGRAPHIC EXAMINATION OF THE ABDOMEN

Urinary System

BREED

DLH

The **urinary bladder**, trigone, and pelvic urethra presented normal thicknesses and normal tone. The ureters were not visible which is normal. No uroliths or sediment were visualized and anechoic urine was present. No evidence of inflammatory or neoplastic changes were noted. Ureteral papillae were normal.

SEX

Spayed Female

The **kidneys** presented minor age related changes, similar to the prior sonogram. The left kidney measured 3.5 cm. The right kidney measured 4.0 cm.

Adrenal Glands

AGE

12.5 Years

The regions of the adrenal glands were unremarkable.

Spleen

WEIGHT

7.9 Pounds

The **spleen** presented a smooth homogeneous parenchyma hyperechoic to liver and renal cortical parenchyma. The capsule was smooth without noticeable expansion or deviation from within the spleen or adjacent pathology. The splenic vasculature demonstrated normal volume without signs of congestion or thrombosis. No sonographic evidence of acute or chronic inflammatory, neoplastic, or infarctual changes were noted.

INTERPRETED BY

Eric Lindquist, DMV

Liver

The **liver** revealed slight increased portal markings. The gallbladder wall was slightly echogenic.

DABVP, Cert. IVUSS

Gastrointestinal

IMAGING PERFORMED BY

Dr. Giuliani

The **stomach** was filled with progressively shadowing material, appears less dense than the prior sonogram. This could represent a post-prandial presentation. The small intestine and colon were unremarkable.

Pancreas

HOSPITAL NAME

The Pet Hospital of Stratford

The **pancreas** revealed minor heterogeneous changes, no evidence of active inflammation.

ULTRASONOGRAPHIC FINDINGS

- Improved gastric luminal material

REFERRING VET

Dr. Giuliani

INTERPRETATION OF THE FINDINGS & FURTHER RECOMMENDATIONS

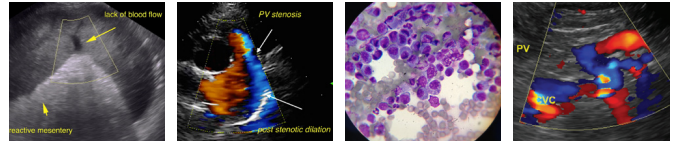
Recommend continued treatment for hairball accumulation. Unremarkable stable abdomen otherwise.

INVOICE

36250

DATE

3/17/22



PATIENT

Gaia Giuliani

SPECIES

Feline

BREED

DLH

SEX

Spayed Female

AGE

12.5 Years

WEIGHT

7.9 Pounds

INTERPRETED BY

Eric Lindquist, DMV

DABVP, Cert. IVUSS

IMAGING PERFORMED BY

Dr. Giuliani

HOSPITAL NAME

The Pet Hospital of
Stratford

REFERRING VET

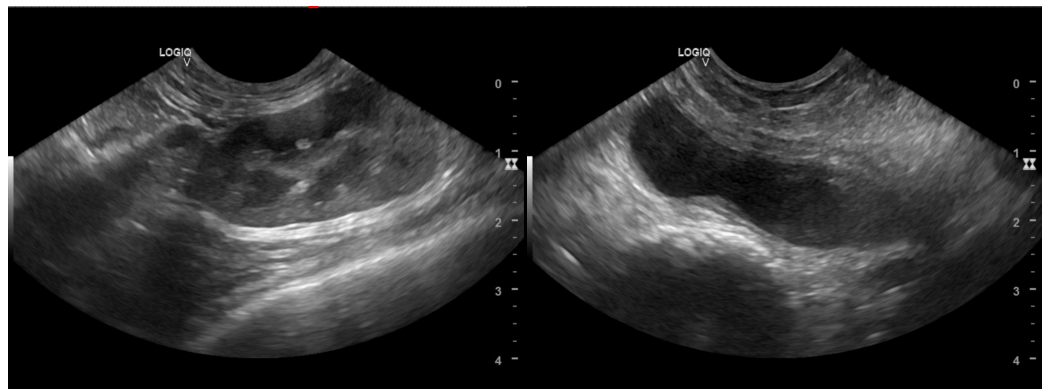
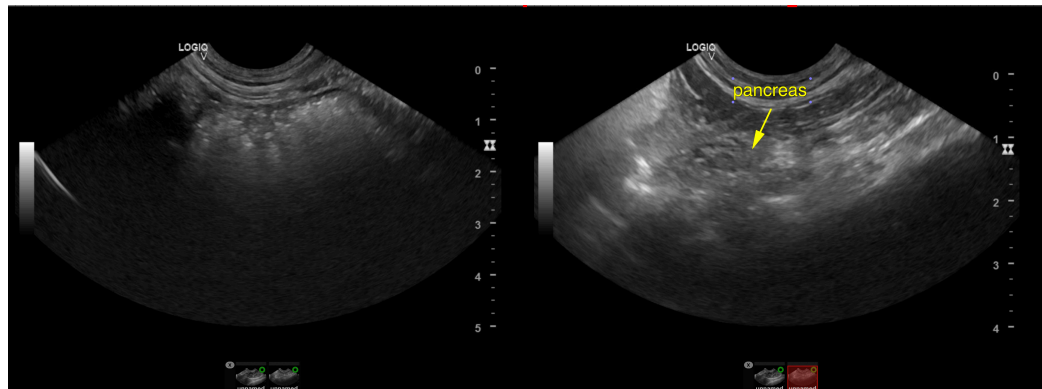
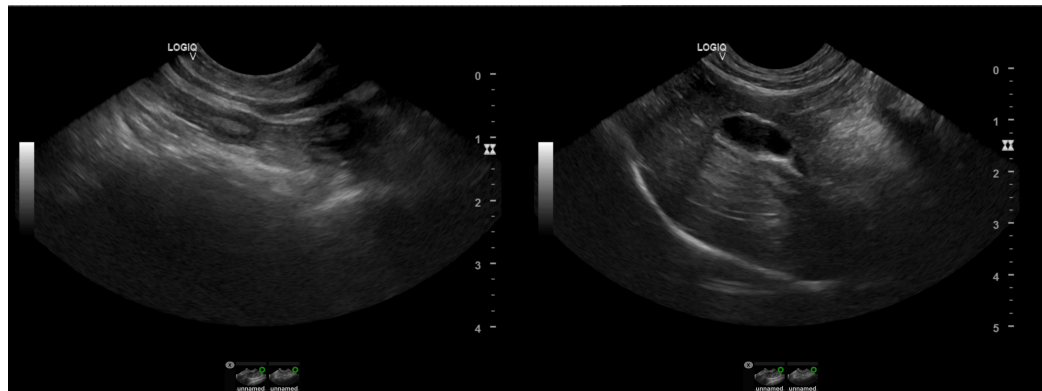
Dr. Giuliani

INVOICE

36250

DATE

3/17/22



The information and recommendations provided are based on the images presented by the referring veterinarian/sonographer. No evaluation can be communicated regarding pathology that was not visible in the image/video clips provided.

Thank you for this referral. If the clinical or image interpretation does not parallel your findings or if I can be of any further assistance please contact me.

Eric Lindquist, DMV, DABVP, Cert. IVUSS, CEO of SonoPath.com

info@SonoPath.com