



PATIENT

French Fry Blum

SPECIES

Rat

BREED

SEX

Neutered male

AGE

1 year

WEIGHT

560 g

INTERPRETED BY

Eric Lindquist, DMV
DABVP, Cert. IVUSS

IMAGING PERFORMED BY

Dr. Parker

HOSPITAL NAME

Lone Mountain AH

REFERRING VET

Dr. Parker

INVOICE

96933

DATE

3/16/22

PRESENTING CLINICAL SIGNS

History: increase respiratory effort for 1 month. chest x-rays last week: 1. Poorly defined large round soft tissue opacity within the caudal dorsal lung. Differentials include primary pulmonary neoplasia (carcinoma), granulomatous disease, abscess, or superimposition artifact. Ultrasound-guided fine-needle aspiration may be possible. 2. Well-defined small round soft tissue opacity within the sixth rib space. Differentials include metastatic disease, granuloma, or superimposition artifact. 3. Mild diffuse bronchial pattern. Differentials include infectious or allergic bronchitis. Lower airway sampling may ultimately be indicated. 4. Unremarkable abdomen

ULTRASONOGRAPHIC EXAMINATION OF THE HEART

A small image set was submitted and demonstrated normal cardiac volume and contractility with an LA:AO ratio of 1.2. Internal diameters were normal. A large amount of surrounding thoracic fat was noted in this patient. Normal air artifact was noted in the lungs. There was no evidence of pleural effusion or masses.

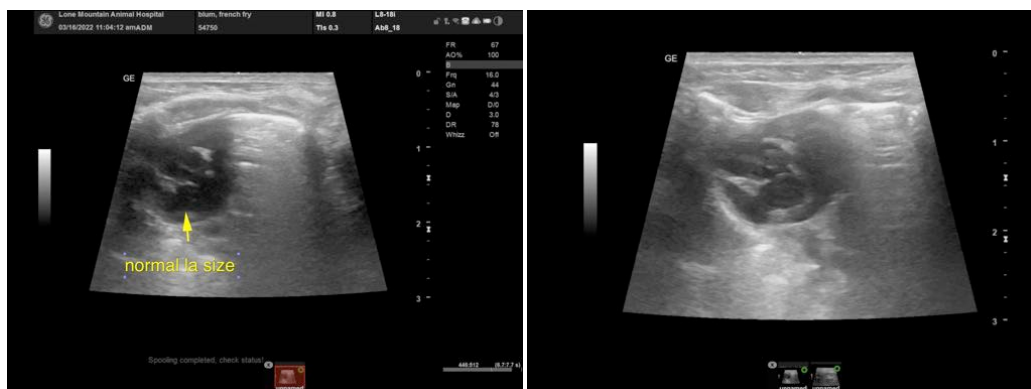
ULTRASONOGRAPHIC FINDINGS

Normal echocardiogram.

Large amount of thoracic fat.

INTERPRETATION OF THE FINDINGS & FURTHER RECOMMENDATIONS

There was no evidence of pathology.





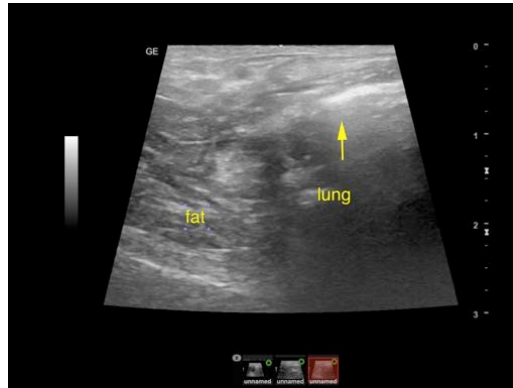
PATIENT

French Fry Blum

SPECIES

Rat

BREED



SEX

Neutered male

AGE

1 year

WEIGHT

560 g

The information and recommendations provided are based on the images presented by the referring veterinarian/sonographer. No evaluation can be communicated regarding pathology that was not visible in the image/video clips provided.

Thank you for this referral. If the clinical or image interpretation does not parallel your findings or if I can be of any further assistance please contact me.

Eric Lindquist, DMV, DABVP, Cert. IVUSS, CEO of SonoPath.com
info@SonoPath.com

INTERPRETED BY

Eric Lindquist, DMV
DABVP, Cert. IVUSS

IMAGING PERFORMED BY

Dr. Parker

HOSPITAL NAME

Lone Mountain AH

REFERRING VET

Dr. Parker

INVOICE

96933

DATE

3/16/22