



PATIENT

Baby Germeyer

SPECIES

Mustelid

BREED

Ferret

SEX

Neutered male

AGE

5 years

WEIGHT

3.82 lbs

INTERPRETED BY

Eric Lindquist, DMV
DABVP, Cert. IVUSS

IMAGING PERFORMED BY

Jack Reese

HOSPITAL NAME

Willow Run VC

REFERRING VET

Dr. Davies

INVOICE

96941

DATE

3/16/22

PRESENTING CLINICAL SIGNS

History: Several month history of weight gain and hairloss. Owner noted that Baby having difficulty with bowel movements - crying out when defecating. Fleas noted on exam.
Abnormal PE/Chem/CBC/UA Results: Palpable abdominal mass No recent labwork

ULTRASONOGRAPHIC EXAMINATION OF THE ABDOMEN

Urinary System

The **urinary bladder**, trigone, and pelvic urethra presented normal thicknesses and normal tone. The ureters were not visible which is normal. No uroliths or sediment were visualized and anechoic urine was present. No evidence of inflammatory or neoplastic changes was noted. Ureteral papillae were normal.

The **kidneys** revealed normal size and structure, corticomedullary definition and ratio for this age. The cortices presented largely uniform texture with normal echogenic relationship to liver and spleen. Medullary structure differed distinctly from the cortex and no evidence of pelvic dilation was present. The capsules were acceptably uniform without significant irregularities. The left kidney measured 3.55 cm. The right kidney measured 3.8 cm.

Adrenal Glands

The left **adrenal gland** revealed a 4.8 cm, mixed hypoechoic expansive mass. Regional inflammation was noted around the mass. The mass imaged from the right approach revealed significant invasion into the vena cava. The vena cava was dilated and measured 1.5 cm in width. Regional free fluid was present. The right adrenal gland was visualized and measured 0.5 cm.

Spleen

The presumed adrenal mass impinges upon the **spleen** and appears to connect or adhere to it. The spleen appeared thickened.

Liver

The **liver** was swollen with irregular contour. Hepatic vein dilation was noted. The gallbladder presented acceptably thin walls with primarily anechoic content. The cystic and common bile ducts were normal.

Gastrointestinal

The **gastrointestinal tract** revealed variable thickening with reactive mesentery.



PATIENT

Pancreas

Baby Germeyer

The base and limbs of the **pancreas** were observed to be largely isoechoic to surrounding omental fat. Pancreatic duct and capsular contour were acceptably normal and parenchyma respected normal curvilinear patterns. No overt evidence of active inflammatory or neoplastic disease was noted.

SPECIES

Mustelid

ULTRASONOGRAPHIC FINDINGS

BREED

Ferret

Large, invasive, left adrenal mass.

Multi-centric lymphadenopathy and nodular hepatic changes. Passive congestion liver pattern.

Swollen, irregular spleen.

SEX

Neutered male

INTERPRETATION OF THE FINDINGS & FURTHER RECOMMENDATIONS

This does not appear to be a surgical case. Palliative care or humane euthanasia should be considered.

AGE

5 years

WEIGHT

3.82 lbs

INTERPRETED BY

Eric Lindquist, DMV
DABVP, Cert. IVUSS

IMAGING PERFORMED BY

Jack Reese

HOSPITAL NAME

Willow Run VC

REFERRING VET

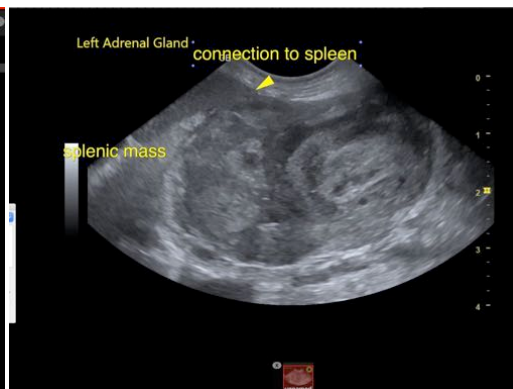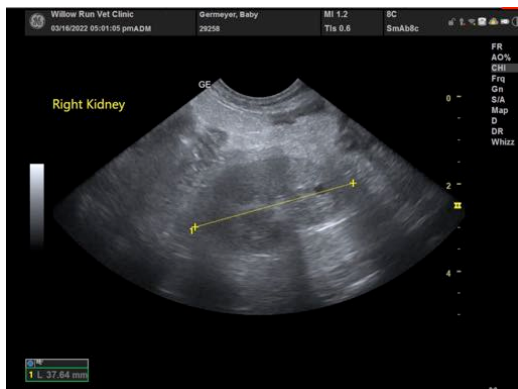
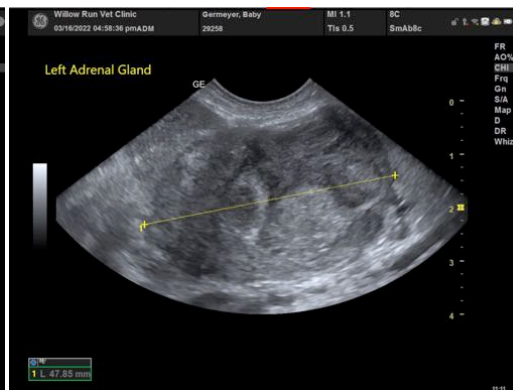
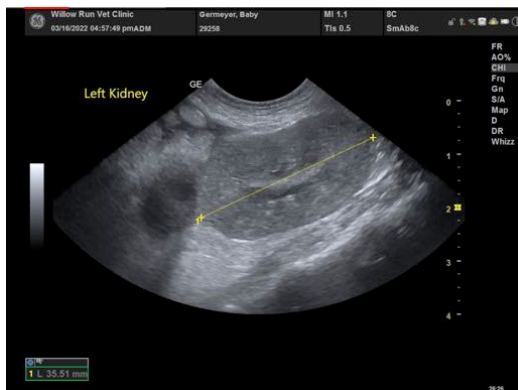
Dr. Davies

INVOICE

96941

DATE

3/16/22





PATIENT

Baby Germeyer

SPECIES

Mustelid

BREED

Ferret

SEX

Neutered male

AGE

5 years

WEIGHT

3.82 lbs

INTERPRETED BY

Eric Lindquist, DMV
DABVP, Cert. IVUSS

IMAGING PERFORMED BY

Jack Reese

HOSPITAL NAME

Willow Run VC

REFERRING VET

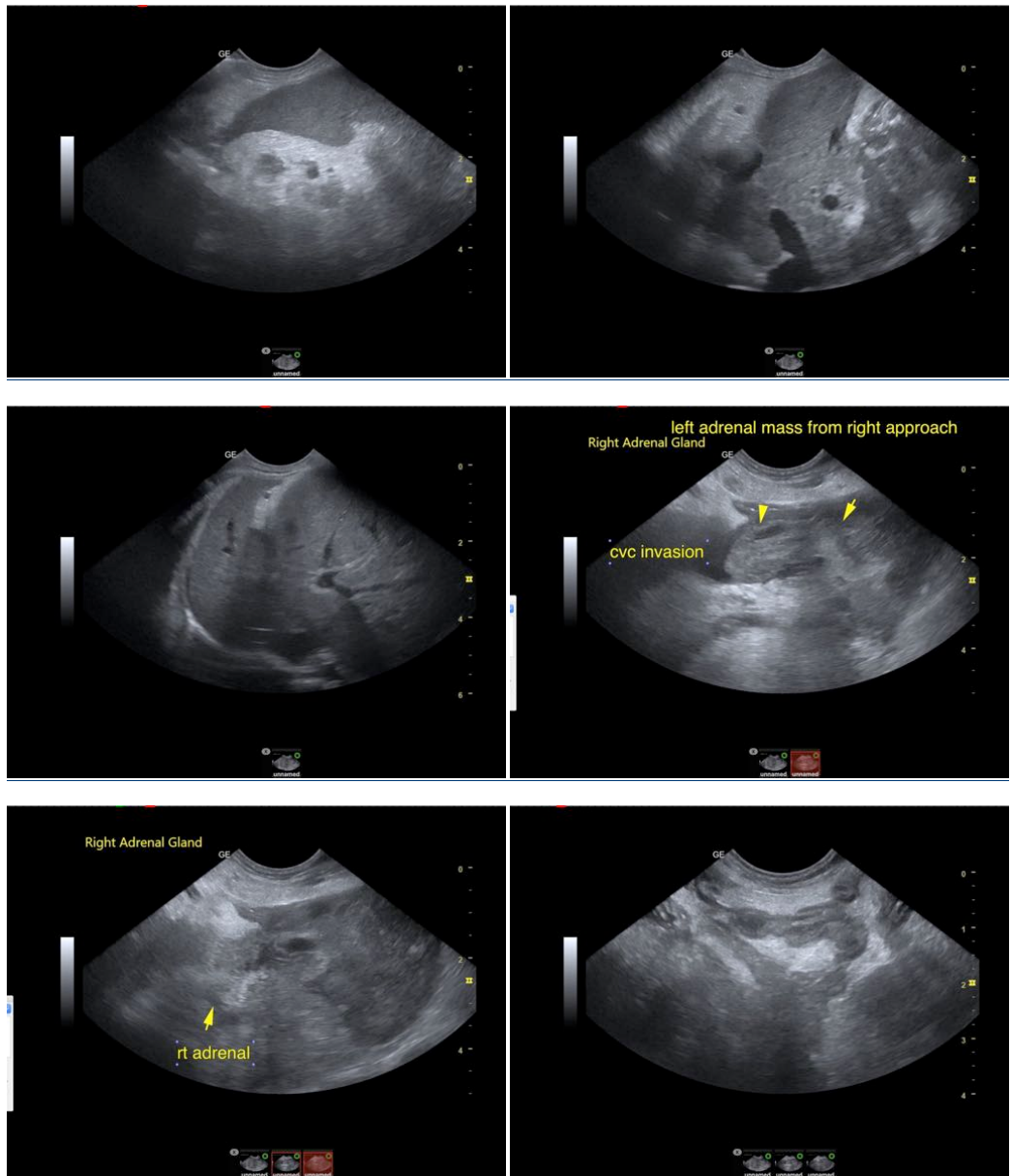
Dr. Davies

INVOICE

96941

DATE

3/16/22



The information and recommendations provided are based on the images presented by the referring veterinarian/sonographer. No evaluation can be communicated regarding pathology that was not visible in the image/video clips provided.

Thank you for this referral. If the clinical or image interpretation does not parallel your findings or if I can be of any further assistance please contact me.

Eric Lindquist, DMV, DABVP, Cert. IVUSS, CEO of SonoPath.com



PATIENT

info@SonoPath.com

Baby Germeyer

SPECIES

Mustelid

BREED

Ferret

SEX

Neutered male

AGE

5 years

WEIGHT

3.82 lbs

INTERPRETED BY

Eric Lindquist, DMV
DABVP, Cert. IVUSS

**IMAGING
PERFORMED BY**

Jack Reese

HOSPITAL NAME

Willow Run VC

REFERRING VET

Dr. Davies

INVOICE

96941

DATE

3/16/22