


PATIENT

Gizmo Stringham

SPECIES

Feline

BREED

DSH

SEX

Neutered Male

AGE

9

WEIGHT

9.8

INTERPRETED BY

Eric Lindquist, DMV

DABVP, Cert. IVUSS

PRESENTING CLINICAL SIGNS

Recheck prev u/s 9/19 showed unclassified to hypertrophic cardiomyopathy with L atrial enlargement, emerging L sided heart failure with compensatory tachycardia, owner reports doing ok at home but does notice cat has increased Resp effort from time to time even at rest. Current meds Clopdogrel 75 mg 1/4 SID Lasix 12.5mg 1/2 BID Enalapril 2.5 mg SID Owner reports sometimes she has trouble giving him his meds

ULTRASONOGRAPHIC EXAMINATION OF THE HEART

FELINE CARDIAC PARAMETERS	BODY WEIGHT (kg)	HR (BPM)	IVSd (cm)	LVIDd (cm)	LVWd (cm)	FS (%)	EF (%)
NORMAL PARAMETER	-----	150-240	0.3-0.6	1.0-2.1	0.25-0.6	35-67	80-100
PATIENT		180	0.6	1.8	0.6	35	70
FELINE CARDIAC PARAMETERS	LA/AO (Boon)	LA/AO HEART BASE (Sisson)	LA 2D 4-chamber long axis AS to FW (Sisson) (cm)	LVOT VEL. (m/s)	RVOT VEL. (m/s)	IVRT (m/)	
NORMAL PARAMETER	<1.5	0.88-1.79	0.7-1.7	<1.6	<1.3	40-60	
PATIENT	2.8	2.5	2.65	0.9	1.31	NM	
Adapted from June Boon, Veterinary Echocardiography, 1998 Sisson D et al. JVIM 1991; 5: 232, Jacobs et al. Am J Vet Res 1985; 46:1705							

Cardiac Presentation

The cardiac presentation presented persistent volume overload of the left atrium with hypocontractility. Mitral and tricuspid insufficiency noted. Mild right atrial enlargement. No pericardial or pleural effusion noted. No spontaneous contrast noted or overt clots.

ULTRASONOGRAPHIC FINDINGS

- Volume overload left atrium
- Mitral and tricuspid insufficiency
- Mild right atrial enlargement

INTERPRETATION OF THE FINDINGS & FURTHER RECOMMENDATIONS

This is most consistent with persistent unclassified cardiomyopathy. Recommend continuation of the current protocol, yet adding Pimobendan at 0.3 mg/kg BID. Recheck echo in 3 months, earlier if murmur grade increases or respiratory signs increase. Target respiratory rate of <25/min.

IMAGING PERFORMED BY

Jenn

HOSPITAL NAME

Rockaway AH

REFERRING VET

Dr. Maniar

INVOICE

45909

DATE

3/15/23



PATIENT

Gizmo Stringham

SPECIES

Feline

BREED

DSH

SEX

Neutered Male

AGE

9

WEIGHT

9.8

INTERPRETED BY

Eric Lindquist, DMV

DABVP, Cert. IVUSS

IMAGING PERFORMED BY

Jenn

HOSPITAL NAME

Rockaway AH

REFERRING VET

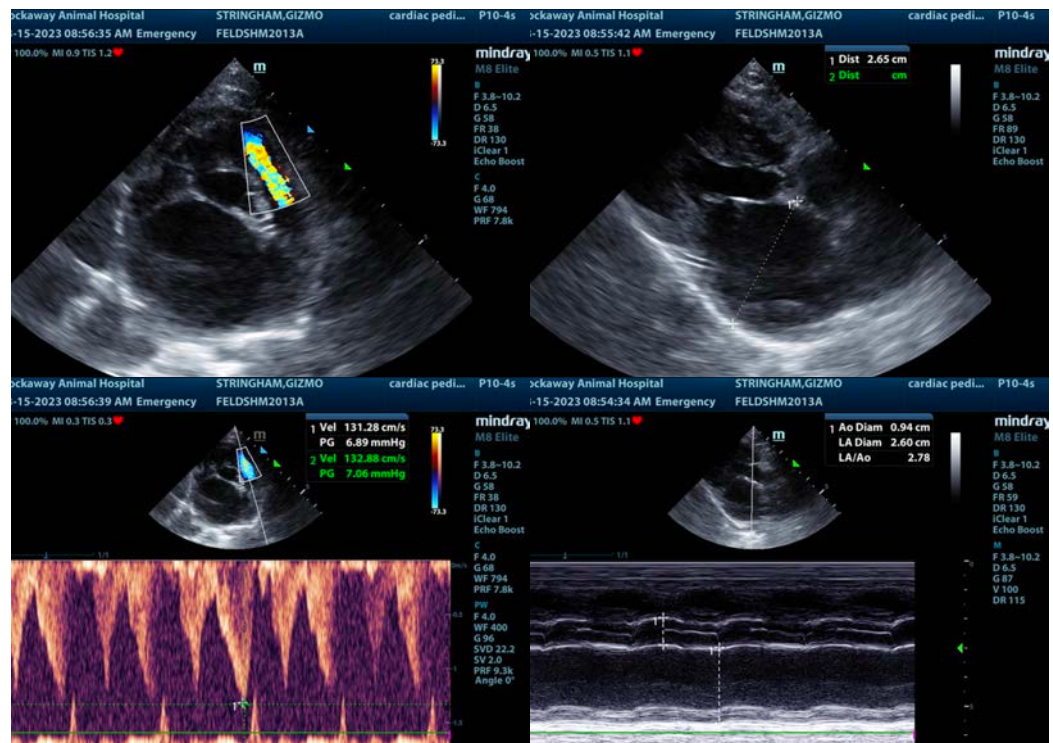
Dr. Maniar

INVOICE

45909

DATE

3/15/23



The information and recommendations provided are based on the images presented by the referring veterinarian/sonographer. No evaluation can be communicated regarding pathology that was not visible in the image/video clips provided.

Thank you for this referral. If the clinical or image interpretation does not parallel your findings or if I can be of any further assistance please contact me.

Eric Lindquist, DMV, DABVP, Cert. IVUSS, CEO of SonoPath.com

info@SonoPath.com