

**DATE**

3/15/22

PRESENTING CLINICAL SIGNS

Squeek came in for a second opinion on URI issues but on PE both kidneys were felt to be enlarged. X-rays taken confirm the bilateral renomegaly. Would like to see if the kidneys look like they have infiltrative disease, FIP, polycystic kidney disease or something else going on. Also, due to her severe congestion, she has not been on any cat food for awhile - she gets ham baby food and the cat lickable treats. Current Medications: Has been on Prednisolone once daily.

PATIENT

Squeek Slemaker

Lab Results: CREA 2.0 mg/dL (0.8 2.4), BUN 18 mg/dL (16 36) from pet ER in Feb.

Date of Previous IntraPet Ultrasound: No previous.

Sedation: Not required to complete full diagnostic ultrasound.

Stat Report: Not requested.

Imaging Performed By: Rachel Brillhart, RDMS.

SPECIES

Feline

BREED

Domestic Shorthair

ULTRASONOGRAPHIC EXAMINATION OF THE ABDOMEN**Urinary System**

The **urinary bladder**, trigone, and pelvic urethra presented normal thicknesses and normal tone. The ureters were not visible which is normal. No uroliths or sediment were visualized and anechoic urine was present. No evidence of inflammatory or neoplastic changes was noted. Ureteral papillae were normal.

SEX

Spayed Female

The **kidneys** revealed severe renomegaly with thickened irregular nodular changes. There was loss of corticomedullary definition. Subcapsular halo was noted. The left kidney measured 5.4 cm. The right kidney measured 5.28 cm. Peripheral inflammation was noted along with severe disruption of architecture in both kidneys.

AGE

4/1/15

WEIGHT

7.75 lbs

Adrenal Glands

Both **adrenal glands** were visualized and recognized as having normal shape, size, position and echogenicity for this breed. The phrenic vasculature, glandular echogenicity and detail were unremarkable. Capsule, cortex, and medullary definition were normal for this age patient.

INTERPRETED BY

Eric Lindquist, DMV
DABVP, Cert. IVUSS

Spleen

The **spleen** presented a smooth homogeneous parenchyma hyperechoic to liver and renal cortical parenchyma. The capsule was smooth without noticeable expansion or deviation from within the spleen or adjacent pathology. The splenic vasculature demonstrated normal volume without signs of congestion or thrombosis. No sonographic evidence of acute or chronic inflammatory, neoplastic, or infarctual changes was noted.

HOSPITAL NAME

Cat Sense Feline
Hospital

REFERRING VET

Dr. Sinclair

Liver

The **liver** images submitted revealed subjectively normal liver size, contour, and structure. Parenchymal echogenicity was naturally coarse and hypoechoic to the spleen. Vascular and biliary tracts were of normal volume with no evidence of congestion. The gallbladder presented acceptably thin walls with primarily anechoic content. The cystic and common bile ducts were normal. No pathological hepatic lymphadenopathy was evident. No overt structural evidence of inflammatory, infiltrative or regenerative pathology was evident.

INVOICE

96903

Gastrointestinal

Examination of the **gastrointestinal tract** revealed a stomach and intestine free of stasis, of normal wall thickness, acceptable curvilinear mural detail, and peristaltic activity. Small and large intestine demonstrated normal luminal chyme and stool consistency respectively. No obstructive or overt infiltrative disease was noted. No associated abnormal lymphatic activity was noted.

Pancreas

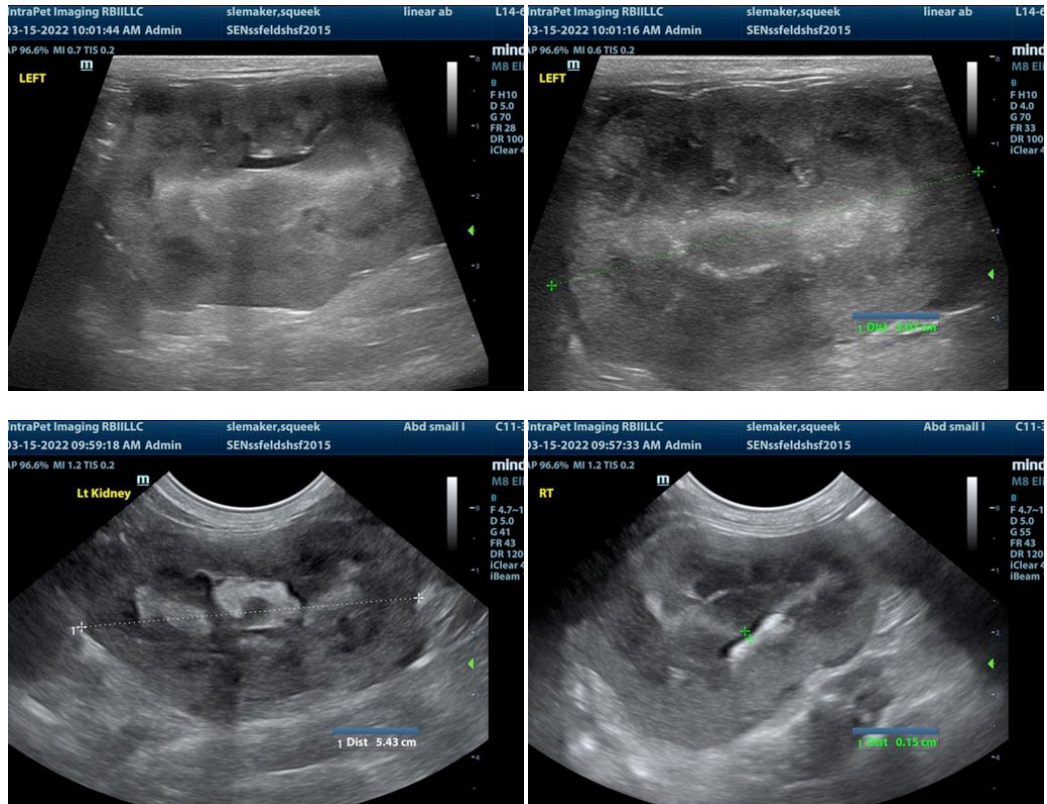
The base and limbs of the **pancreas** were observed to be largely isoechoic to surrounding omental fat. Pancreatic duct and capsular contour were acceptably normal and parenchyma respected normal curvilinear patterns. No overt evidence of active inflammatory or neoplastic disease was noted.

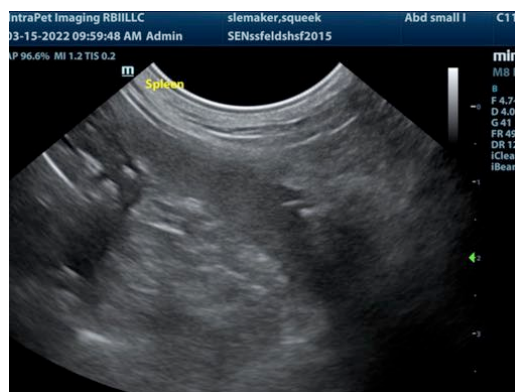
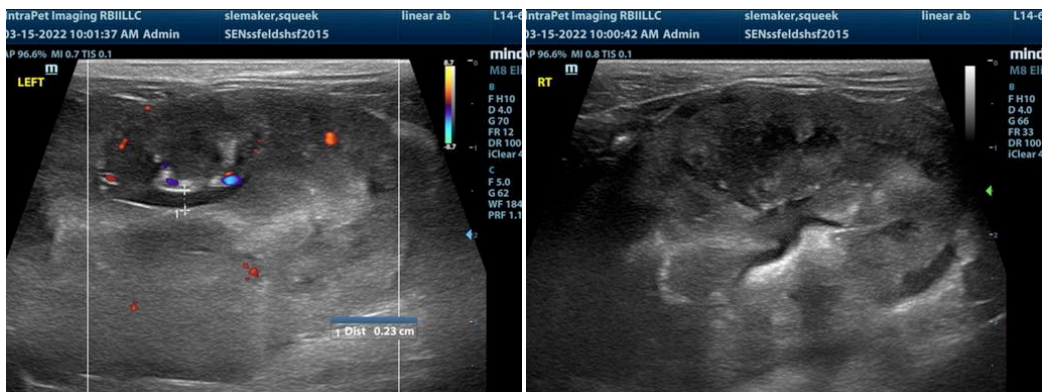
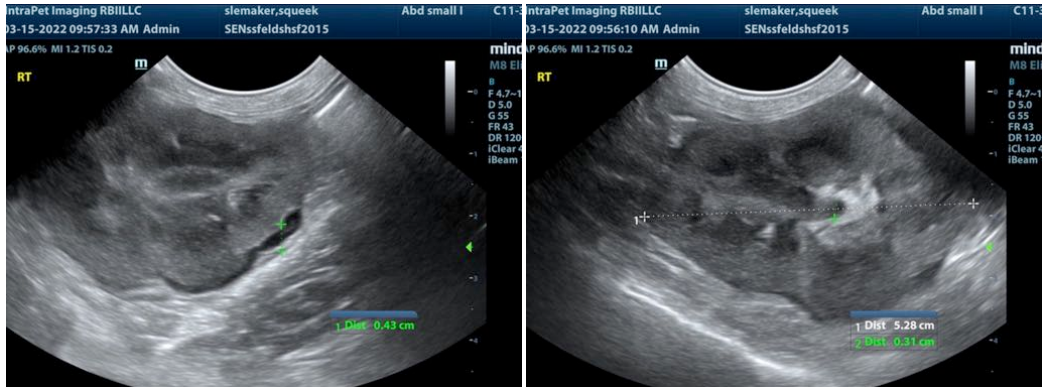
ULTRASONOGRAPHIC FINDINGS

Bilateral renal lymphoma pattern with nodules and infiltrative pattern. Subcapsular halo.

INTERPRETATION OF THE FINDINGS & FURTHER RECOMMENDATIONS

FNA of either kidney is recommended for confirmation. The spleen appeared normal and there was no evidence of organ metastasis. Immediate chemotherapeutic intervention is necessary.





The information and recommendations provided are based on the images presented by the referring veterinarian. No evaluation can be communicated regarding pathology that was not visible in the image/video clips provided.

Thank you for this referral. If the clinical or image interpretation does not parallel your findings or if I can be of any further assistance please contact me.

Eric Lindquist, DMV, DABVP, Cert. IVUSS, CEO of SonoPath.com
 Eric.Lindquist@SonoPath.com