



PATIENT PRESENTING CLINICAL SIGNS

PATIENT
Lilly Beggs
SPECIES
Canine
BREED
Shih Tzu Mix
SEX
Spayed Female
AGE
13 years
WEIGHT
20 lbs

PRESENTING CLINICAL SIGNS
History: Chronic coughing at home- especially at night, on auscultation lungs sound clear, owner hears "crackles" when laying next to patient. Tongue sometimes deep purple, never blue. No collapse. Current meds: Pred 5mg 1/2 tab SID, Hydrocodone 5mg 1/2 BID, Theophylline 5mg BID, was on Doxy finished 3/11/22
Abnormal PE/Chem/CBC/UA Results: ALKP 144

ULTRASONOGRAPHIC EXAMINATION OF THE HEART

The echocardiogram in this patient demonstrated normal **left atrial** size based on 3 different LA measurement methods. Chamber volumes and echogenicity were normal. The cranial and caudal **mitral** valve leaflets presented vegetative thickening consistent with endocardiosis. Doppler indicated measurable insufficiency. The **left ventricle** presented thicknesses with linear contour and was not dilated nor restricted. The **myocardium** presented normal echogenicity without subjective evidence of significant fibrotic or ischemic disease. **Contractility** of the ventricular walls was adequate and in normal range for this patient evidenced by the fractional shortening measurement and subjective evaluation of the different regions of the myocardium. The **left ventricular outflow** tract demonstrated normal laminar flow and subjective structural integrity. The **right atrium** and auricle revealed normal size, structure and content. No evidence of masses was noted or chamber overload. **Tricuspid** valvular assessment demonstrated adequate linear morphology. The **right ventricle** was of normal size (1/3 diameter of LV), chordae structure, myocardial echogenicity and thickness. **Pulmonic** tract assessment revealed normal valve structure, laminar flow, and diameter (approx. 1:1 pa/ao ratio). No visible **pericardial** or free pleura fluid was noted. No echographically detectable evidence of infiltrative disease was visible. The cranial **mediastinum and pericardial regions** were free of masses in the visible window.

INTERPRETED BY

Eric Lindquist, DMV
DABVP, Cert. IVUSS

IMAGING PERFORMED BY

Jessica Miller, RDMS

HOSPITAL NAME

Whippany VH

REFERRING VET

Dr. Cordero

CANINE	MR	TR	LA/AO	LA/AO	FS	EF	EPSS
CARDIAC PARAMETERS	VMAX (m/s)	VMAX (m/s)	(Boon method)	(Heart Base; Swe)	(%)	(%)	(cm)
NORMAL PARAMETER	4.5-5.5	<2.7	1.3	<1.6	28-40	40-100	<0.6
PATIENT	6.16	3.04	1.2	1.09	63	92	NM
CANINE	HR	AV	PV	BODY WEIGHT	LA	LVIDd	LVIDs
CARDIAC PARAMETERS	(BPM)	VMAX (m/s)	MAX (m/s)		2D short axis Base view (cm)	Avg; 2D and m-mode short axis (cm)	Avg; 2D and m-mode short axis (cm)
NORMAL PARAMETER	50-100	0.7-1.7	0.7-1.6				
PATIENT	125	1.89	1.2	20 lbs	2.24 max		

INVOICE

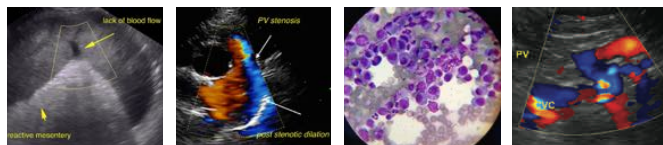
96882

DATE

3/15/22

ULTRASONOGRAPHIC FINDINGS

Stage B1 valvular disease.



PATIENT

Lilly Beggs

SPECIES

Canine

BREED

Shih Tzu Mix

SEX

Spayed Female

AGE

13 years

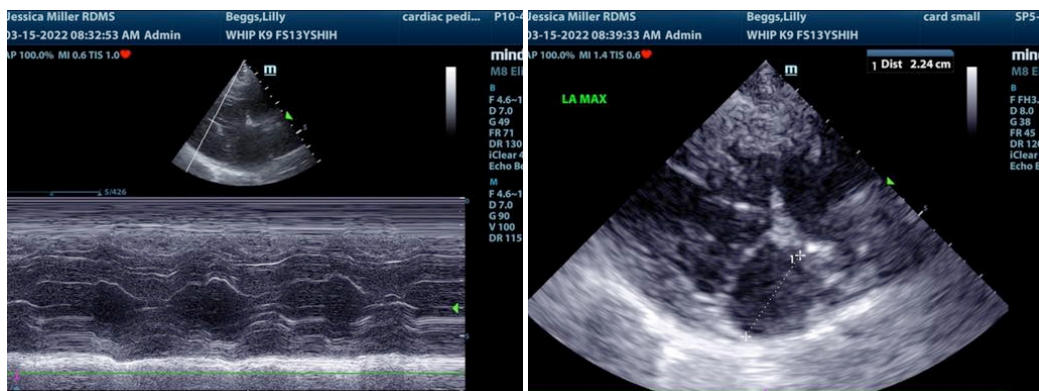
WEIGHT

20 lbs

INTERPRETATION OF THE FINDINGS & FURTHER RECOMMENDATIONS

Even though there is a murmur in this patient the cough is non-cardiogenic. No left sided volume overload is present. Primary respiratory protocol is recommended.

B1: The heart is stable without clinical disease. No overt contraindication for anesthesia of brief to moderate duration. I suggest Torbutrol premed, Propofol induction, Isoflurane maintenance or similar protocol if anesthesia is desired. Blood pressure recommended if not already performed and target white coat negative systolic pressure of < 160 mmHg. If higher than this ACE-inhibitor is suggested to reach this level. Recheck echocardiogram is recommended in 6 months, earlier if murmur grade increases or clinical signs initiate.



INTERPRETED BY

Eric Lindquist, DMV
DABVP, Cert. IVUSS

IMAGING PERFORMED BY

Jessica Miller, RDMS

HOSPITAL NAME

Whippany VH

REFERRING VET

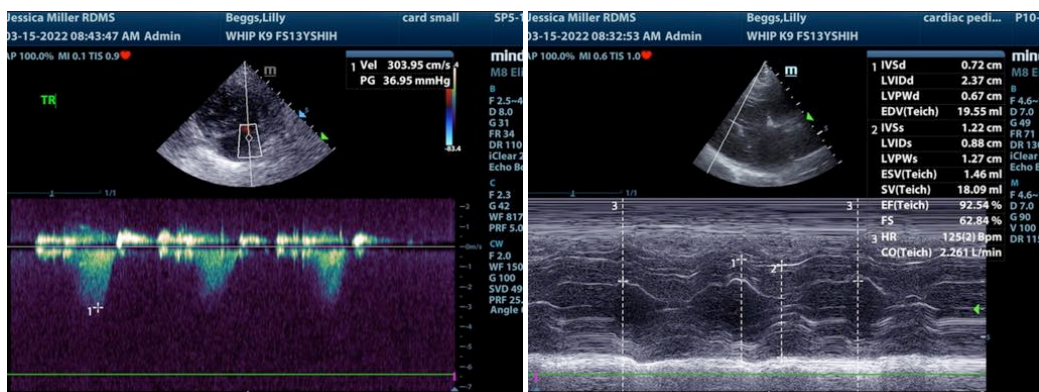
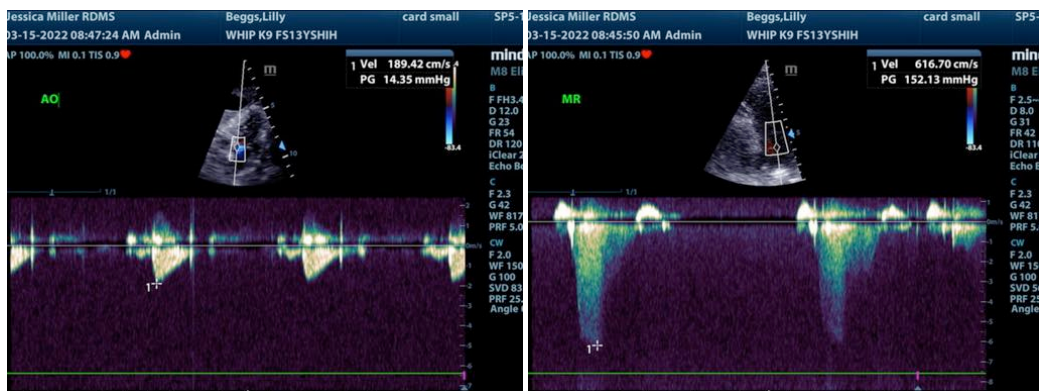
Dr. Cordero

INVOICE

96882

DATE

3/15/22





PATIENT

Lilly Beggs

SPECIES

Canine

BREED

Shih Tzu Mix

SEX

Spayed Female

AGE

13 years

WEIGHT

20 lbs

INTERPRETED BY

Eric Lindquist, DMV
DABVP, Cert. IVUSS

**IMAGING
PERFORMED BY**

Jessica Miller, RDMS

HOSPITAL NAME

Whippany VH

REFERRING VET

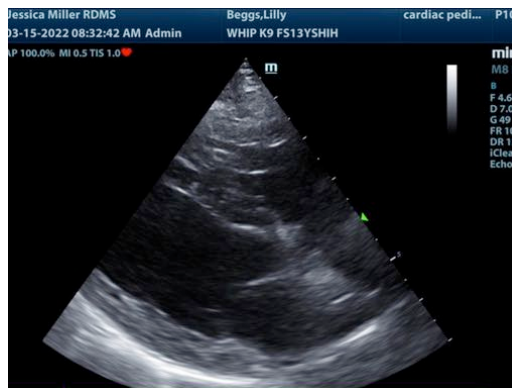
Dr. Cordero

INVOICE

96882

DATE

3/15/22



The information and recommendations provided are based on the images presented by the referring veterinarian/sonographer. No evaluation can be communicated regarding pathology that was not visible in the image/video clips provided.

Thank you for this referral. If the clinical or image interpretation does not parallel your findings or if I can be of any further assistance please contact me.

Eric Lindquist, DMV, DABVP, Cert. IVUSS, CEO of SonoPath.com
info@SonoPath.com