



<b>PATIENT</b>	<b>PRESENTING CLINICAL SIGNS</b>
Frankie Marabondo	History: IVDD cp deficits HL gastritis
<b>SPECIES</b>	<b>ULTRASONOGRAPHIC EXAMINATION OF THE ABDOMEN</b>
Canine	<b>Urinary System</b>
<b>BREED</b>	The <b>urinary bladder</b> , trigone, and pelvic urethra presented normal thicknesses and normal tone. The ureters were not visible which is normal. No uroliths or sediment were visualized and anechoic urine was present. No evidence of inflammatory or neoplastic changes was noted. Ureteral papillae were normal.
Dachshund	
<b>SEX</b>	The <b>kidneys</b> revealed largely normal size and structure, corticomedullary definition and ratio (cortex 1/3 of medulla) were essentially maintained with some age-related loss of curvilinear patterns regarding the capsule and C/M junction. The cortices presented largely uniform texture with some increased echogenicity expected for this age patient. Medullary structure differed distinctly from that of the cortex and no evidence of pelvic dilation was present. The right kidney measured 3.88 cm.
Spayed Female	
<b>AGE</b>	
9 years	
<b>WEIGHT</b>	<b>Adrenal Glands</b>
10 lbs	Both <b>adrenal glands</b> were visualized and recognized as having normal shape, size, position and echogenicity for this breed. The phrenic vasculature, glandular echogenicity and detail were unremarkable. Capsule, cortex, and medullary definition were normal for this age patient. The left adrenal gland measured 1.56 x 0.53 cm at the caudal pole and 0.48 cm at the cranial pole. The right adrenal gland measured 1.47 x 0.51 cm at the caudal pole and 0.92 cm at the cranial pole.
<b>INTERPRETED BY</b>	
Eric Lindquist, DMV DABVP, Cert. IVUSS	
<b>IMAGING PERFORMED BY</b>	<b>Spleen</b>
Jenn	The <b>spleen</b> presented a smooth homogeneous parenchyma hyperechoic to liver and renal cortical parenchyma. The capsule was smooth without noticeable expansion or deviation from within the spleen or adjacent pathology. The splenic vasculature demonstrated normal volume without signs of congestion or thrombosis. No sonographic evidence of acute or chronic inflammatory, neoplastic, or infarctual changes was noted.
<b>HOSPITAL NAME</b>	
Rockaway AH	
<b>REFERRING VET</b>	<b>Liver</b>
Dr. Maniar	The <b>liver</b> images from right and left intercostal as well as subcostal views revealed subjectively normal liver size, contour, and structure. Some age-related parenchymal remodeling was noted but likely not clinically significant at this time. Vascular and biliary tracts were of normal volume and no evidence of congestion was noted. The gallbladder wall and cystic duct were thickened with polypoid changes. This is consistent with polypoid hyperplasia.
<b>INVOICE</b>	
96863	
<b>DATE</b>	<b>Gastrointestinal</b>
3/15/22	Examination of the <b>gastrointestinal tract</b> revealed a stomach and intestine free of stasis, of normal wall thickness, acceptable curvilinear mural detail, and peristaltic activity. Small and large intestine



<b>PATIENT</b>	demonstrated normal luminal chyme and stool consistency respectively. No obstructive or overt infiltrative disease was noted. No associated abnormal lymphatic activity was noted.
Frankie Marabondo	
<b>SPECIES</b>	<b>Pancreas</b>
Canine	The base and limbs of the <b>pancreas</b> were observed to be largely isoechoic to surrounding omental fat. Pancreatic duct and capsular contour were acceptably normal and parenchyma respected normal curvilinear patterns. No overt evidence of active inflammatory or neoplastic disease was noted.
<b>BREED</b>	
Dachshund	
<b>SEX</b>	Chronic cholangitis pattern.
Spayed Female	Hepatic remodeling.
	Otherwise, age related changes.
<b>AGE</b>	
9 years	
<b>WEIGHT</b>	
10 lbs	
<b>INTERPRETED BY</b>	<b>INTERPRETATION OF THE FINDINGS &amp; FURTHER RECOMMENDATIONS</b>
Eric Lindquist, DMV DABVP, Cert. IVUSS	There is no evidence of significant disease.

**INTERPRETED BY**  
Eric Lindquist, DMV  
DABVP, Cert. IVUSS

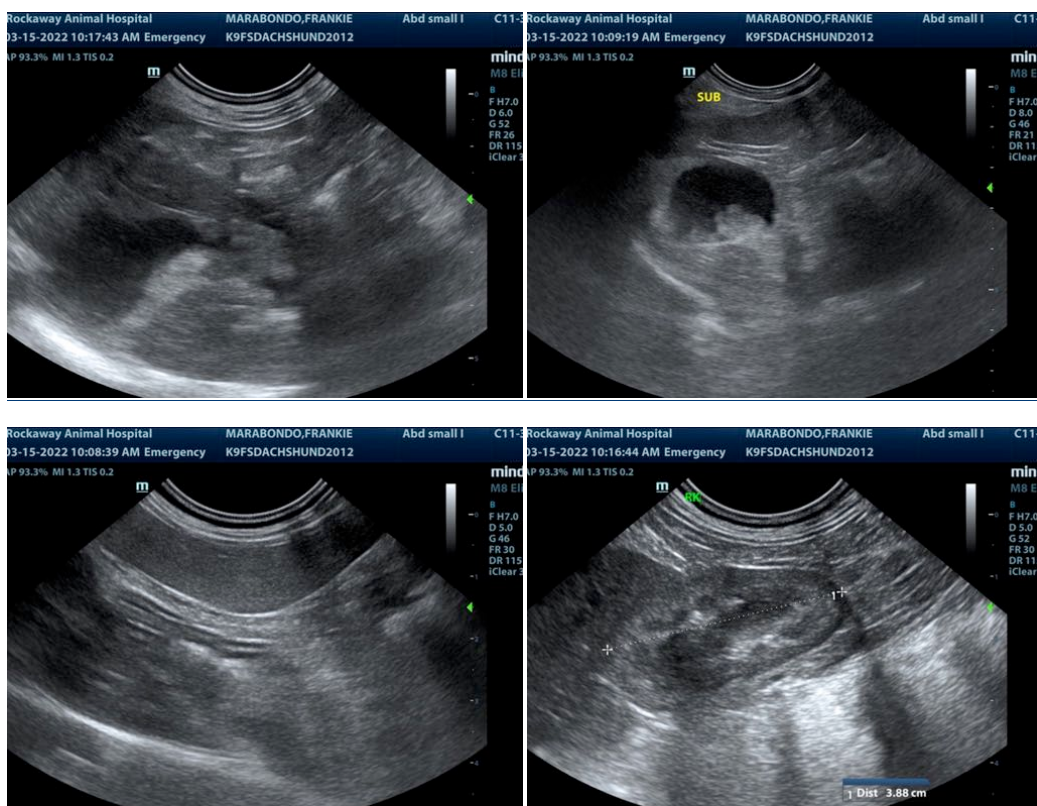
**IMAGING PERFORMED BY**  
Jenn

**HOSPITAL NAME**  
Rockaway AH

**REFERRING VET**  
Dr. Maniar

**INVOICE**  
96863

**DATE**  
3/15/22





**PATIENT**

Frankie Marabondo

**SPECIES**

Canine

**BREED**

Dachshund

**SEX**

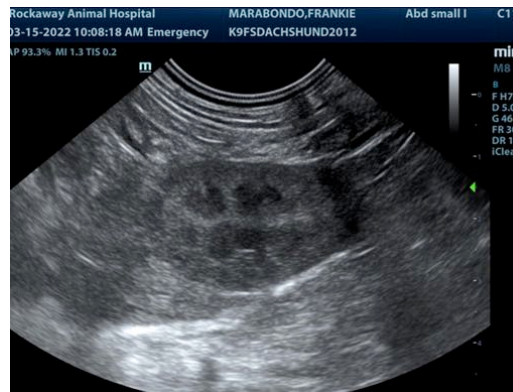
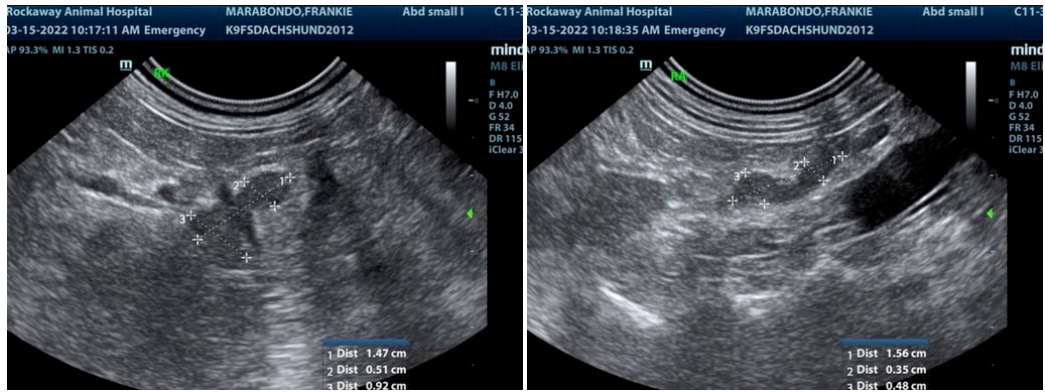
Spayed Female

**AGE**

9 years

**WEIGHT**

10 lbs



**INTERPRETED BY**

Eric Lindquist, DMV  
DABVP, Cert. IVUSS

**IMAGING PERFORMED BY**

Jenn

**HOSPITAL NAME**

Rockaway AH

**REFERRING VET**

Dr. Maniar

**INVOICE**

96863

**DATE**

3/15/22

The information and recommendations provided are based on the images presented by the referring veterinarian/sonographer. No evaluation can be communicated regarding pathology that was not visible in the image/video clips provided.

Thank you for this referral. If the clinical or image interpretation does not parallel your findings or if I can be of any further assistance please contact me.

Eric Lindquist, DMV, DABVP, Cert. IVUSS, CEO of SonoPath.com  
info@SonoPath.com