



PATIENT PRESENTING CLINICAL SIGNS

Penny Lane Harrison History: recheck previous u/s yesterday showed minor shadowing material in the pylorus

SPECIES ULTRASONOGRAPHIC EXAMINATION OF THE ABDOMEN

Canine

Gastrointestinal

BREED

The **gastrointestinal tract** was empty in this patient. The curvilinear patterns were maintained. There was no evidence of residual luminal material. The small intestine and colon were unremarkable.

Chihuahua Mix

SEX

ULTRASONOGRAPHIC FINDINGS

Spayed female

Normal gastrointestinal tract.

AGE

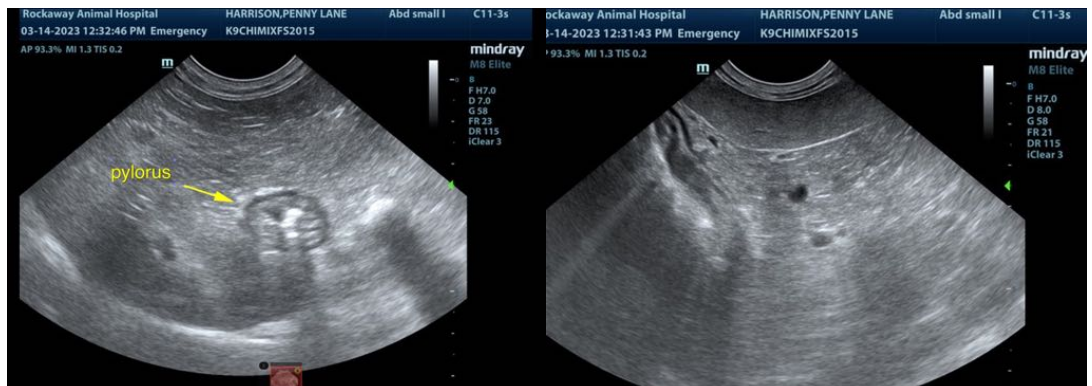
INTERPRETATION OF THE FINDINGS & FURTHER RECOMMENDATIONS

7 years

No evidence of residual luminal material. No further therapy is necessary at this time.

WEIGHT

27.5 lbs



INTERPRETED BY

Eric Lindquist, DMV
DABVP, Cert. IVUSS

IMAGING PERFORMED BY

Jenn

HOSPITAL NAME

Rockaway AH

The information and recommendations provided are based on the images presented by the referring veterinarian/sonographer. No evaluation can be communicated regarding pathology that was not visible in the image/video clips provided.

REFERRING VET

Dr. Maniar

Thank you for this referral. If the clinical or image interpretation does not parallel your findings or if I can be of any further assistance please contact me.

INVOICE

43284

Eric Lindquist, DMV, DABVP, Cert. IVUSS, CEO of SonoPath.com
info@SonoPath.com

DATE

3/14/23