



PATIENT PRESENTING CLINICAL SIGNS

Murphy Swenson

History: recheck on 3/11 showed full stomach with soft progressively shadowing material, likely foreign matter

SPECIES

Canine

ULTRASONOGRAPHIC EXAMINATION

Gastrointestinal

BREED

Golden Retriever

The upper **gastrointestinal tract** was empty in this patient. There was no further retention of ingesta noted in this patient. The curvilinear patterns were maintained. There was no residual pathology.

SEX

Neutered male

ULTRASONOGRAPHIC FINDINGS

Normalized GI tract.

AGE

3 years

INTERPRETATION OF THE FINDINGS & FURTHER RECOMMENDATIONS

There was no retention of ingesta noted today.

WEIGHT

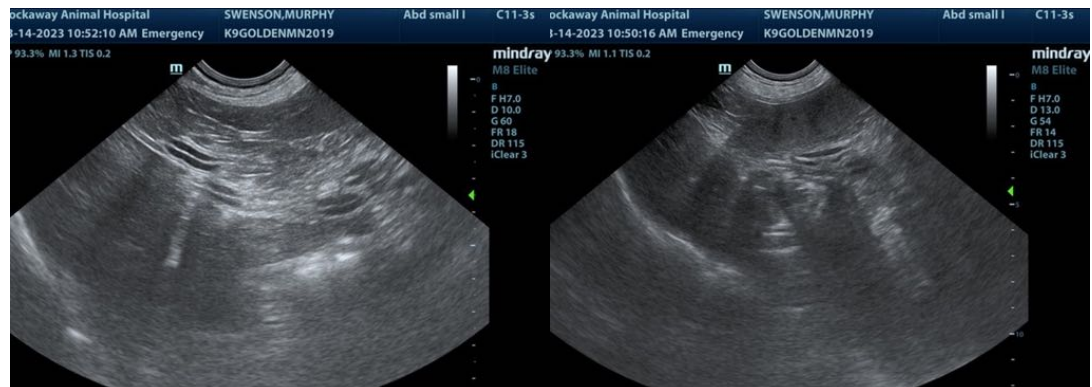
73 lbs

INTERPRETED BY

Eric Lindquist, DMV
DABVP, Cert. IVUSS

IMAGING PERFORMED BY

Jenn



HOSPITAL NAME

Rockaway AH

The information and recommendations provided are based on the images presented by the referring veterinarian/sonographer. No evaluation can be communicated regarding pathology that was not visible in the image/video clips provided.

REFERRING VET

Dr. Maniar

Thank you for this referral. If the clinical or image interpretation does not parallel your findings or if I can be of any further assistance please contact me.

Eric Lindquist, DMV, DABVP, Cert. IVUSS, CEO of SonoPath.com
info@SonoPath.com

INVOICE

43276

DATE

3/14/23