



**PATIENT**

Johnny Randolph

**SPECIES**

Feline

**BREED**

DSH

**SEX**

Intact Male

**AGE**

7 Months

**WEIGHT**

4 Years

**INTERPRETED BY**

Eric Lindquist, DMV  
DABVP, Cert. IVUSS

**IMAGING PERFORMED BY**

Melissa Pascucci

**HOSPITAL NAME**

American AH

**REFERRING VET**

Melissa Pascucci

**INVOICE**

13421

**DATE**

3/14/22

**PRESENTING CLINICAL SIGNS**

History: Chronic vomiting almost daily shortly after eating for the last 1-2 months. Patient is small for his age. Used to be a very quiet kitten. Otherwise doing well. Had been treated for mycoplasma.

Abnormal PE/Chem/CBC/UA Results: Unremarkable

**ULTRASONOGRAPHIC EXAMINATION OF THE ABDOMEN**

**Urinary System**

The **urinary bladder**, trigone, and pelvic urethra presented normal thicknesses and normal tone. The ureters were not visible which is normal. No uroliths or sediment were visualized, and anechoic urine was present. No evidence of inflammatory or neoplastic changes were noted. Ureteral papillae were normal.

The **kidneys** revealed normal size and structure, corticomedullary definition and ratio for this age. The cortices presented largely uniform texture with normal echogenic relationship to liver and spleen. Medullary structure differed distinctly from the cortex and no evidence of pelvic dilation was present. The capsules were acceptably uniform without significant irregularities. The left kidney measured 3.0 cm. The right kidney measured 3.0 cm.

**Adrenal Glands**

The regions of the **adrenal glands** imaged yet not visualized.

**Spleen**

The **spleen** presented a smooth homogeneous parenchyma hyperechoic to liver and renal cortical parenchyma. The capsule was smooth without noticeable expansion or deviation from within the spleen or adjacent pathology. The splenic vasculature demonstrated normal volume without signs of congestion or thrombosis. No sonographic evidence of acute or chronic inflammatory, neoplastic, or infarctual changes were noted.

**Liver**

The **liver** images submitted revealed subjectively normal liver size, contour, and structure. Parenchymal echogenicity was naturally coarse and hypoechoic to the spleen. Vascular and biliary tracts were of normal volume with no evidence of congestion. The gallbladder presented acceptably thin walls with primarily anechoic content. The cystic and common bile ducts were normal. No pathological hepatic lymphadenopathy was evident. No overt structural evidence of inflammatory, infiltrative or regenerative pathology was evident.

**Gastrointestinal**

Examination of the **gastrointestinal tract** revealed a stomach and intestine free of stasis, of normal wall thickness, acceptable curvilinear mural detail, and peristaltic activity. Small and large intestine demonstrated normal luminal chyme and stool consistency respectively. No obstructive or overt infiltrative disease was noted. No associated abnormal lymphatic activity was noted.

**Pancreas**

The base and limbs of the **pancreas** were observed to be largely isoechoic to surrounding omental fat. Pancreatic duct and capsular contour were acceptably normal and parenchyma respected normal curvilinear patterns. No overt evidence of active inflammatory or neoplastic disease was noted.



## PATIENT

Johnny Randolph

## SPECIES

Feline

## BREED

DSH

## SEX

Intact Male

## AGE

7 Months

## WEIGHT

4 Years

## INTERPRETED BY

Eric Lindquist, DMV  
DABVP, Cert. IVUSS

## IMAGING PERFORMED BY

Melissa Pascucci

## HOSPITAL NAME

American AH

## REFERRING VET

Melissa Pascucci

## INVOICE

13421

## DATE

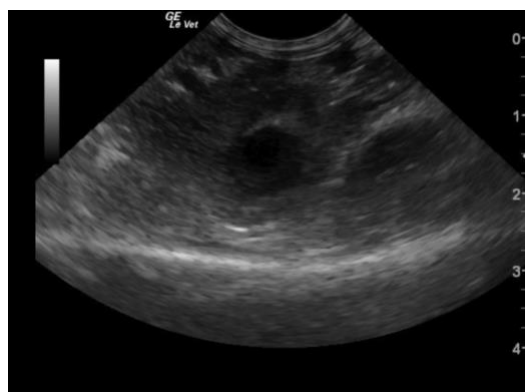
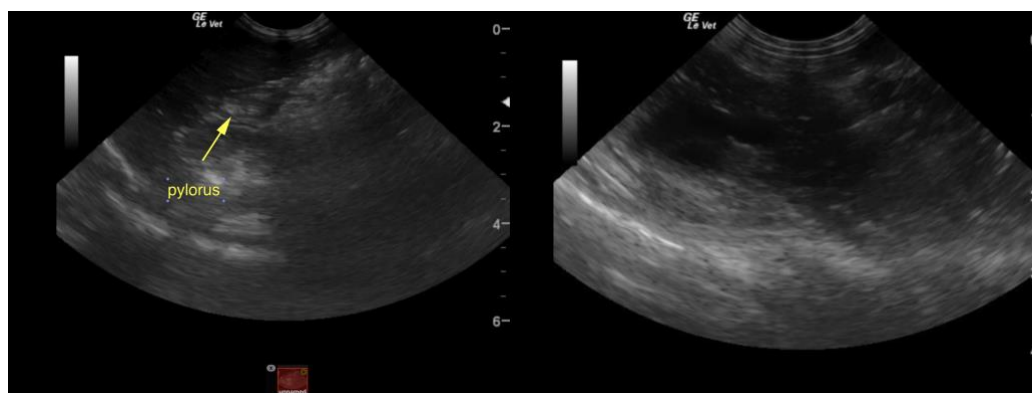
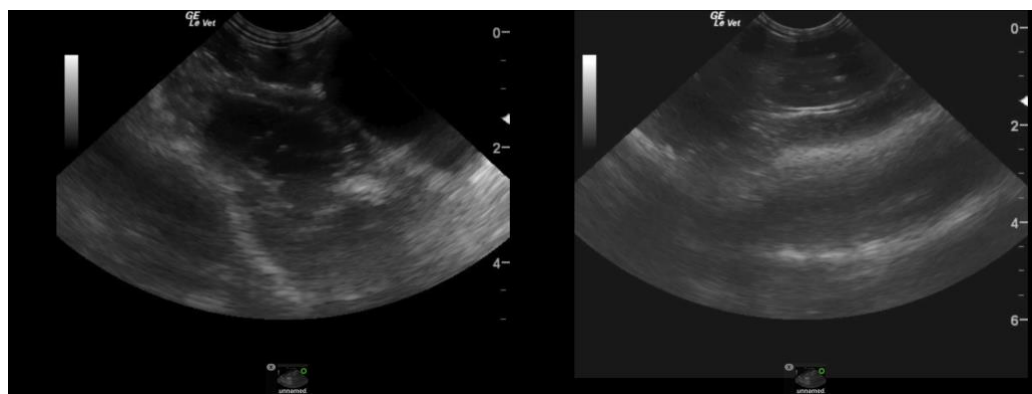
3/14/22

## ULTRASONOGRAPHIC FINDINGS

- Structurally unremarkable abdomen

## INTERPRETATION OF THE FINDINGS & FURTHER RECOMMENDATIONS

No evidence of significant disease. Dietary intolerance or occult parasitism expected. Cannot absolutely rule out portosystemic shunting, however, structurally the liver appears unremarkable, however, further imaging under higher resolution would be necessary for this approach. If portosystemic shunt is suspected, then bile acid profile indicated.





**PATIENT**

Johnny Randolph

**The information and recommendations provided are based on the images presented by the referring veterinarian. No evaluation can be communicated regarding pathology that was not visible in the image/video clips provided.**

**SPECIES**

Feline

Thank you for this referral. If the clinical or image interpretation does not parallel your findings or if I can be of any further assistance please contact me.

**BREED**

DSH

**Eric Lindquist**, DMV, DABVP, Cert. IVUSS, CEO of SonoPath.com  
info@SonoPath.com

**SEX**

Intact Male

**AGE**

7 Months

**WEIGHT**

4 Years

**INTERPRETED BY**

Eric Lindquist, DMV  
DABVP, Cert. IVUSS

**IMAGING  
PERFORMED BY**

Melissa Pascucci

**HOSPITAL NAME**

American AH

**REFERRING VET**

Melissa Pascucci

**INVOICE**

13421

**DATE**

3/14/22