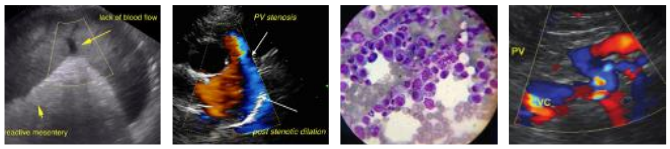

SonoPath.com
1-800-838-4268 info@sonopath.com

PATIENT

Ziggy Matos

SPECIES

Canine

BREED

Pitbull

SEX

Neutered Male

AGE

1

WEIGHT

75

INTERPRETED BY

Eric Lindquist, DMV DABVP, Cert. IVUSS

IMAGING PERFORMED BY

Jenn

HOSPITAL NAME

Rockaway AH

REFERRING VET

Dr. Maniar

INVOICE

21613

DATE

3/13/23

PRESENTING CLINICAL SIGNS

History: re check prev u/s showed full stomach on 3/11

LIMITED ULTRASONOGRAPHIC EXAMINATION

The upper gastrointestinal tract was empty in this patient. Normal transit of chyme into the small intestinal was present.

ULTRASONOGRAPHIC FINDINGS

- Normalized upper GI tract

INTERPRETATION OF THE FINDINGS & FURTHER RECOMMENDATIONS

No evidence of pathology.

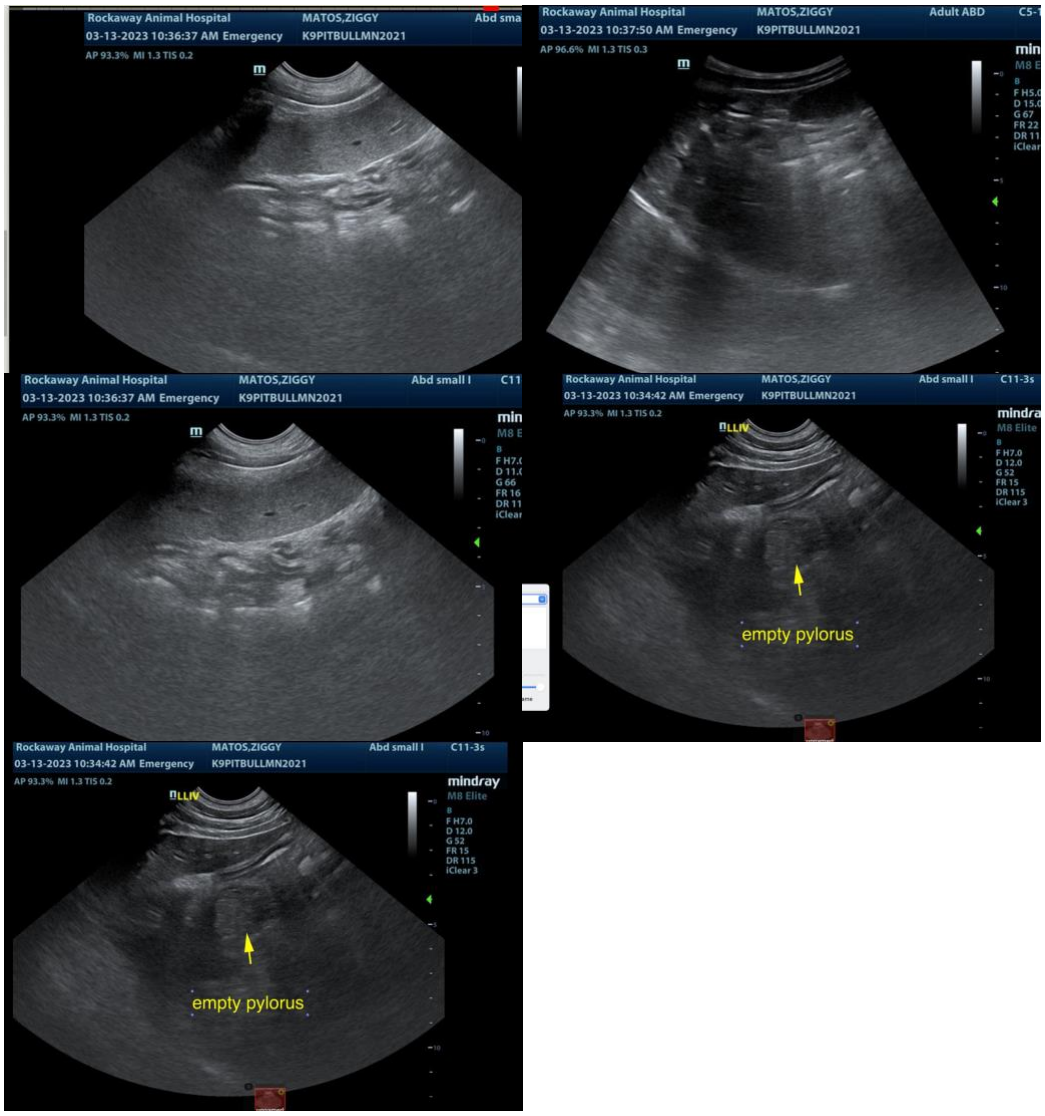

The information and recommendations provided are based on the images presented by the

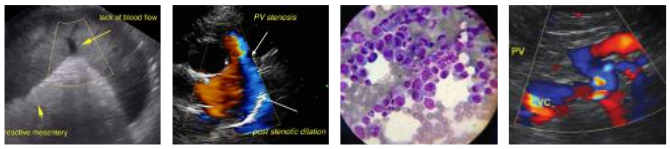

SonoPath.com
1-800-838-4268 info@sonopath.com

PATIENT

Ziggy Matos

SPECIES

Canine

BREED

Pitbull

SEX

Neutered Male

AGE

1

WEIGHT

75

INTERPRETED BY

Eric Lindquist, DMV
DABVP, Cert. IVUSS

IMAGING PERFORMED BY

Jenn

HOSPITAL NAME

Rockaway AH

REFERRING VET

Dr. Maniar

INVOICE

21613

DATE

3/13/23

referring veterinarian. No evaluation can be communicated regarding pathology that was not visible in the image/video clips provided.

Thank you for this referral. If the clinical or image interpretation does not parallel your findings or if I can be of any further assistance please contact me.

Eric Lindquist, DMV, DABVP, Cert. IVUSS, CEO of SonoPath.com
info@SonoPath.com