



PATIENT

Tre Cool MacInnis

SPECIES

Feline

BREED

Domestic Shorthair

SEX

Neutered male

AGE

11 ½ years

WEIGHT

3.79 lbs

INTERPRETED BY

Eric Lindquist, DMV
DABVP, Cert. IVUSS

IMAGING PERFORMED BY

Dr. Trudeau

HOSPITAL NAME

Petworks VH

REFERRING VET

Dr. Trudeau

INVOICE

43244

DATE

3/13/23

PRESENTING CLINICAL SIGNS

History: Follow - up u/s from Inv # 44836 Feb 8, 2023 ongoing weight loss and decreased appetite
These are images of just the pancreatic region (near stomach and near the right kidney)

ULTRASONOGRAPHIC EXAMINATION OF THE ABDOMEN

Spleen

The **spleen** was borderline enlarged at 1.2 cm.

Pancreas

The **pancreas** is enlarged, irregular and hypoechoic measuring up to 1.3 cm with a dilated duct. Nodular and cystic changes were noted.

The mesenteric lymph nodes were round and mildly enlarged measuring up to 0.5 cm.

ULTRASONOGRAPHIC FINDINGS

Progressively prominent, irregular pancreas. Pronounced hyperplasia, emerging carcinoma or pancreatic lymphoma are all possible.

Mildly enlarged mesenteric lymph nodes.

Borderline enlarged spleen.

INTERPRETATION OF THE FINDINGS & FURTHER RECOMMENDATIONS

***5 still images and 8 videos were submitted

Ultrasound-guided FNA is indicated.

Maldigestion panel, three view chest radiographs and full CNS examination is recommended to examine for occult disease that could be responsible for the weight loss. Evaluation for competitive eating environments should also be considered.



PATIENT

Tre Cool MacInnis

SPECIES

Feline

BREED

Domestic Shorthair

SEX

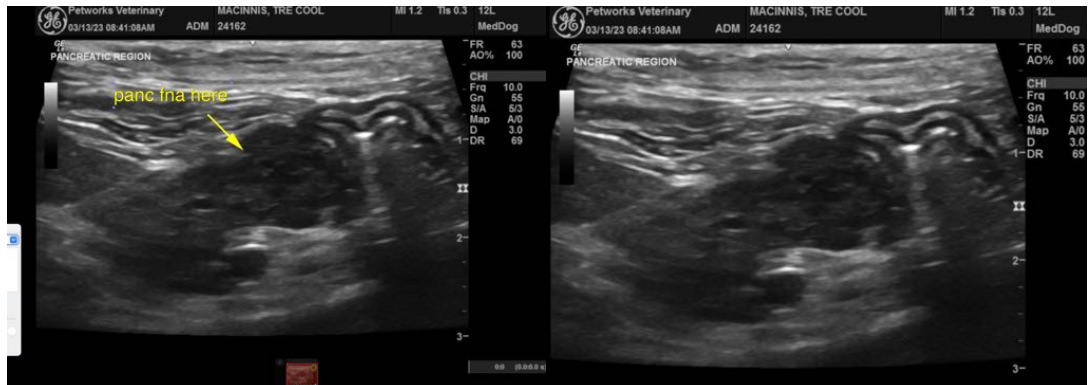
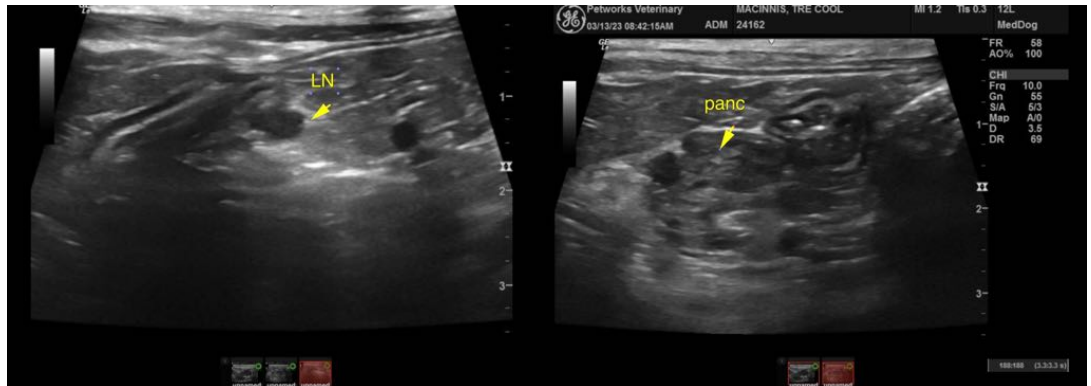
Neutered male

AGE

11 ½ years

WEIGHT

3.79 lbs



INTERPRETED BY

Eric Lindquist, DMV
DABVP, Cert. IVUSS

IMAGING PERFORMED BY

Dr. Trudeau

HOSPITAL NAME

Petworks VH

REFERRING VET

Dr. Trudeau

INVOICE

43244

DATE

3/13/23

The information and recommendations provided are based on the images presented by the referring veterinarian/sonographer. No evaluation can be communicated regarding pathology that was not visible in the image/video clips provided.

Thank you for this referral. If the clinical or image interpretation does not parallel your findings or if I can be of any further assistance please contact me.

Eric Lindquist, DMV, DABVP, Cert. IVUSS, CEO of SonoPath.com
info@SonoPath.com