



PATIENT

Lala Grazyna

SPECIES

Canine

BREED

Cockapoo

SEX

Spayed Female

AGE

22 Months

WEIGHT

14.3 Pounds

INTERPRETED BY

Eric Lindquist, DMV

DABVP, Cert. IVUSS

IMAGING PERFORMED BY

Dr. Kim

HOSPITAL NAME

Ridgefield Park AH

REFERRING VET

Dr. Kim

INVOICE

36140

DATE

3/13/22

PRESENTING CLINICAL SIGNS

Here for possible remnant ovary. P was spayed 6 months- afterwards, O noticed bloody discharge/spotting. P bites/licks vagina since spay. Dr. requests second opinion to verify possible remnant ovary.

ULTRASONOGRAPHIC EXAMINATION OF THE ABDOMEN

Urinary System

The **urinary bladder**, trigone, and pelvic urethra presented normal thicknesses and normal tone. The ureters were not visible which is normal. No uroliths or sediment were visualized and anechoic urine was present. No evidence of inflammatory or neoplastic changes were noted. Ureteral papillae were normal.

The **kidneys** revealed normal size and structure, corticomedullary definition and ratio for this age. The cortices presented largely uniform texture with normal echogenic relationship to liver and spleen. Medullary structure differed distinctly from the cortex and no evidence of pelvic dilation was present. The capsules were acceptably uniform without significant irregularities. The kidneys measured 4.0 cm each.

Adrenal Glands

Both **adrenal glands** were visualized and recognized as having normal shape, size, position and echogenicity for this breed. The phrenic vasculature, glandular echogenicity and detail were unremarkable. Capsule, cortex, and medullary definition were normal for this age patient. The left adrenal gland measured 0.40 cm. The right adrenal gland measured 0.60 cm.

Spleen

The **spleen** presented a smooth homogeneous parenchyma hyperechoic to liver and renal cortical parenchyma. The capsule was smooth without noticeable expansion or deviation from within the spleen or adjacent pathology. The splenic vasculature demonstrated normal volume without signs of congestion or thrombosis. No sonographic evidence of acute or chronic inflammatory, neoplastic, or infarctual changes were noted.

Liver

The **liver** images submitted revealed subjectively normal liver size, contour, and structure. Parenchymal echogenicity was naturally coarse and hypoechoic to the spleen. Vascular and biliary tracts were of normal volume with no evidence of congestion. The gallbladder presented acceptably thin walls with primarily anechoic content. The cystic and common bile ducts were normal. No pathological hepatic lymphadenopathy was evident. No overt structural evidence of inflammatory, infiltrative or regenerative pathology was evident.

Gastrointestinal

Examination of the **gastrointestinal tract** revealed a stomach and intestine free of stasis, of normal wall thickness, acceptable curvilinear mural detail, and peristaltic activity. Small and large intestine demonstrated normal luminal chyme and stool consistency respectively. No obstructive or overt infiltrative disease was noted. No associated abnormal lymphatic activity was noted.



PATIENT

Pancreas

Lala Grazyna

The base and limbs of the **pancreas** were observed to be largely isoechoic to surrounding omental fat. Pancreatic duct and capsular contour were acceptably normal and parenchyma respected normal curvilinear patterns. No overt evidence of active inflammatory or neoplastic disease was noted.

SPECIES

Canine

Free Abdomen

The uterus was thickened, measuring 1.13 cm. The uterine base extended to the mid urinary bladder. The left ovarian fossa revealed a 1.6 cm x 1.08 cm hypoechoic cystic structure, consistent with ovarian remnant.

BREED

Cockapoo

ULTRASONOGRAPHIC FINDINGS

SEX

- Left ovarian remnant and prominent uterus
- Unremarkable abdomen otherwise

Spayed Female

INTERPRETATION OF THE FINDINGS & FURTHER RECOMMENDATIONS

Recommend left remnant removal and resection of the uterus to the level of the cervix.

AGE

22 Months

WEIGHT

14.3 Pounds

INTERPRETED BY

Eric Lindquist, DMV

DABVP, Cert. IVUSS

IMAGING PERFORMED BY

Dr. Kim

HOSPITAL NAME

Ridgefield Park AH

REFERRING VET

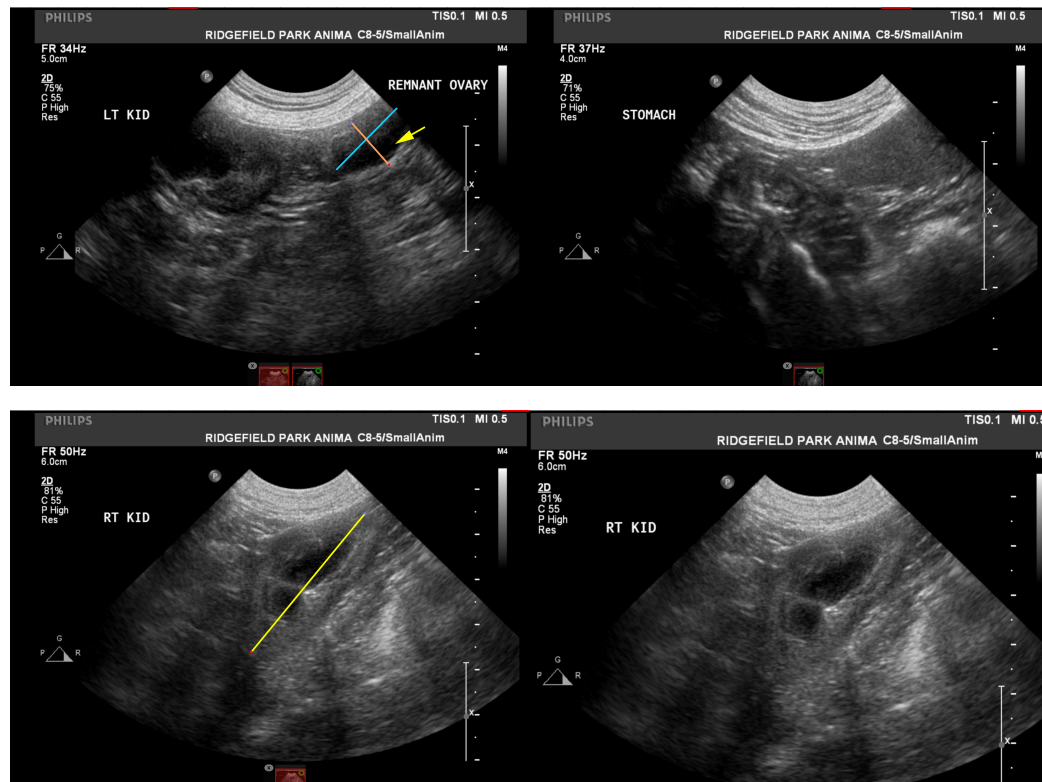
Dr. Kim

INVOICE

36140

DATE

3/13/22





PATIENT

Lala Grazyna

SPECIES

Canine

BREED

Cockapoo

SEX

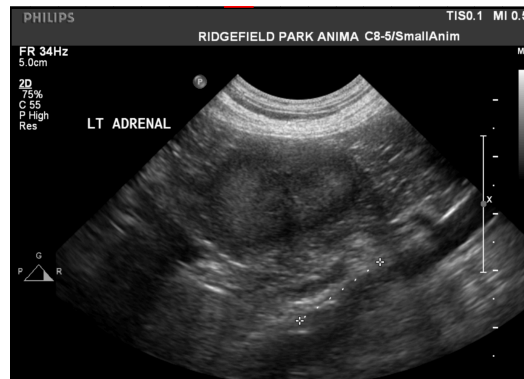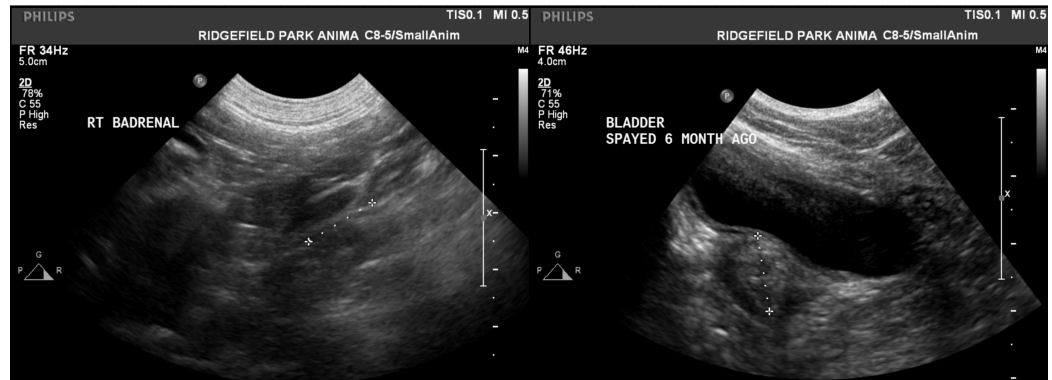Spayed Female

AGE

22 Months

WEIGHT

14.3 Pounds



INTERPRETED BY

Eric Lindquist, DMV

DABVP, Cert. IVUSS

IMAGING PERFORMED BY

Dr. Kim

HOSPITAL NAME

Ridgefield Park AH

REFERRING VET

Dr. Kim

INVOICE

36140

DATE

3/13/22

The information and recommendations provided are based on the images presented by the referring veterinarian/sonographer. No evaluation can be communicated regarding pathology that was not visible in the image/video clips provided.

Thank you for this referral. If the clinical or image interpretation does not parallel your findings or if I can be of any further assistance please contact me.

Eric Lindquist, DMV, DABVP, Cert. IVUSS, CEO of SonoPath.com

info@SonoPath.com