



PATIENT PRESENTING CLINICAL SIGNS

Katie Weaver

In early Feb. 2022 Katie presented for a routine exam and was found to have lost weight and was tachycardic. Her T4 level was normal, but in the gray zone above 2.5. Chest radiographs taken during past 2 weeks appeared normal and Katie's BP was normal today, 150 mmHg with the doppler unit. She has continued to lose weight. She was given 0.7mg butorphanol IV to lightly sedate for the cardiac ultrasound exam today.

SPECIES

Feline

Abnormal PE/Chem/CBC/UA Results: T4 was 3.4ug/dl on 2/8/22 (normal, but gray zone above 2.5)

BREED ULTRASONOGRAPHIC EXAMINATION OF THE HEART

DSH

SEX

Spayed Female

AGE

14 Years 10 Months

WEIGHT

8 Pounds

FELINE CARDIAC PARAMETERS	BODY WEIGHT (kg)	HR (BPM)	IVSd (cm)	LVIDd (cm)	LVWd (cm)	FS (%)	EF (%)
NORMAL PARAMETER	-----	150-240	0.3-0.6	1.0-2.1	0.25-0.6	35-67	80-100
PATIENT		NM		1.5		30	
FELINE CARDIAC PARAMETERS	LA/AO (Boon)	LA/AO HEART BASE (Sisson)	LA 2D 4-chamber long axis AS to FW (Sisson) (cm)	LVOT VEL. (m/s)	RVOT VEL. (m/s)	IVRT (m/)	
NORMAL PARAMETER	<1.5	0.88-1.79	0.7-1.7	<1.6	<1.3	40-60	
PATIENT	1.0	1.3	1.21		0.7	NM	
Adapted from June Boon, Veterinary Echocardiography, 1998 Sisson D et al. JVIM 1991; 5: 232, Jacobs et al. Am J Vet Res 1985; 46:1705							

INTERPRETED BY

Eric Lindquist, DMV

DABVP, Cert. IVUSS

IMAGING PERFORMED BY

Dr. Alex McFeely

HOSPITAL NAME

Straley Vet Associates

REFERRING VET

Dr. Alex McFeely

INVOICE

36137

DATE

3/13/22

Cardiac Presentation

The echocardiogram in this patient demonstrated normal **left atrial** size based on 3 separate methods of LA evaluation. The cranial and caudal **mitral** valve leaflets presented normal linear structure, extension in systole, and union in diastole with normal kinesis. The **left ventricle** presented thicknesses with linear contour and was not dilated nor restricted. The **myocardium** presented normal echogenicity without subjective evidence of significant fibrotic or ischemic disease. **Contractility** of the ventricular walls was adequate and in normal range for this patient evidenced by the fractional shortening measurement and subjective evaluation of the different regions of the myocardium. The **left ventricular outflow** tract demonstrated normal laminar flow and subjective structural integrity. The **right atrium** and auricle revealed normal size, structure and content. No evidence of masses was noted. **Tricuspid** valvular assessment demonstrated adequate linear morphology and kinesis. The **right ventricle** was of normal size (1/3 diameter of LV), chordae structure, myocardial echogenicity and thickness. **Pulmonary outflow** tract assessment revealed normal valve structure, laminar flow, and diameter (approx. 1:1 pa/ao ratio). No visible **pericardial** or free pleura fluid was noted. The cranial **mediastinum and pericardial and extra-cardiac regions** were free of masses in the visible window.

ULTRASONOGRAPHIC FINDINGS

- Normal echocardiogram with normal contractility, structures and volumes.

INTERPRETATION OF THE FINDINGS & FURTHER RECOMMENDATIONS

No structural evidence of disease.



PATIENT

Katie Weaver

SPECIES

Feline

BREED

DSH

SEX

Spayed Female

AGE

14 Years 10 Months

WEIGHT

8 Pounds

INTERPRETED BY

Eric Lindquist, DMV

DABVP, Cert. IVUSS

IMAGING PERFORMED BY

Dr. Alex McFeely

HOSPITAL NAME

Straley Vet Associates

REFERRING VET

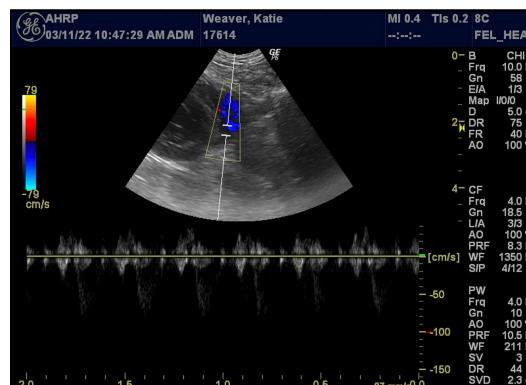
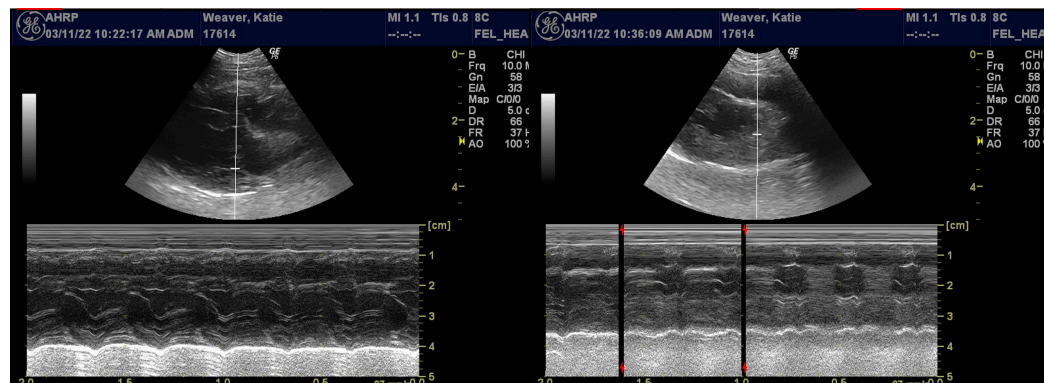
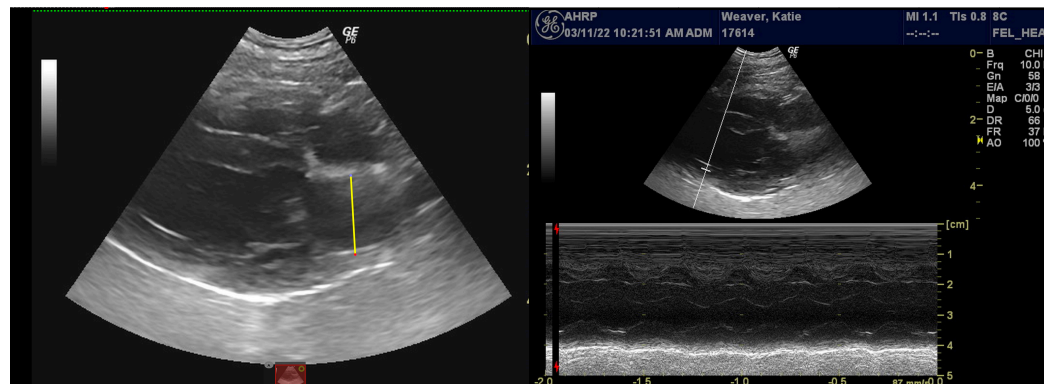
Dr. Alex McFeely

INVOICE

36137

DATE

3/13/22



The information and recommendations provided are based on the images presented by the referring veterinarian/sonographer. No evaluation can be communicated regarding pathology that was not visible in the image/video clips provided.

Thank you for this referral. If the clinical or image interpretation does not parallel your findings or if I can be of any further assistance please contact me.

Eric Lindquist, DMV, DABVP, Cert. IVUSS, CEO of SonoPath.com

info@SonoPath.com