



**PATIENT**

Toty Gubacs-Collins

**SPECIES**

Canine

**BREED**

Hound x

**SEX**

Neutered Male

**AGE**

7 Years

**WEIGHT**

44 lbs

**INTERPRETED BY**

Eric Lindquist, DMV,  
DABVP (CFM), Cert.  
IVUSS

**IMAGING PERFORMED BY**

Eric Lindquist, DMV,  
DABVP (CFM), Cert.  
IVUSS

**HOSPITAL NAME**

Franklin Lakes Animal  
Hospital

**REFERRING VET**

Dr. Ward

**INVOICE**

73619

**DATE**

3/12/26

**PRESENTING CLINICAL SIGNS**

Weight loss. Normal bloodwork.

**ULTRASONOGRAPHIC EXAMINATION OF THE ABDOMEN**

**Urinary System**

The **urinary bladder**, trigone, and pelvic urethra presented normal thicknesses and normal tone. The ureters were not visible which is normal. No uroliths or sediment were visualized and anechoic urine was present. No evidence of inflammatory or neoplastic changes were noted. Ureteral papillae were normal. The pelvic urethra was imaged 3.0 cm beyond the cystourethral junction.

The residual prostate measures 6.0 mm.

The **kidneys** revealed normal size and structure, corticomedullary definition and ratio for this age. The cortices presented largely uniform texture with normal echogenic relationship to liver and spleen. Medullary structure differed distinctly from the cortex and no evidence of pelvic dilation was present. The capsules were acceptably uniform without significant irregularities. Left kidney measured 6.17 cm. Right kidney measured 6.4 cm.

**Adrenal Glands**

Both **adrenal glands** were visualized and recognized as having normal shape, size, position and echogenicity for this breed. The phrenic vasculature, glandular echogenicity and detail were unremarkable. Capsule, cortex, and medullary definition were normal for this age patient. Left measured 1.34 cm x 0.45 cm. Right measured 1.94 cm x 0.93 cm at the cranial pole and 0.54 cm at the caudal pole.

**Spleen**

The **spleen** was folded upon itself cranially. It presented a smooth homogeneous parenchyma hyperechoic to liver and renal cortical parenchyma. The capsule was smooth without noticeable expansion or deviation from within the spleen or adjacent pathology. The splenic vasculature demonstrated normal volume without signs of congestion or thrombosis. No sonographic evidence of acute or chronic inflammatory, neoplastic, or infarctual changes were noted.

Trace amount of free fluid noted between the splenic fold and the liver.

**Liver**

The **liver** images submitted revealed subjectively normal liver size, contour, and structure. Parenchymal echogenicity was naturally coarse and hypoechoic to the spleen. Vascular and biliary tracts were of normal volume with no evidence of congestion. The gallbladder presented acceptably thin walls with primarily anechoic content. The cystic and common bile ducts were normal. No pathological hepatic lymphadenopathy was evident. No overt structural evidence of inflammatory, infiltrative or regenerative pathology was evident.

**Gastrointestinal**

Examination of the **gastrointestinal tract** revealed a stomach and intestine free of stasis, of normal wall thickness, acceptable curvilinear mural detail, and peristaltic activity. Small and large intestine



**PATIENT**

Toty Gubacs-Collins

**SPECIES**

Canine

**BREED**

Hound x

**SEX**

Neutered Male

**AGE**

7 Years

**WEIGHT**

44 lbs

**INTERPRETED BY**

Eric Lindquist, DMV,  
DABVP (CFM), Cert.  
IVUS

**IMAGING PERFORMED BY**

Eric Lindquist, DMV,  
DABVP (CFM), Cert.  
IVUS

**HOSPITAL NAME**

Franklin Lakes Animal  
Hospital

**REFERRING VET**

Dr. Ward

**INVOICE**

73619

**DATE**

3/12/26

demonstrated normal luminal chyme and stool consistency respectively. No obstructive or overt infiltrative disease was noted. No associated abnormal lymphatic activity was noted.

**Pancreas**

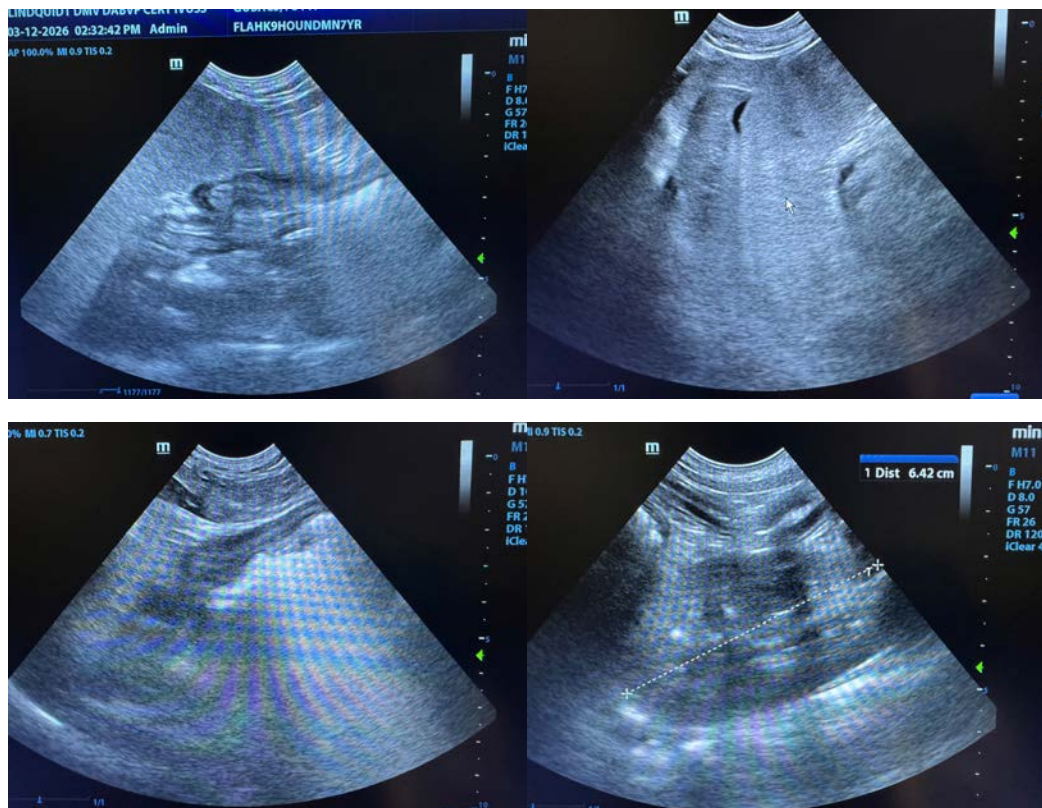
The base and limbs of the **pancreas** were observed to be largely isoechoic to surrounding omental fat. Pancreatic duct and capsular contour were acceptably normal and parenchyma respected normal curvilinear patterns. No overt evidence of active inflammatory or neoplastic disease was noted.

**ULTRASONOGRAPHIC FINDINGS**

- Essentially normal abdomen with trace unexplainable free fluid at the splenic fold, which may be a positional issue.

**INTERPRETATION OF THE FINDINGS & FURTHER RECOMMENDATIONS**

If further weight loss occurs, screening FNA of the spleen and liver may be appropriate. No other evidence of pathology.





**PATIENT**

Toty Gubacs-Collins

**SPECIES**

Canine

**BREED**

Hound x

**SEX**

Neutered Male

**AGE**

7 Years

**WEIGHT**

44 lbs

**INTERPRETED BY**

Eric Lindquist, DMV,  
 DABVP (CFM), Cert.  
 IVUSS

**IMAGING PERFORMED BY**

Eric Lindquist, DMV,  
 DABVP (CFM), Cert.  
 IVUSS

**HOSPITAL NAME**

Franklin Lakes Animal  
 Hospital

**REFERRING VET**

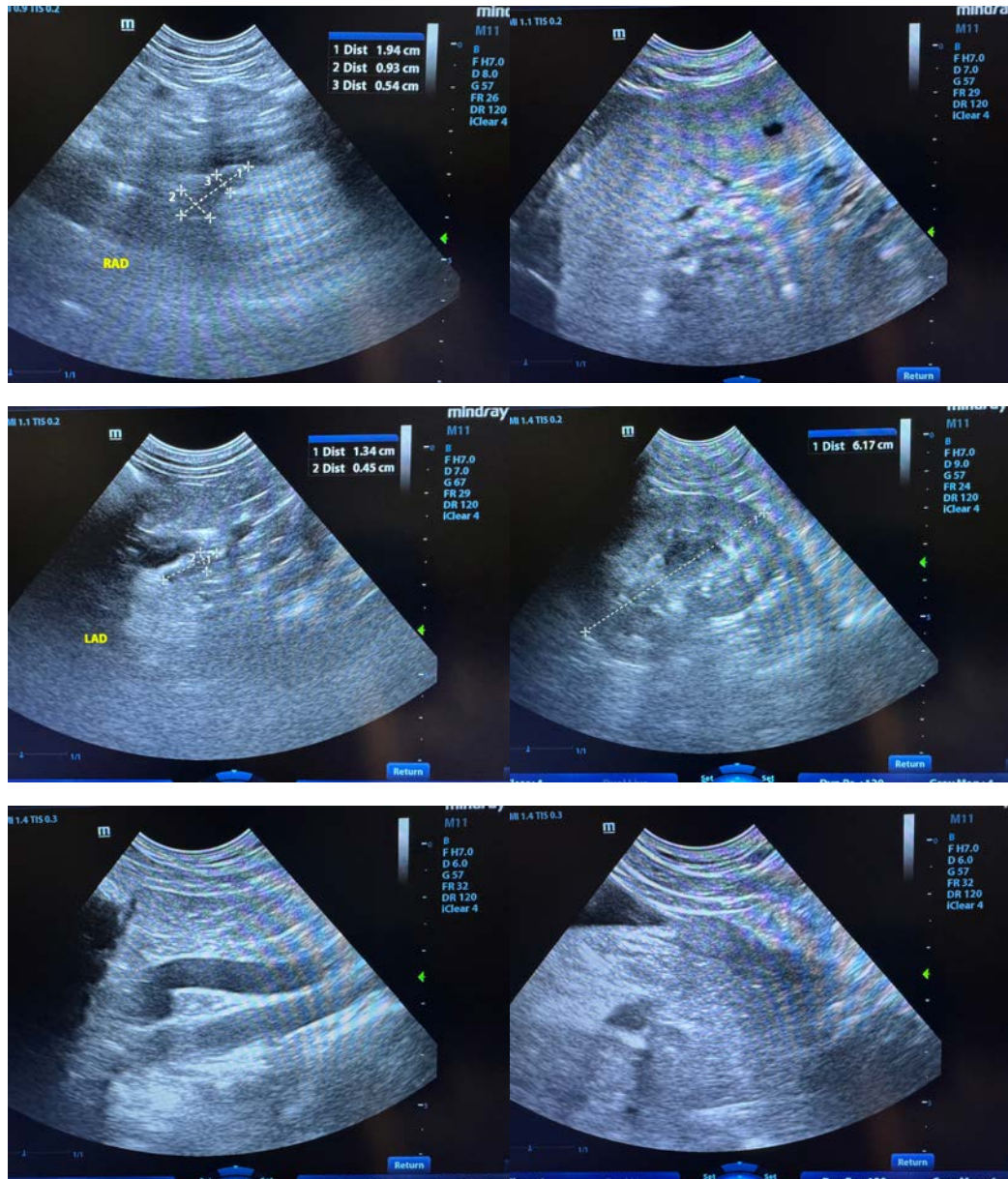
Dr. Ward

**INVOICE**

73619

**DATE**

3/12/26



The information and recommendations provided are based on the images presented by the referring veterinarian/sonographer. No evaluation can be communicated regarding pathology that was not visible in the image/video clips provided.

Thank you for this referral. If the clinical or image interpretation does not parallel your findings or if I can be of any further assistance please contact me.

**Eric Lindquist, DMV, DABVP(CFM), Cert. IVUSS,**  
 CEO, Owner, Founder -- SonoPath.com  
[info@SonoPath.com](mailto:info@SonoPath.com)