

PATIENT

Oscar Medberry

SPECIES

Feline

BREED

DSH

SEX

Neutered Male

AGE

10 Years

WEIGHT

10.5 pounds

INTERPRETED BY

Eric Lindquist, DMV,
DABVP (Canine &
Feline), Cert. IVUSS

**IMAGING
PERFORMED BY**

Pamela Harrigan,
RDCS

HOSPITAL NAME

All Friends Animal
Hospital

REFERRING VET

Dr. Lisa Sabbadini
DVM

INVOICE

14294

DATE

03/12/26

PRESENTING CLINICAL SIGNS

- Routine blood work: ALT 297 - repeated two weeks later and now 376. Some weight loss, otherwise clinically normal cat. Concerned about primary liver disease vs neoplasia vs other

ULTRASONOGRAPHIC EXAMINATION OF THE ABDOMEN

Urinary System

The **urinary bladder**, trigone, and pelvic urethra presented normal thicknesses and normal tone. The ureters were not visible which is normal. No uroliths or sediment were visualized, and anechoic urine was present. No evidence of inflammatory or neoplastic changes were noted. Ureteral papillae were normal.

The **kidneys** presented a relatively uniform cortical hyperechogenicity when compared to the renal medulla, spleen and liver. No overt masses were noted. Corticomedullary definition was nebulous and the ratio favored the cortex slightly. The ureters were not visible and assumed to be normal. These changes are most consistent with chronic interstitial nephritis yet infiltrative disease could not be entirely ruled out without biopsy though neoplasia is not suspected. The left kidney measured 4.3 cm in length. The right kidney measured 5.1 cm in length. Cortical infarcts and dorsal cortical collapse was noted in portions of both kidneys. Slight pyelectasia was noted in the left kidney.

Adrenal Glands

Both **adrenal glands** were visualized and recognized as having normal shape, size, position and echogenicity for this breed. The phrenic vasculature, glandular echogenicity and detail were unremarkable. Capsule, cortex, and medullary definition were normal for this age patient. The left adrenal gland measured 0.44 cm width. The right adrenal gland measured 0.39 cm width.

Spleen

The **spleen** was mildly enlarged with uniform, but subtly micronodular parenchyma, and undulating capsular contour. This is consistent with reactive spleen owing to immune stimulus or early infiltrative disease such as mast cell disease or lymphoma. 25-gauge FNA would be ideal if weight loss is an issue to differentiate early round cell neoplasia versus splenitis or reactive spleen all of which can present in this manner. The spleen measured 1.4 cm.

Liver

The **liver** images submitted revealed subjectively normal liver size, contour, and structure. Parenchymal echogenicity was naturally coarse and hypoechoic to the spleen. Vascular and biliary tracts were of normal volume with no evidence of congestion. The gallbladder presented acceptably thin walls with primarily anechoic content. The cystic and common bile ducts were normal. No pathological hepatic lymphadenopathy was evident. No overt structural evidence of inflammatory, infiltrative or regenerative pathology was evident.

Gastrointestinal

The **gastrointestinal** presentation revealed mild uniform prominence of the gastric mucosa as well as areas of "ropey" small intestinal wall with slight disruption of the normal 1:3 muscularis/mucosal ratio. The intestinal submucosa was slightly irregular, thickened and hyperechoic suggestive of low grade,



PATIENT

Oscar Medberry

SPECIES

Feline

BREED

DSH

SEX

Neutered Male

AGE

10 Years

WEIGHT

10.5 pounds

INTERPRETED BY

Eric Lindquist, DMV,
DABVP (Canine &
Feline), Cert. IVUSS

IMAGING PERFORMED BY

Pamela Harrigan,
RDCS

HOSPITAL NAME

All Friends Animal
Hospital

REFERRING VET

Dr. Lisa Sabbadini
DVM

INVOICE

14294

DATE

03/12/26

chronic disease. No concerning lymphadenopathy was visible. No evidence of obstruction was present. Chronic inflammatory bowel disease is likely with a low possibility of an early neoplastic event such as lymphoma. Full thickness tissue biopsies via open laparotomy, ideally guided by intraoperative ultrasound in order to obtain the most representative mural sample, would be necessary to rule out this possibility. Intestinal wall thickness measured up to 0.34 cm.

Pancreas

The base and limbs of the **pancreas** were observed to be largely isoechoic to surrounding omental fat. Some mild parenchymal remodeling, however, with mild deviation from curvilinear normalcy was observed. Pancreatic duct and capsular irregularities were present consistent with age related changes. If pain upon imaging (+ Murphy sign) was present or if the patient is focally painful in subxiphoid palpation then low-grade smoldering chronic pancreatitis should be suspected.

Free Abdomen

The enlarged mesenteric **lymph nodes** presented normal length to width ratio with slight, swollen contour. There was no loss of parenchymal detail. This is most consistent with reactive lymphadenitis or lymphatic hyperplasia. The lymph nodes measured up to 0.47 cm.

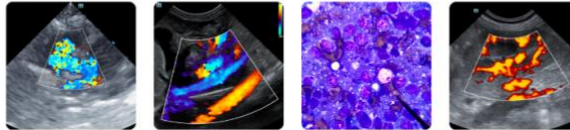
ULTRASONOGRAPHIC FINDINGS

- Diffuse mild intestinal thickening without neoplastic criteria.
- Mesenteric lymphadenopathy.
- Interstitial nephrosis renal pattern with cortical infarcts and cortical collapse.
- Scalloping spleen- emerging round cell neoplasia, reactive spleen, splenitis all possible.
- Age-related abdominal changes.
- Low-grade inflammatory hepatopathy or reactive hepatopathy owing to mesenteric inflammation absorbed through the portal system.

INTERPRETATION OF THE FINDINGS & FURTHER RECOMMENDATIONS

Cannot rule out an emerging round cell neoplasia, especially given the splenic presentation. Urinary workup is warranted if not already performed. 25-gauge FNA of the spleen is indicated as well as the mesenteric lymph nodes if accessible, however, may be difficult to have adequate exfoliation upon FNA alone. Full thickness intestinal and lymph node biopsies may be necessary for a definitive diagnosis.

Maldigestion panel, three view chest radiographs and full CNS examination is recommended to examine for occult disease that could be responsible for the weight loss. Evaluation for competitive eating environments should also be considered.



PATIENT

Oscar Medberry

SPECIES

Feline

BREED

DSH

SEX

Neutered Male

AGE

10 Years

WEIGHT

10.5 pounds

INTERPRETED BY

Eric Lindquist, DMV,
DABVP (Canine &
Feline), Cert. IVUSS

**IMAGING
PERFORMED BY**

Pamela Harrigan,
RDACS

HOSPITAL NAME

All Friends Animal
Hospital

REFERRING VET

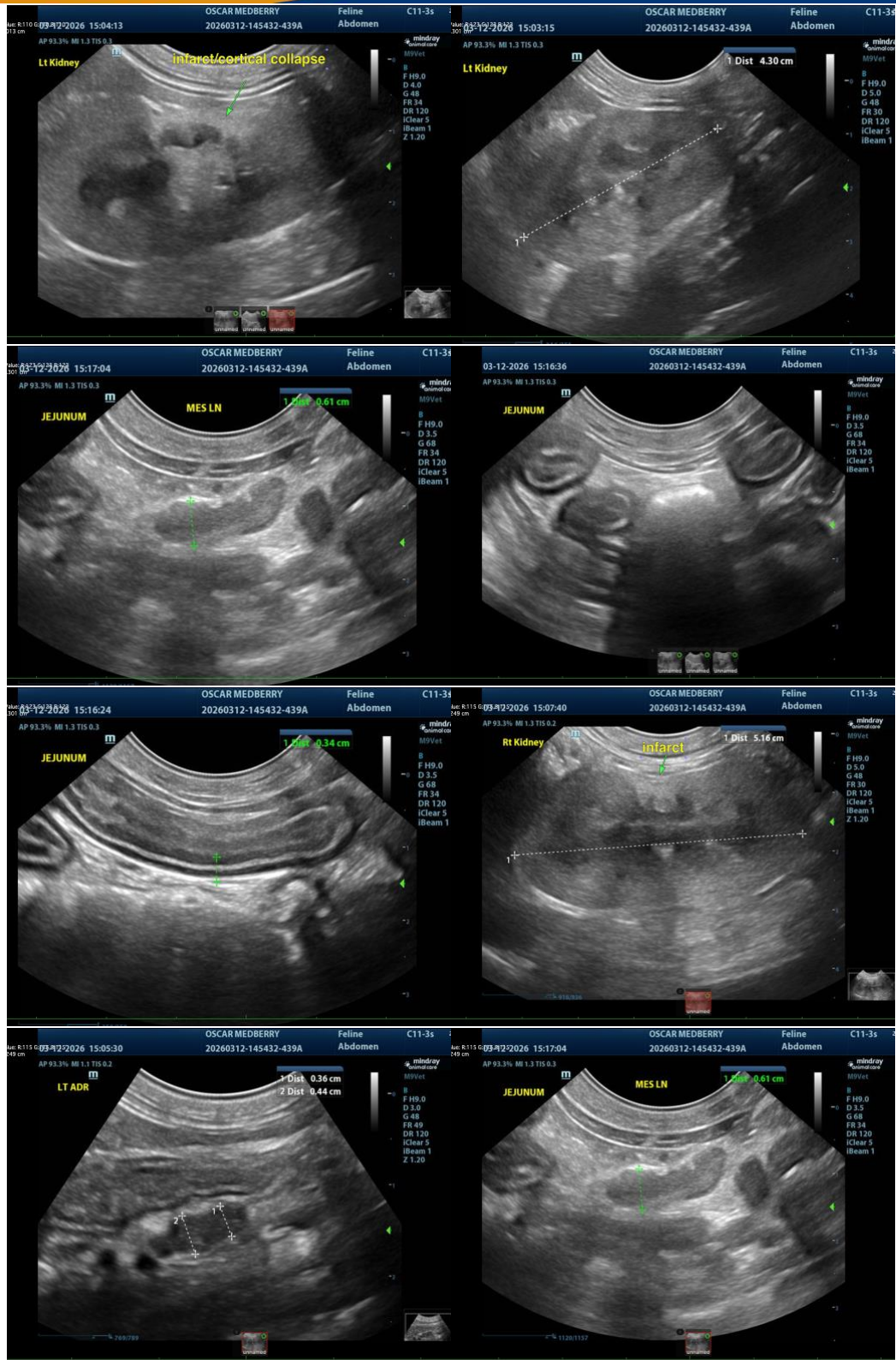
Dr. Lisa Sabbadini
DVM

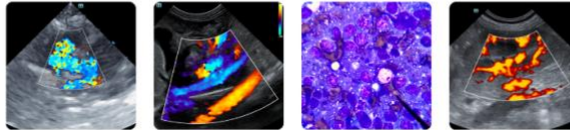
INVOICE

14294

DATE

03/12/26





PATIENT

Oscar Medberry

SPECIES

Feline

BREED

DSH

SEX

Neutered Male

AGE

10 Years

WEIGHT

10.5 pounds

INTERPRETED BY

Eric Lindquist, DMV,
DABVP (Canine &
Feline), Cert. IVUSS

IMAGING PERFORMED BY

Pamela Harrigan,
RDCS

HOSPITAL NAME

All Friends Animal
Hospital

REFERRING VET

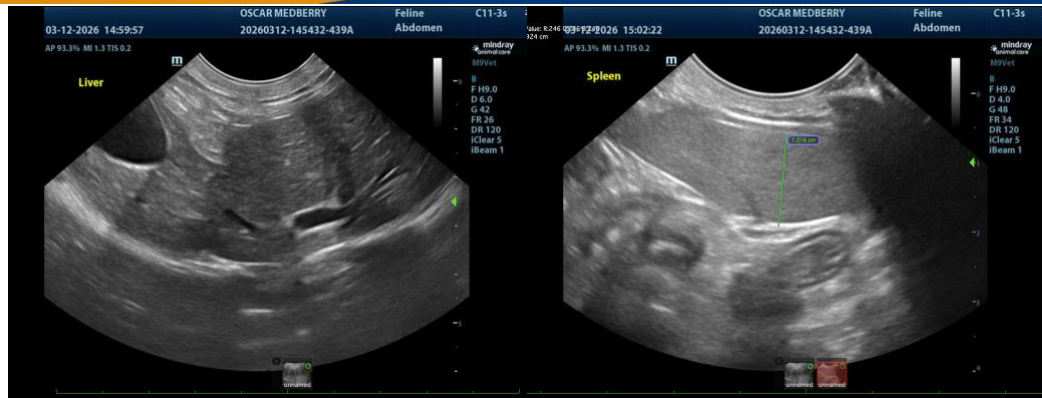
Dr. Lisa Sabbadini
DVM

INVOICE

14294

DATE

03/12/26



The information and recommendations provided are based on the images presented by the referring veterinarian/sonographer. No evaluation can be communicated regarding pathology that was not visible in the image/video clips provided.

Thank you for this referral. If the clinical or image interpretation does not parallel your findings or if I can be of any further assistance, please contact me.

Eric Lindquist, DMV, DABVP(CFM), Cert. IVUSS,

CEO, Owner, Founder -- SonoPath.com

info@SonoPath.com