



## PATIENT

Nico Todd

## SPECIES

Canine

## BREED

Mix

## SEX

Neutered Male

## AGE

4

## WEIGHT

41

## INTERPRETED BY

Eric Lindquist, DMV,  
DABVP (Canine &  
Feline), Cert. IVUSS

## IMAGING PERFORMED BY

Dr. Becky Meier-Gast

## HOSPITAL NAME

Meier VC, PC

## REFERRING VET

Dr. Becky Meier-Gast

## INVOICE

36210

## DATE

3/12/26

## PRESENTING CLINICAL SIGNS

- Nico presented for a dental. Administered .4cc Torbugesic IM for sedation. 300mg Gabapentin and 45mg Cerenia given prior to sedation.
- ECG was placed prior to induction.
- Noticed on ECG grade 1 heart block which progressed to a grade 3 heart block
- Atropine was given and dental was canceled.
- Echo was then performed

## ULTRASONOGRAPHIC EXAMINATION OF THE HEART

CANINE CARDIAC PARAMETERS	MR VMAX (m/s)	TR VMAX (m/s)	LA/AO (M-Mode)	LA/AO (Heart Base; Swe)	FS (%)	EF (%)	EPSS (cm)
NORMAL PARAMETER	4.5-5.5	<2.7	1.3	Up to 1.6	28-40	40-100	<0.6
PATIENT	--	--	1.0	1.0	39	71	0.1
CANINE CARDIAC PARAMETERS	HR (BPM)	AV VMAX (m/s)	PV MAX (m/s)	BODY WEIGHT	LAD LA MAX 4 Chamber	LVIDd Avg; 2D and m-mode short axis (cm)	LVIDs Avg; 2D and m-mode short axis (cm)
NORMAL PARAMETER	50-100	0.7-1.7	0.7-1.6				
PATIENT	--	2.0	.90	41	3.0	3.05	--

### Cardiac Presentation

The echocardiogram in this patient demonstrated normal **left atrial** size based on 3 separate methods of LA evaluation. The cranial and caudal **mitral** valve leaflets presented normal linear structure, extension in systole, and union in diastole with normal kinesis. The **left ventricle** presented thicknesses with linear contour and was not dilated nor restricted. The **myocardium** presented normal echogenicity without subjective evidence of significant fibrotic or ischemic disease. **Contractility** of the ventricular walls was adequate and in normal range for this patient evidenced by the fractional shortening measurement and subjective evaluation of the different regions of the myocardium. The **left ventricular outflow** tract demonstrated normal laminar flow and subjective structural integrity. The **right atrium** and auricle revealed normal size, structure and content. No evidence of masses was noted. **Tricuspid** valvular assessment demonstrated adequate linear



**PATIENT**

Nico Todd

**SPECIES**

Canine

**BREED**

Mix

**SEX**

Neutered Male

**AGE**

4

**WEIGHT**

41

**INTERPRETED BY**

Eric Lindquist, DMV,  
DABVP (Canine &  
Feline), Cert. IVUSS

**IMAGING PERFORMED BY**

Dr. Becky Meier-Gast

**HOSPITAL NAME**

Meier VC, PC

**REFERRING VET**

Dr. Becky Meier-Gast

**INVOICE**

36210

**DATE**

3/12/26

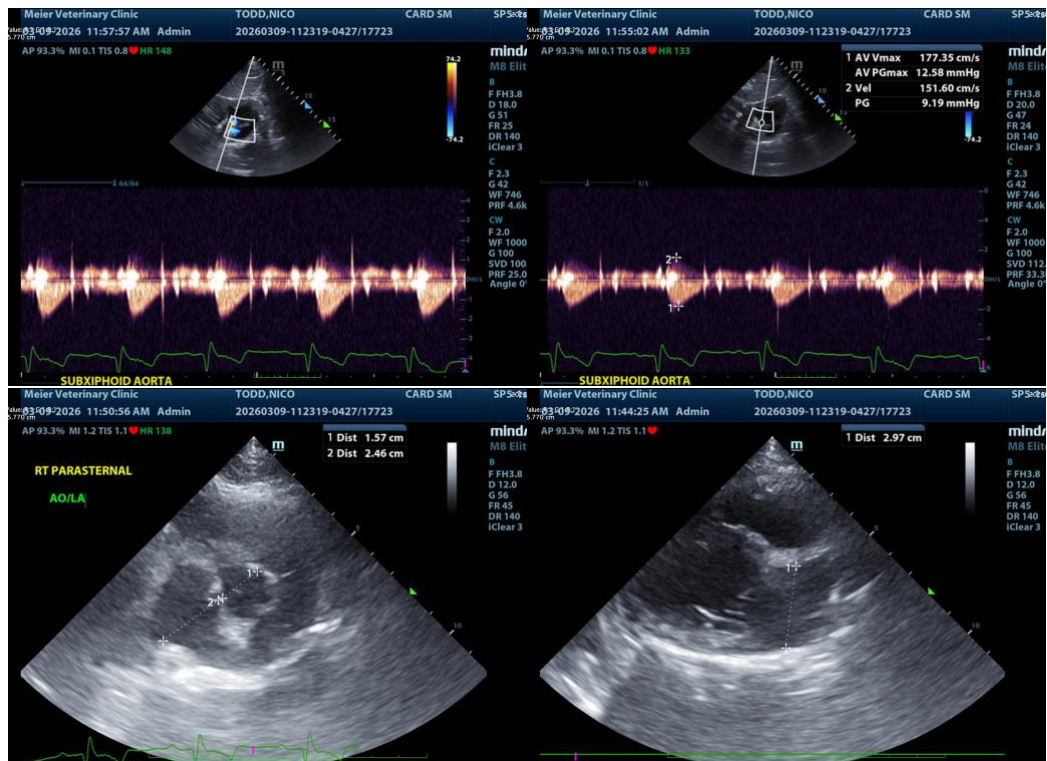
morphology and kinesis. The **right ventricle** was of normal size (1/3 diameter of LV), chordae structure, myocardial echogenicity and thickness. **Pulmonary outflow** tract assessment revealed normal valve structure, laminar flow, and diameter (approx.1:1 pa/ao ratio). No visible **pericardial** or free pleura fluid was noted. The cranial **mediastinum and pericardial and extra-cardiac regions** were free of masses in the visible window.

**ULTRASONOGRAPHIC FINDINGS**

- Normal echocardiogram- no evidence of pathology related to the reported heart block

**INTERPRETATION OF THE FINDINGS & FURTHER RECOMMENDATIONS**

Any management should be based on EKG results.





## PATIENT

Nico Todd

## SPECIES

Canine

## BREED

Mix

## SEX

Neutered Male

## AGE

4

## WEIGHT

41

## INTERPRETED BY

Eric Lindquist, DMV,  
DABVP (Canine &  
Feline), Cert. IVUSS

## IMAGING PERFORMED BY

Dr. Becky Meier-Gast

## HOSPITAL NAME

Meier VC, PC

## REFERRING VET

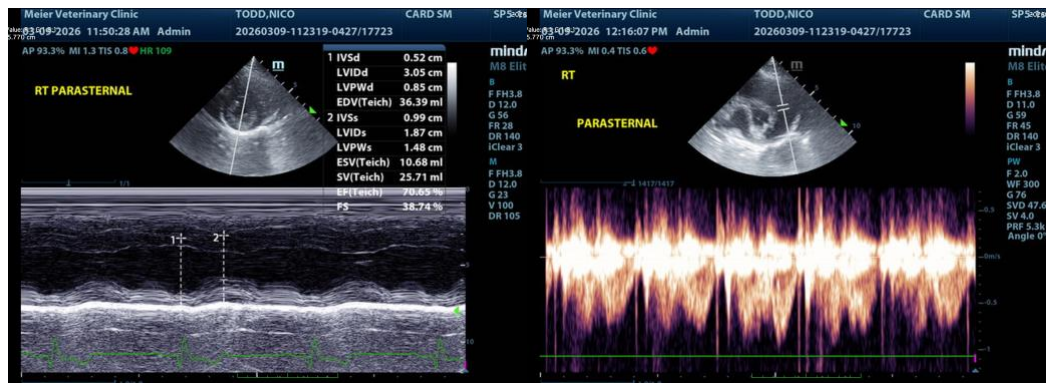
Dr. Becky Meier-Gast

## INVOICE

36210

## DATE

3/12/26



The information and recommendations provided are based on the images presented by the referring veterinarian/sonographer. No evaluation can be communicated regarding pathology that was not visible in the image/video clips provided.

Thank you for this referral. If the clinical or image interpretation does not parallel your findings or if I can be of any further assistance please contact me.

**Eric Lindquist**, DMV, DABVP(CFM), Cert. IVUSS,  
CEO, Owner, Founder -- SonoPath.com  
[info@SonoPath.com](mailto:info@SonoPath.com)