



PATIENT

Ed Truong

SPECIES

Feline

BREED

DLH

SEX

Neutered Male

AGE

6 Years

WEIGHT

11.5 pounds

INTERPRETED BY

Eric Lindquist, DMV,
DABVP(CFM), Cert.
IVUSS

IMAGING PERFORMED BY

Dr. Rodriguez

HOSPITAL NAME

Foxfield Veterinary
Services

REFERRING VET

Dr. Rodriguez

INVOICE

14278

DATE

03/12/26

PRESENTING CLINICAL SIGNS

- Heart murmur 2/6

Abnormal PE/Chem/CBC/UA Results: WNL

ULTRASONOGRAPHIC EXAMINATION OF THE HEART

FELINE CARDIAC PARAMETERS	BODY WEIGHT (lbs)	HR (BPM)	IVSd (cm)	LVIDd (cm)	LVWd (cm)	FS (%)	EF (%)
NORMAL PARAMETER	-----	150-240	0.3-0.6	1.0-2.1	0.25-0.6	35-67	80-100
PATIENT	11.5	280	0.67	1.4	0.72	--	--
FELINE CARDIAC PARAMETERS	LA/AO (M-mode)	LA/AO HEART BASE (Sisson)	LAD LA MAX 4 Chamber		LVOT VEL. (m/s)	RVOT VEL. (m/s)	IVRT (m/)
NORMAL PARAMETER	<1.5	1.6	0.7-1.7		<1.6	<1.3	40-60
PATIENT	2.0	1.9	1.8		--	1.4	NM
Adapted from June Boon, Veterinary Echocardiography, 1998							
Sisson D et al. JVIM 1991; 5: 232, Jacobs et al. Am J Vet Res 1985; 46:1705							

EPSS: 0.1

Cardiac Presentation

The echocardiogram in this patient demonstrated normal **left atrial** size and structure with no evidence of “smoke” or thrombi. The cranial and caudal **mitral** valve leaflets appeared mildly thickened with some insufficiency noted on Doppler. The **left ventricle** presented excessive free wall and septal thicknesses with hypertrophic thicknesses compared to normal for this species. The **myocardium** presented essentially normal echogenicity without immediate signs of fibrotic or ischemic disease. **Contractility** of the ventricular walls was considered excessive for this patient evidenced by the elevated fractional shortening measurement. The **left ventricular outflow** tract demonstrated turbulent laminar flow. Subjective assessment of the **right atrium** and auricle revealed normal size, structure and content. No evidence of masses was noted. **Tricuspid** valvular assessment demonstrated linear morphology. The **right ventricle** was of normal size with normal chordae structure, myocardial echogenicity and thickness. **Pulmonic** tract assessment revealed normal valve structure, laminar flow, and diameter. No visible **pericardial** or free pleura fluid was noted. No echographically detectable evidence of infiltrative disease was visible. The **mediastinum** was free of masses in the visible window.

ULTRASONOGRAPHIC FINDINGS

- Hypertrophic cardiomyopathy phenotype with mild left atrial enlargement.

INTERPRETATION OF THE FINDINGS & FURTHER RECOMMENDATIONS



PATIENT

Ed Truong

SPECIES

Feline

BREED

DLH

SEX

Neutered Male

AGE

6 Years

WEIGHT

11.5 pounds

INTERPRETED BY

Eric Lindquist, DMV,
DABVP(CFM), Cert.
IVUSS

IMAGING PERFORMED BY

Dr. Rodriguez

HOSPITAL NAME

Foxfield Veterinary
Services

REFERRING VET

Dr. Rodriguez

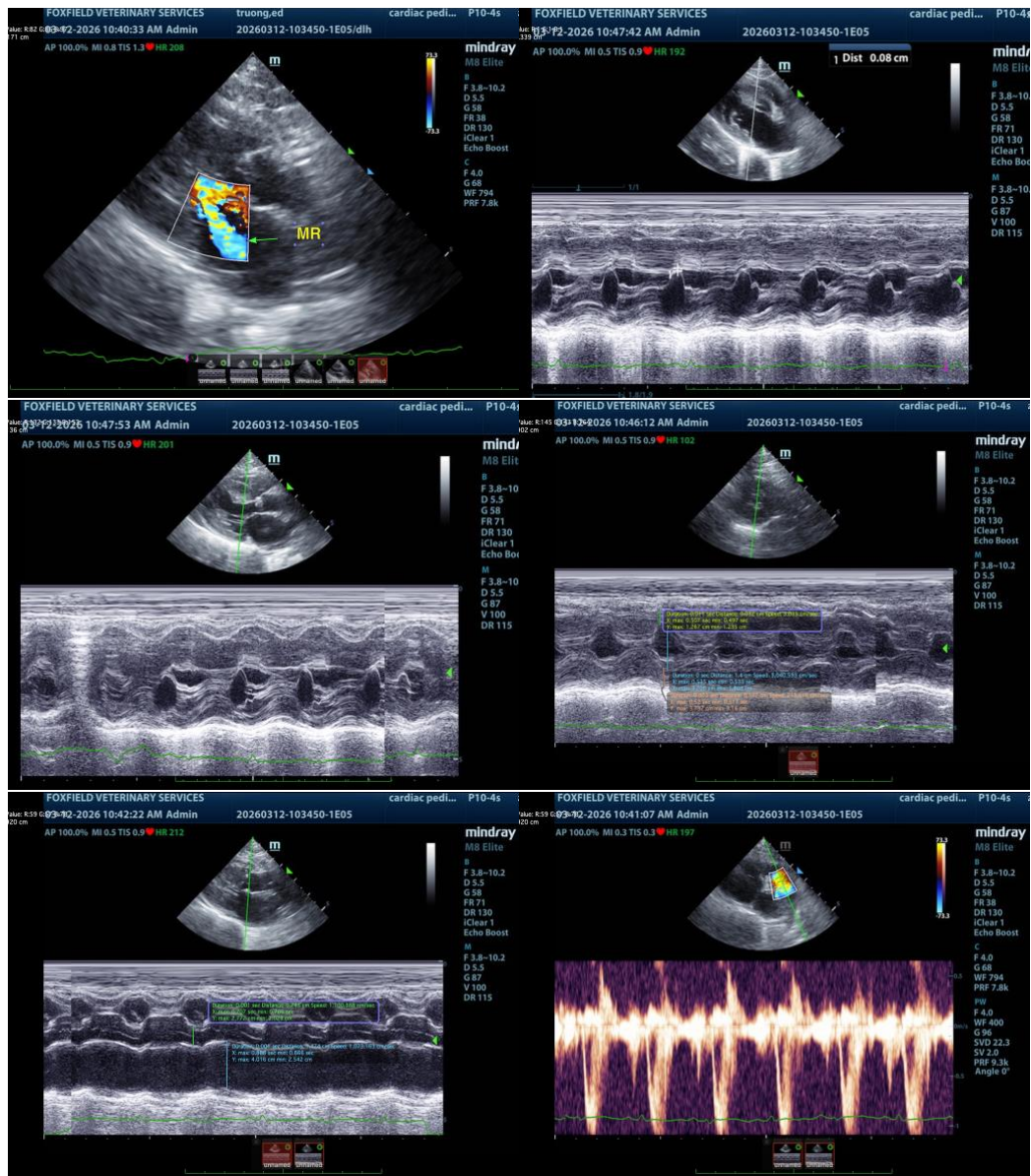
INVOICE

14278

DATE

03/12/26

Recommend initiating Atenolol therapy in this patient at 6.25 to 12.5 mg SID to BID to target a heart rate less than 180. ACE inhibitor therapy could be considered at 0.5 mg/kg SID. Plavix therapy is debatable yet would not be contraindicated. Recheck echo in one month to assess for improvement regarding volume overload as there is left atrial enlargement.





PATIENT

Ed Truong

SPECIES

Feline

BREED

DLH

SEX

Neutered Male

AGE

6 Years

WEIGHT

11.5 pounds

INTERPRETED BY

Eric Lindquist, DMV,
DABVP(CFM), Cert.
IVUSS

IMAGING PERFORMED BY

Dr. Rodriguez

HOSPITAL NAME

Foxfield Veterinary
Services

REFERRING VET

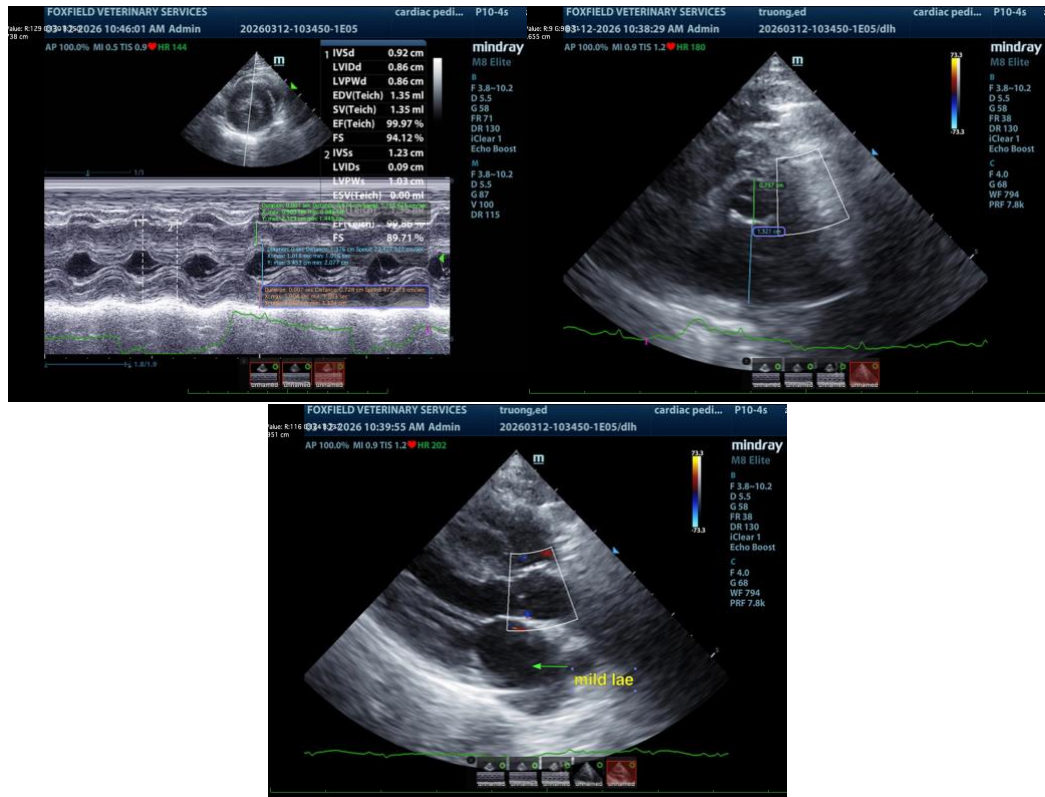
Dr. Rodriguez

INVOICE

14278

DATE

03/12/26



The information and recommendations provided are based on the images presented by the referring veterinarian/sonographer. No evaluation can be communicated regarding pathology that was not visible in the image/video clips provided.

Thank you for this referral. If the clinical or image interpretation does not parallel your findings or if I can be of any further assistance, please contact me.

Eric Lindquist, DMV, DABVP(CFM), Cert. IVUSS,

CEO, Owner, Founder -- SonoPath.com

info@SonoPath.com

Feline Cardiomyopathy

<http://www.sonopath.com/FelineHeartDisease>

Description: Feline hypertrophic cardiomyopathy (HCM) is the most common form of heart disease in cats. There is some evidence that HCM is hereditary in breeds such as the Maine Coon, Persian, American and British Shorthair, and Ragdoll. It affects cats between the ages of 4 months and 17 years (mean age: 5-7 years); however, the median age of diagnosis is much lower in Maine Coons than Domestic Shorthairs or Persians. It has been reported that the underlying mechanism is due to impaired sarcomeric activity caused by mutations that affect the sarcomere's functional proteins. Variable genetic



PATIENT

Ed Truong

SPECIES

Feline

BREED

DLH

SEX

Neutered Male

AGE

6 Years

WEIGHT

11.5 pounds

INTERPRETED BY

Eric Lindquist, DMV,
DABVP(CFM), Cert.
IVUSS

IMAGING PERFORMED BY

Dr. Rodriguez

HOSPITAL NAME

Foxfield Veterinary
Services

REFERRING VET

Dr. Rodriguez

INVOICE

14278

DATE

03/12/26

expression and diverse environmental factors make it such that the symptomatology and conditions for pathological onset fluctuate. Although two related mutations affecting the MYBPC3 gene have already been identified in the Maine Coon and the Ragdoll, they do not alone comprise adequate screening tools. In keeping with research findings in human medicine, there are likely many other mutations involved in the development of HCM.

The main morphological characteristic of HCM is a hypertrophied, non-dilated left ventricle in the absence of an obvious cause of secondary left ventricular concentric hypertrophy, such as aortic stenosis, systemic hypertension, or hyperthyroidism. The hypertrophy can be diffuse or segmental, symmetric or asymmetric. The pathophysiological mainstay of HCM is diastolic dysfunction due to increased filling pressures, which leads to left atrial enlargement and finally congestive heart failure (CHF); however, systolic dysfunction, which is rarely an obvious condition, also seems to play a role. Dynamic left ventricular outflow obstruction caused by the systolic anterior motion (SAM) of the anterior mitral valve leaflet may also occur, leading to turbulence within the left ventricular outflow tract (LVOT), increased left ventricular pressures, and secondary mitral regurgitation. Baroreceptor down-regulation ensues in the myocardium, stimulating the release of catecholamine and activating the renin-angiotensin-aldosterone system. All of this leads to myocardial remodeling and gives rise to progressive ischemic events, fibrotic myo- and endocardial infiltration, narrowed coronary arteries, and overall myocardial dysfunction. Ischemic cardiomyopathy may also occur; it is characterized by left ventricular dilation and subsequent systolic dysfunction.

Although HCM is primarily a genetic disease, systemic hypertension or hyperthyroidism is sometimes present concomitantly and can lead to left ventricular hypertrophy in the absence of genetic HCM. Therefore, it is imperative to monitor the systolic blood pressure, renal function, and total T4 assay.

Diagnosics: Physical exam findings may include a heart murmur due to a left ventricular outflow disturbance or secondary mitral insufficiency, S3 or S4 gallop, muffled heart sounds with pleural effusion, thromboembolic disease, syncope, and sinus bradycardia; however, in the majority of cases, no overt clinical signs are evident. The presence of a systolic heart murmur is neither specific nor sensitive for HCM, as it has been shown that heart murmurs may be present in both symptomatic and asymptomatic cats.

Radiographically speaking, left atrial enlargement is best visualized with a properly positioned dorso-ventral thoracic view, which is easier to obtain in cases where cats are experiencing respiratory distress. Yet, a recent study showed that left atrial enlargement might be absent even on thoracic radiographs in cats with left-sided CHF.

One can conduct echocardiographic assessments of HCM cases using M-Mode or 2D imaging. These assessments will typically reveal diffuse or segmental, symmetric or asymmetric left ventricular concentric hypertrophy with an end-diastolic thickness greater than 5.5 mm. Fractional shortening is usually increased. Systolic anterior motion of the anterior mitral valve leaflet and a basal septal bulge may be present, leading to dynamic LVOT obstruction. The size of the left atrium determines the severity of the disease. Although it has been shown that alterations in tissue Doppler velocities can precede left ventricular hypertrophy in HCM, this has not yet been investigated in a large population group and therefore has not yet been established as a viable screening tool.

NT-proBNP is a cardiac biomarker that can help differentiate whether respiratory distress is due to heart disease or respiratory disease. It might also provide added information for early detection of cardiac disease in subclinical patients, especially in high-risk breeds, such as Main Coons and Persians; however, it has not yet replaced echocardiography as the gold standard



PATIENT

diagnostic tool. Reports indicate that NT-proBNP is higher in feline patients with systemic hypertension, severe renal failure, and hyperthyroidism.

Ed Truong

SPECIES

Feline

BREED

DLH

SEX

Neutered Male

AGE

6 Years

WEIGHT

11.5 pounds

INTERPRETED BY

Eric Lindquist, DMV,
DABVP(CFM), Cert.
IVUSS

Therapy: Because patients with HCM often experience a long subclinical stage, there is a lack of evidence regarding early medical treatment of HCM. Therapy is indicated when there are clinical and echographic signs suggestive of HCM. Initial therapy consists of administering enalapril (0.25-0.5 mg/kg PO Q24hr), benazepril (0.25-0.5 mg/kg PO Q24hr), and furosemide (1 mg/kg BID). Once the left atrial diameter exceeds 22 mm or it is possible to detect a spontaneous echocontrast in the left atrium, clopidogrel (18.75 mg/cat PO Q24hr) is recommended. Atenolol (6.25-12.5 mg/cat PO Q12-24hr) can be given if tachycardia is present and/or dynamic LVOT obstruction is present. (Sotalol [1-2 mg/kg BID] can be used instead of atenolol.) Extended-release diltiazem (30-45 mg/cat Q12-24hr) can also be used in cats with diastolic dysfunction and left atrial enlargement, but without dynamic LVOT obstruction.

Medical management of acute CHF due to HCM includes 2-4 doses of furosemide (1mg/kg IV, IM, or SC Q30min), which is subsequently reduced to 1-2 mg/kg PO Q12-24hr and then to the lowest effective dose as soon as possible to help avoid significant dehydration. Alternatively, one can administer furosemide as a CRI (0.5-1mg/kg/hour) and discontinue once the respiratory rate normalizes. Pleurocentesis is essential in cases of pleural effusion. Nitroglycerin paste (0.25-0.5 inches) can be applied to the shaven axilla or pinna Q12hr, although the efficacy in cats remains unclear. Oxygen therapy and cage rest are also essential. Initially, most arrhythmias (VPCs or tachyarrhythmias) should not be treated since they are often partially or entirely resolved with preload treatments. Yet, in cases of persistent ventricular tachycardia, one should administer lidocaine boluses (0.5-1mg/kg) 30 minutes apart and then as a CRI (10-20 ug/kg/min) until rhythmic stabilization occurs. Sedation of dyspneic cats with butorphanol (0.2-0.3 mg/kg) reduces stress and stress-induced sympathetic overactivation.

Outpatient management of chronic HCM after a first CHF event has occurred is based on ultrasound, ECG, and systolic blood pressure findings, and usually includes furosemide, an angiotensin-converting enzyme (ACE) inhibitor, and clopidogrel. Diltiazem can be used in accordance with the guidelines outlined above. Atenolol should be avoided once CHF has occurred and in cases of ventricular tachyarrhythmias.

IMAGING PERFORMED BY

Dr. Rodriguez

HOSPITAL NAME

Foxfield Veterinary
Services

REFERRING VET

Dr. Rodriguez

Restrictive Cardiomyopathy (RCM): RCM is defined as cardiomyopathy with impaired myocardial relaxation and compliance due to infiltrative disease (neoplasia), myocardial fibrosis, remodeling, or idiopathy. Two forms of RCM are currently recognized: i) an endomyocardial form, which is exemplified by echogenic fibrous bridging across the left ventricular free wall to the ventricular septum and accompanied by significant valvular dystrophic change; and ii) a myocardial form, which is typified primarily by myocardial fibrotic remodeling without significant valvular pathology. In both cases, one observes severe left and mild-moderate right atrial enlargement, normal to slightly thickened ventricular walls, normal to decreased fractional shortening (24-30%), and an LV diameter greater than 18mm. The pathological changes may be universal or segmental. The following distinguishes RCM from HCM: a hyperechoic appearance of the heart due to fibrotic remodeling; normal to decreased fractional shortening; absence of significant myocardial hypertrophy; a tendency toward biatrial enlargement; and poor response to therapy. The diagnostic approach and therapy for RCM is the same as that outlined for HCM.

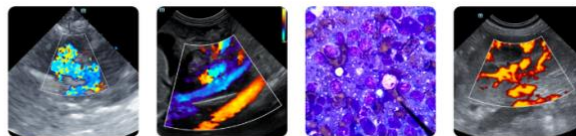
INVOICE

14278

DATE

03/12/26

Thyrotoxic Cardiomyopathy: Thyrotoxic cardiomyopathy occurs because of a hypermetabolic state and systemic hypertension, which stimulate the renin-angiotensin-aldosterone system, prompting myocardial or endocardial remodeling. Most cardiac changes—mild ventricular septal and free wall thickening, myocardial or endocardial fibrosis, increased LV diastolic dimension, normal to mildly elevated fractional shortening, and biatrial enlargement (in severe cases)—do not cause significant hemodynamic pathology and should not be confused with HCM. Yet, when the disease progresses it can lead to decreased fractional shortening, significant fibrosis, and other signs that are similar to RCM, including CHF. No specific cardiac therapy is usually recommended for thyrotoxic cardiomyopathy unless severe changes are noted. Cardiac changes



PATIENT

Ed Truong

may be resolved with Iodine 131 therapy or adequately managed using methimazole (5 mg BID-TID); however, if the hypertension does not resolve, then atenolol (6.25-12.5 mg/cat/day) or amlodipine (0.625-1.25 mg/cat/day) should be started as well.

SPECIES

Feline

Hypertensive Cardiomyopathy: Left ventricular hypertrophy can occur subsequent to systemic hypertension; as a result, both structural changes (concentric hypertrophy) and functional changes (decreased diastolic function) may transpire. Although acute increases in left ventricular wall thickness have been reported in hypertensive cats, the concomitant presence of HCM should be considered in patients with severe concentric hypertrophy. **Therapy is geared towards managing hypertension. If the systolic blood pressure is persistently greater than 180 mmHG, then one can administer either atenolol (6.25-12.5 mg PO Q12-24hr) or amlodipine (0.625-1.25 mg PO Q12-24hr) to reach a target systolic blood pressure of < 150 mmHg and heart rate < 180 bpm.** Enalapril (0.25-0.5 mg/kg PO Q24hr) or benazepril (0.25-0.5 mg/kg PO Q24hr) can also be given, but only if there is CHF or a marked enlargement of the left atrium (left atrial aortic root ratio [LA:Ao] > 2:1). Hypotension is the main side effect with these medications. One should conduct a routine follow-up 5 days after treatment to monitor blood pressure and then biweekly or monthly following therapy.

BREED

DLH

SEX

Neutered Male

AGE

6 Years

Pseudohypertrophy: Pseudohypertrophy is a temporary hypertrophy of the left ventricle in response to systemic volume contraction and is often associated with systemic diseases, such as hypertension, renal failure, neoplasia, dehydration, hypertension, and many other conditions. It is sometimes associated with flow murmurs that may be new in onset. Pseudohypertrophy is not considered to be a cardiac pathology; it is a localized response by the heart to a systemic disease process that affects volume contraction.

WEIGHT

11.5 pounds

INTERPRETED BY

Eric Lindquist, DMV,
DABVP(CFM), Cert.
IVUSS

Myocarditis: Myocarditis in cats seems to present with left ventricular concentric hypertrophy; however, this has rarely been confirmed on necropsy. Nevertheless, the occurrence of a transient left ventricular concentric hypertrophy along with a transient increase in cTnI values is suggestive of myocarditis. Concentric hypertrophy—particularly asymmetric or segmental hypertrophy—should be differentiated from infiltrative disease (e.g. lymphoma).

IMAGING PERFORMED BY

Dr. Rodriguez

References:

HOSPITAL NAME

Foxfield Veterinary
Services

Abbott J. Feline hypertrophic cardiomyopathy: an update. *Vet Clin North Am Small Anim Pract* 2010;40:685-700.

REFERRING VET

Dr. Rodriguez

Glaus T, Wess G. Left ventricular hypertrophy in the cat: When hypertrophic cardiomyopathy is not hypertrophic cardiomyopathy. *Schweiz Arch Tierheilkd* 2010;152:325-30.

INVOICE

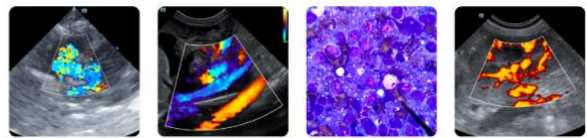
14278

Payne JR, Borgeat K, Connolly DJ, et al. Prognostic indicators in cats with hypertrophic cardiomyopathy. *J Vet Intern Med* 2013;27:1427-36.

DATE

03/12/26

Rishniw M, Pion PD. Is treatment of feline hypertrophic cardiomyopathy based in science or faith? A survey of cardiologists and a literature search. *J Feline Med Surg* 2011;13:487-97.



PATIENT

Ed Truong

SPECIES

Feline

BREED

DLH

SEX

Neutered Male

AGE

6 Years

WEIGHT

11.5 pounds

INTERPRETED BY

Eric Lindquist, DMV,
DABVP(CFM), Cert.
IVUSS

IMAGING PERFORMED BY

Dr. Rodriguez

HOSPITAL NAME

Foxfield Veterinary
Services

REFERRING VET

Dr. Rodriguez

INVOICE

14278

DATE

03/12/26

Trehiou-Sechi E, Tissier R, Gouni V, et al. Comparative echocardiographic and clinical features of hypertrophic cardiomyopathy in 5 breeds of cats: a retrospective analysis of 344 cases (2001-2011). *J Vet Intern Med* 2012;26:532-41.