



PATIENT

Belly Qin

SPECIES

Canine

BREED

Corgi

SEX

Neutered Male

AGE

6 Years

WEIGHT

33

INTERPRETED BY

Eric Lindquist, DMV,
DABVP (CFM), Cert.
IVUSS

IMAGING PERFORMED BY

Dr. Shen Li

HOSPITAL NAME

Dr. Shen Li Veterinary
Service

REFERRING VET

Dr. Shen Li

INVOICE

73645

DATE

3/12/26

PRESENTING CLINICAL SIGNS

Present for a non healing spot on RTL. Sensitive stomach. Screening ultrasound.

Abnormal PE/Chem/CBC/UA Results: Pending

ULTRASONOGRAPHIC EXAMINATION OF THE ABDOMEN

Urinary System

The **urinary bladder**, trigone, and pelvic urethra presented normal thicknesses and normal tone. The ureters were not visible which is normal. No uroliths or sediment were visualized and anechoic urine was present. No evidence of inflammatory or neoplastic changes were noted. Ureteral papillae were normal. The pelvic urethra was imaged 1.0 cm beyond the cystourethral junction.

The **kidneys** revealed normal size and structure, corticomedullary definition and ratio for this age. The cortices presented largely uniform texture with normal echogenic relationship to liver and spleen. Medullary structure differed distinctly from the cortex and no evidence of pelvic dilation was present. The capsules were acceptably uniform without significant irregularities. Right kidney measured 5.5 cm. Left kidney measured 4.7 cm.

Adrenal Glands

The regions of the **adrenal glands** were unremarkable.

Spleen

The **spleen** presented a smooth homogeneous parenchyma hyperechoic to liver and renal cortical parenchyma. The capsule was smooth without noticeable expansion or deviation from within the spleen or adjacent pathology. The splenic vasculature demonstrated normal volume without signs of congestion or thrombosis. No sonographic evidence of acute or chronic inflammatory, neoplastic, or infarctual changes were noted.

Liver

The **liver** images submitted revealed subjectively normal liver size, contour, and structure. Parenchymal echogenicity was naturally coarse and hypoechoic to the spleen. Vascular and biliary tracts were of normal volume with no evidence of congestion. The gallbladder presented acceptably thin walls with primarily anechoic content. The cystic and common bile ducts were normal. No pathological hepatic lymphadenopathy was evident. No overt structural evidence of inflammatory, infiltrative or regenerative pathology was evident.

Gastrointestinal

The **gastrointestinal tract** was structurally unremarkable. Curvilinear patterns were maintained. Some areas of hyperperistalsis noted consistent with irritable bowel. No evidence of ingesta or transiting chyme noted.

Pancreas

The base and limbs of the **pancreas** were observed to be largely isoechoic to surrounding omental fat. Pancreatic duct and capsular contour were acceptably normal and parenchyma respected normal curvilinear patterns. No overt evidence of active inflammatory or neoplastic disease was noted.



PATIENT

Belly Qin

SPECIES

Canine

BREED

Corgi

SEX

Neutered Male

AGE

6 Years

WEIGHT

33

INTERPRETED BY

Eric Lindquist, DMV,
DABVP (CFM), Cert.
IVUS

IMAGING PERFORMED BY

Dr. Shen Li

HOSPITAL NAME

Dr. Shen Li Veterinary
Service

REFERRING VET

Dr. Shen Li

INVOICE

73645

DATE

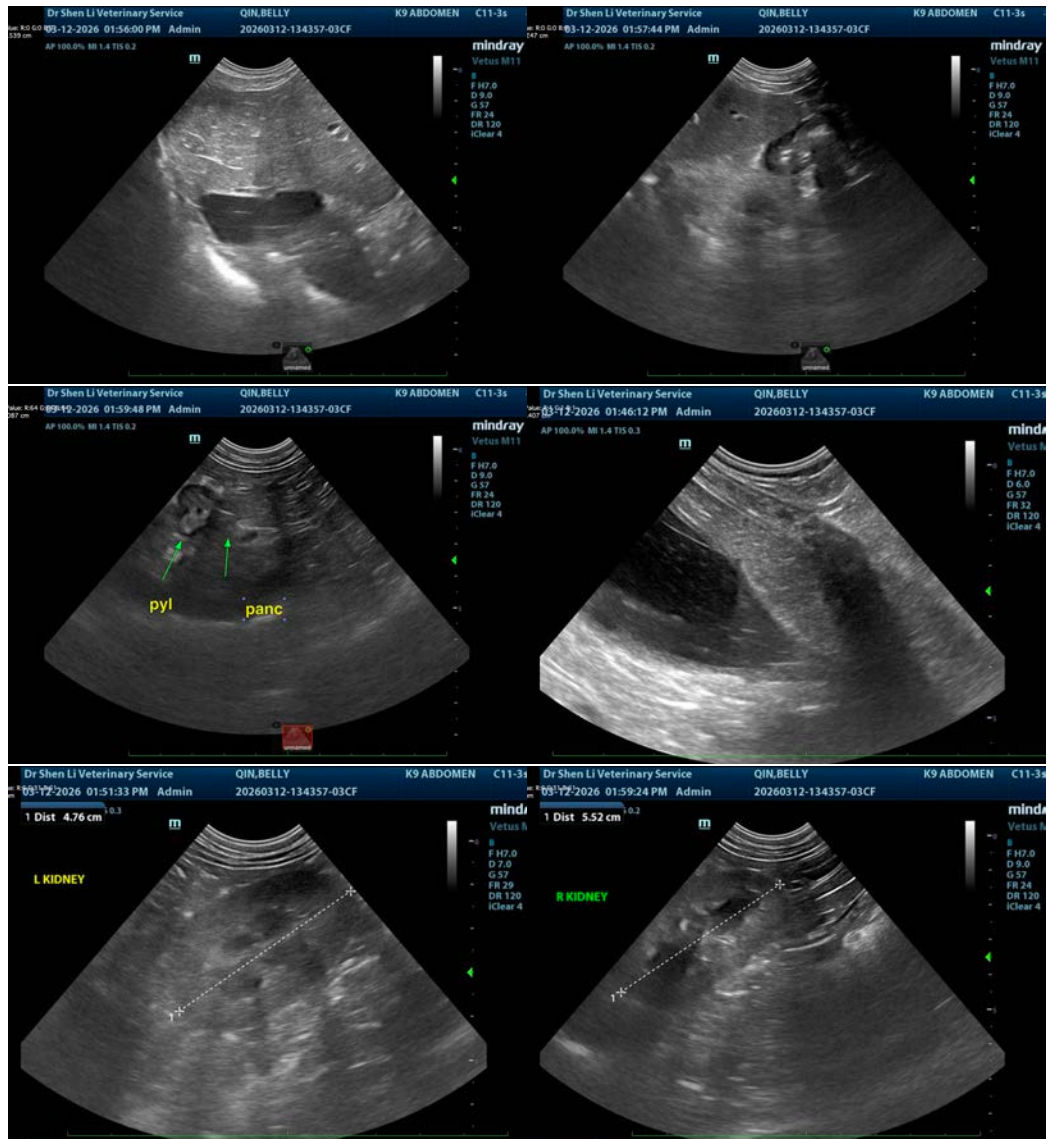
3/12/26

ULTRASONOGRAPHIC FINDINGS

- Minor irritable bowel presentation, unremarkable abdomen otherwise.

INTERPRETATION OF THE FINDINGS & FURTHER RECOMMENDATIONS

Screening for occult Addison's indicated. Parasite management and diet change indicated. No evidence of significant disease.





PATIENT

Belly Qin

SPECIES

Canine

BREED

Corgi

SEX

Neutered Male

AGE

6 Years

WEIGHT

33

INTERPRETED BY

Eric Lindquist, DMV,
DABVP (CFM), Cert.
IVUSS

IMAGING PERFORMED BY

Dr. Shen Li

HOSPITAL NAME

Dr. Shen Li Veterinary
Service

REFERRING VET

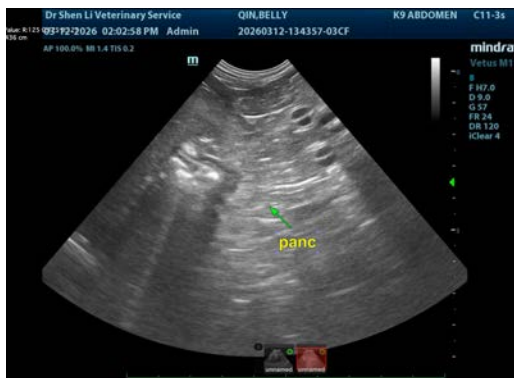Dr. Shen Li

INVOICE

73645

DATE

3/12/26



The information and recommendations provided are based on the images presented by the referring veterinarian/sonographer. No evaluation can be communicated regarding pathology that was not visible in the image/video clips provided.

Thank you for this referral. If the clinical or image interpretation does not parallel your findings or if I can be of any further assistance please contact me.

Eric Lindquist, DMV, DABVP(CFM), Cert. IVUSS,
CEO, Owner, Founder -- SonoPath.com
info@SonoPath.com