

PATIENT

Bandit Prystowski

SPECIES

Canine

BREED

Jack Russell

SEX

Neutered Male

AGE

11 Years

WEIGHT

36 pounds

INTERPRETED BY

Eric Lindquist, DMV,
DABVP(CFM), Cert.
IVUSS

IMAGING PERFORMED BY

Vincent Ravancho CVT

HOSPITAL NAME

All Creatures Great &
Small Fairfield

REFERRING VET

Dr. Perez

INVOICE

14281

DATE

03/12/26

PRESENTING CLINICAL SIGNS

- Wellness

Abnormal PE/Chem/CBC/UA Results: U/A 1+ Proteinuria USG 1.033

ULTRASONOGRAPHIC EXAMINATION OF THE ABDOMEN

Urinary System

The **urinary bladder**, trigone, and pelvic urethra presented normal thicknesses and normal tone. The ureters were not visible which is normal. No uroliths or sediment were visualized, and anechoic urine was present. No evidence of inflammatory or neoplastic changes were noted. Ureteral papillae were normal.

The **iliac trifurcation** was unremarkable.

The **kidneys** revealed normal size and structure, corticomedullary definition and ratio for this age. The cortices presented largely uniform texture with normal echogenic relationship to liver and spleen. Medullary structure differed distinctly from the cortex and no evidence of pelvic dilation was present. The capsules were acceptably uniform without significant irregularities. The left kidney measured 4.12 cm in length. The right kidney measured 5.9 cm in length. Blood flow to the kidneys appeared adequate on color flow assessment.

Adrenal Glands

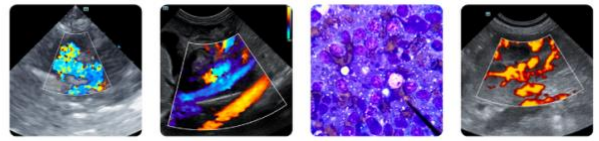
Both **adrenal glands** were visualized and recognized as having normal shape, size, position and echogenicity for this breed. The phrenic vasculature, glandular echogenicity and detail were unremarkable. Capsule, cortex, and medullary definition were normal for this age patient. The left adrenal gland measured 1.27 cm x 0.51 cm width at the cranial pole and 0.49 cm width at the caudal pole. The right adrenal gland measured 1.8 cm x 0.85 cm width at the cranial pole and 0.61 cm width at the caudal pole.

Spleen

The **spleen** presented a smooth homogeneous parenchyma hyperechoic to liver and renal cortical parenchyma. The capsule was smooth without noticeable expansion or deviation from within the spleen or adjacent pathology. The splenic vasculature demonstrated normal volume without signs of congestion or thrombosis. No sonographic evidence of acute or chronic inflammatory, neoplastic, or infarctual changes were noted.

Liver

The **liver** images from right and left intercostal as well as subcostal views revealed subjectively normal liver size, contour, and structure. Some mild age-related parenchymal remodeling was noted but likely not clinically significant at this time. Vascular and biliary tracts were of normal volume and no evidence of congestion was noted. The gallbladder presented some dependent debris with essentially normal contour. The cystic and common bile ducts were normal. No overt evidence of active inflammatory, infiltrative or regenerative pathology was noted but should be paired with current or past LE elevations regarding any clinical significance to this presentation. The hepatic lymph nodes were unremarkable.



PATIENT

Bandit Prystowski

SPECIES

Canine

BREED

Jack Russell

SEX

Neutered Male

AGE

11 Years

WEIGHT

36 pounds

INTERPRETED BY

Eric Lindquist, DMV,
DABVP(CFM), Cert.
IVUSS

**IMAGING
PERFORMED BY**

Vincent Ravancho CVT

HOSPITAL NAME

All Creatures Great &
Small Fairfield

REFERRING VET

Dr. Perez

INVOICE

14281

DATE

03/12/26

Gastrointestinal

Examination of the **gastrointestinal tract** revealed a stomach and intestine free of stasis, of normal wall thickness, acceptable curvilinear mural detail, and peristaltic activity. Small and large intestine demonstrated normal luminal chyme and stool consistency respectively. No obstructive or overt infiltrative disease was noted. No associated abnormal lymphatic activity was noted.

Pancreas

The base and limbs of the **pancreas** were observed to be largely isoechoic to surrounding omental fat. Pancreatic duct and capsular contour were acceptably normal and parenchyma respected normal curvilinear patterns. No overt evidence of active inflammatory or neoplastic disease was noted.

Free Abdomen

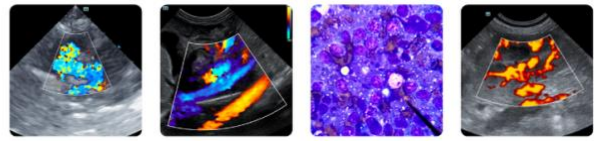
A large amount of abdominal fat was noted in this patient.

ULTRASONOGRAPHIC FINDINGS

- Structurally unremarkable abdomen.

INTERPRETATION OF THE FINDINGS & FURTHER RECOMMENDATIONS

No evidence of pathology. These are expected age-related changes for this age and breed.



PATIENT

Bandit Prystowski

SPECIES

Canine

BREED

Jack Russell

SEX

Neutered Male

AGE

11 Years

WEIGHT

36 pounds

INTERPRETED BY

Eric Lindquist, DMV,
 DABVP(CFM), Cert.
 IUUSS

IMAGING PERFORMED BY

Vincent Ravancho CVT

HOSPITAL NAME

All Creatures Great &
 Small Fairfield

REFERRING VET

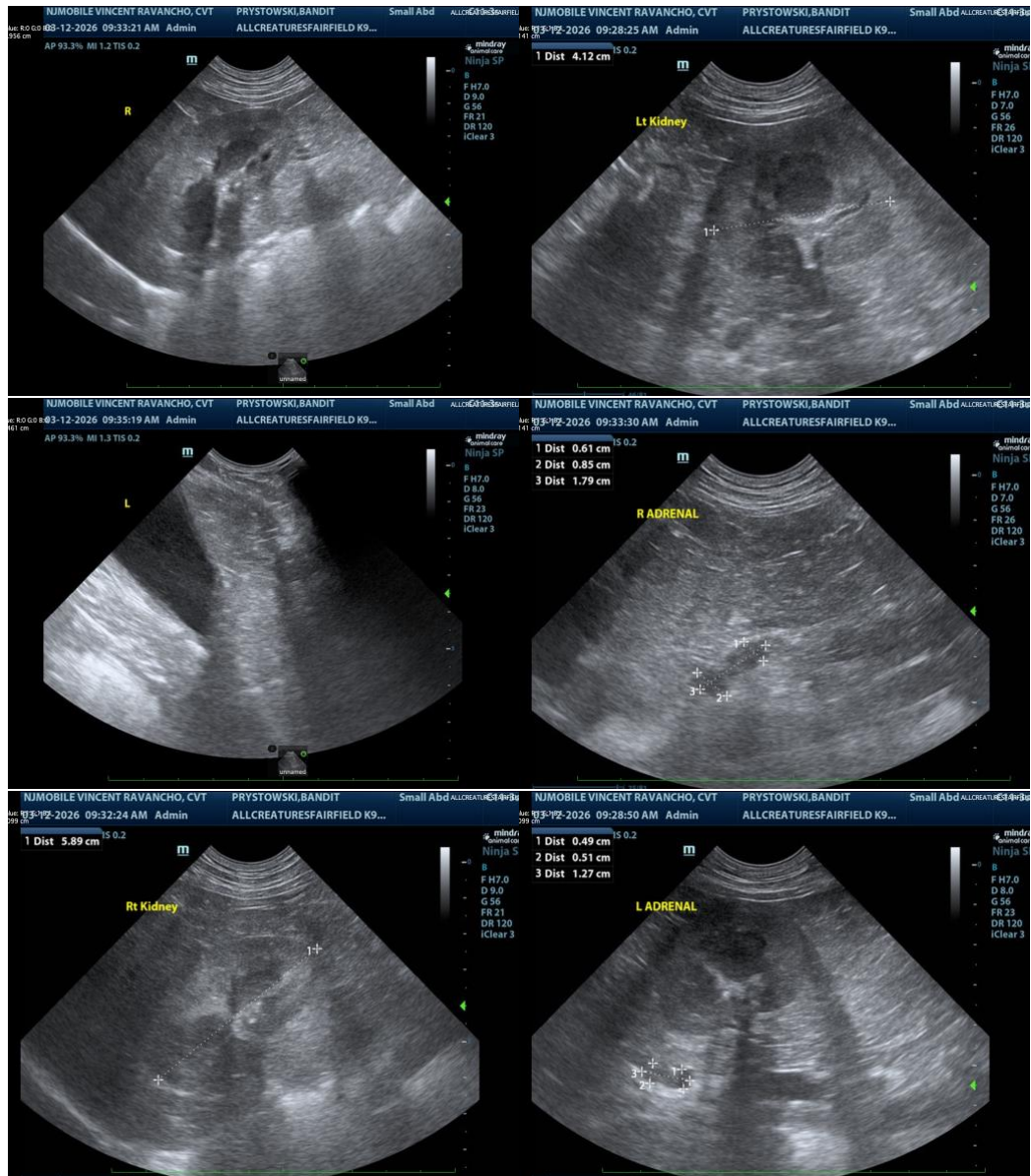
Dr. Perez

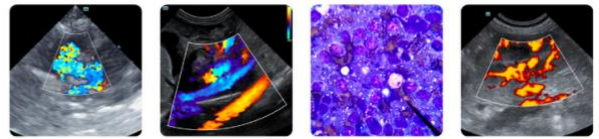
INVOICE

14281

DATE

03/12/26





PATIENT

Bandit Prystowski

SPECIES

Canine

BREED

Jack Russell

SEX

Neutered Male

AGE

11 Years

WEIGHT

36 pounds

INTERPRETED BY

Eric Lindquist, DMV,
 DABVP(CFM), Cert. IVUSS

IMAGING PERFORMED BY

Vincent Ravancho CVT

HOSPITAL NAME

All Creatures Great &
 Small Fairfield

REFERRING VET

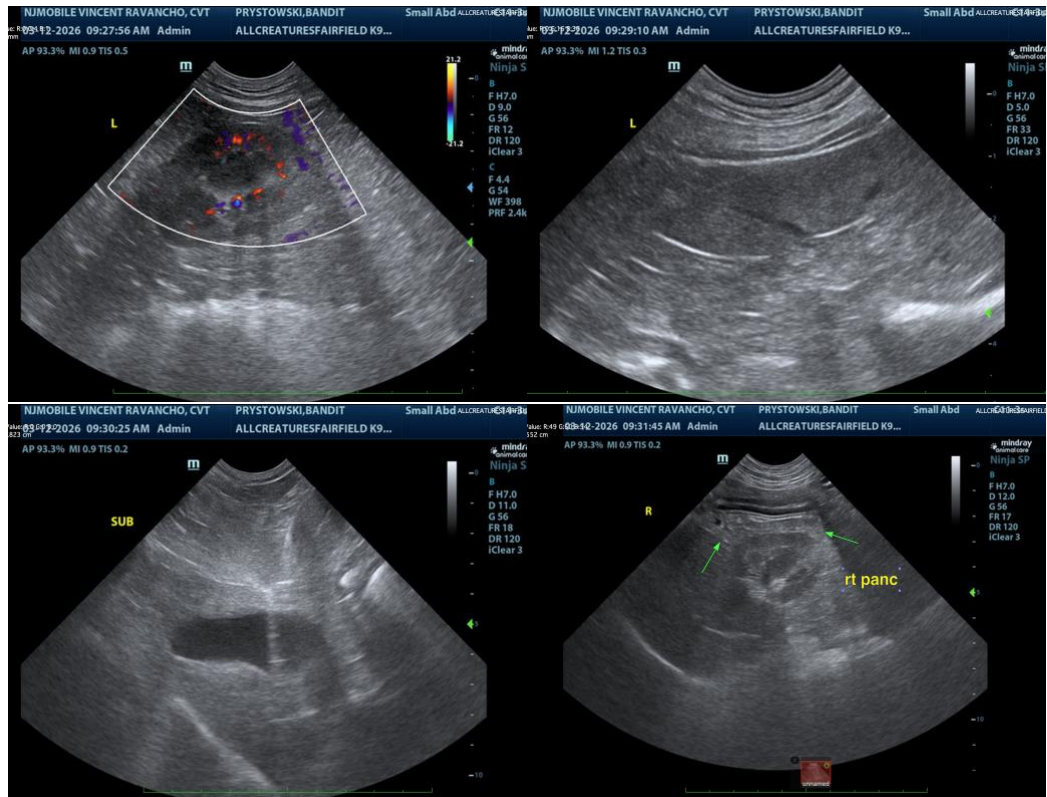
Dr. Perez

INVOICE

14281

DATE

03/12/26



The information and recommendations provided are based on the images presented by the referring veterinarian/sonographer. No evaluation can be communicated regarding pathology that was not visible in the image/video clips provided.

Thank you for this referral. If the clinical or image interpretation does not parallel your findings or if I can be of any further assistance, please contact me.

Eric Lindquist, DMV, DABVP(CFM), Cert. IVUSS,

CEO, Owner, Founder -- SonoPath.com

info@SonoPath.com