IMAGING PERFORMED BY

IntraPet.com

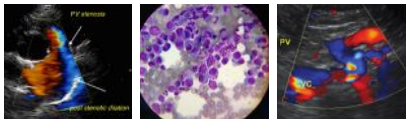

SonoPath
Clinical Sonography & Telecytology
EDUCATIONAL TELECONSULTATION SERVICES™
1-800-838-4268 info@sonopath.com SonoPath.com

DATE
3/11/22

PATIENT
Poe Laisure

SPECIES
Feline

BREED
DLH

SEX
Neutered Male

AGE
3/10/09

WEIGHT
14.1 Pounds

INTERPRETED BY
Eric Lindquist, DMV
DABVP, Cert. IVUSS

HOSPITAL NAME
Animal Emergency Hospital

REFERRING VET
Dr. Thompson

INVOICE
14295

PRESENTING CLINICAL SIGNS

History: Poe is a 13 y/o MN DLH who presents for lethargy - laying around more - O was gone for the weekend, was acting normally when first got home - yesterday morning found water and grass vomit - will occasionally vomit every once in a while his food or grass - appeared painful hind end was touched - laying around, O would pick up and would just lay back down - no interacting or as active as usually is - decreased drinking, no interested in eating for at least 24 hours - indoor/outdoor - Felv/fiv status unknown - no known FB or toxin exposure - no C, will sneeze often, no unusual for him - UTD vx, no hx medical conditions.

Current Medications: None, no preventatives. Unasyn, Cerenia and Gabapentin.
Lab Results: See attached.
Date of Previous IntraPet Ultrasound: No previous.
Sedation: Not required to complete full diagnostic ultrasound.
Stat Report: Not requested.
Imaging Performed By: Rachel Brilhart, RDMS.

ULTRASONOGRAPHIC EXAMINATION OF THE ABDOMEN

Urinary System

The **urinary bladder**, trigone, and pelvic urethra presented normal thicknesses and normal tone. The ureters were not visible which is normal. No uroliths or sediment were visualized and anechoic urine was present. No evidence of inflammatory or neoplastic changes were noted. Ureteral papillae were normal.

The **kidneys** revealed a mild interstitial nephrosis renal pattern. Pelvic mineralization noted in the left kidney (0.44 cm). The right kidney measured 4.86 cm. The left kidney measured 4.44 cm.

Adrenal Glands

Both **adrenal glands** were visualized and recognized as having normal shape, size, position and echogenicity for this breed. The phrenic vasculature, glandular echogenicity and detail were unremarkable. Capsule, cortex, and medullary definition were normal for this age patient. The left adrenal gland measured 0.44 cm. The right adrenal gland measured 0.44 cm.

Spleen

The **spleen** revealed slight irregular swelling and contour. Focal, hypoechoic nodule noted in the mid cranial spleen.

Liver

The **liver** images submitted revealed subjectively normal liver size, contour, and structure. Parenchymal echogenicity was naturally coarse and hypoechoic to the spleen. Vascular and biliary tracts were of normal volume with no evidence of congestion. The gallbladder presented acceptably thin walls with primarily anechoic content. The cystic and common bile ducts were normal. No pathological hepatic lymphadenopathy was evident. No overt structural evidence of inflammatory, infiltrative or regenerative pathology was evident. Comet tail lung pattern was noted through the diaphragm.

Gastrointestinal

Examination of the **gastrointestinal tract** revealed a stomach and intestine free of stasis, of normal wall thickness, acceptable curvilinear mural detail, and peristaltic activity. Small and large intestine

demonstrated normal luminal chyme and stool consistency respectively. No obstructive or overt infiltrative disease was noted. No associated abnormal lymphatic activity was noted.

Pancreas

The base and limbs of the **pancreas** were observed to be largely isoechoic to surrounding omental fat. Pancreatic duct and capsular contour were acceptably normal and parenchyma respected normal curvilinear patterns. No overt evidence of active inflammatory or neoplastic disease was noted.

ULTRASONOGRAPHIC FINDINGS

- Mild to moderate interstitial nephrosis renal pattern. Left renal pelvic calculus.
- Comet tail lung pattern
- Irregular spleen with hypoechoic nodule

INTERPRETATION OF THE FINDINGS & FURTHER RECOMMENDATIONS

Chest radiographs warranted to assess for thoracic disease. If any weight loss is an issue, FNA of the spleen indicated, however, this is likely a positional variant. If the palpation of the spleen reveals pain, then splenectomy indicated. Otherwise, the abdomen appears stable and unremarkable.

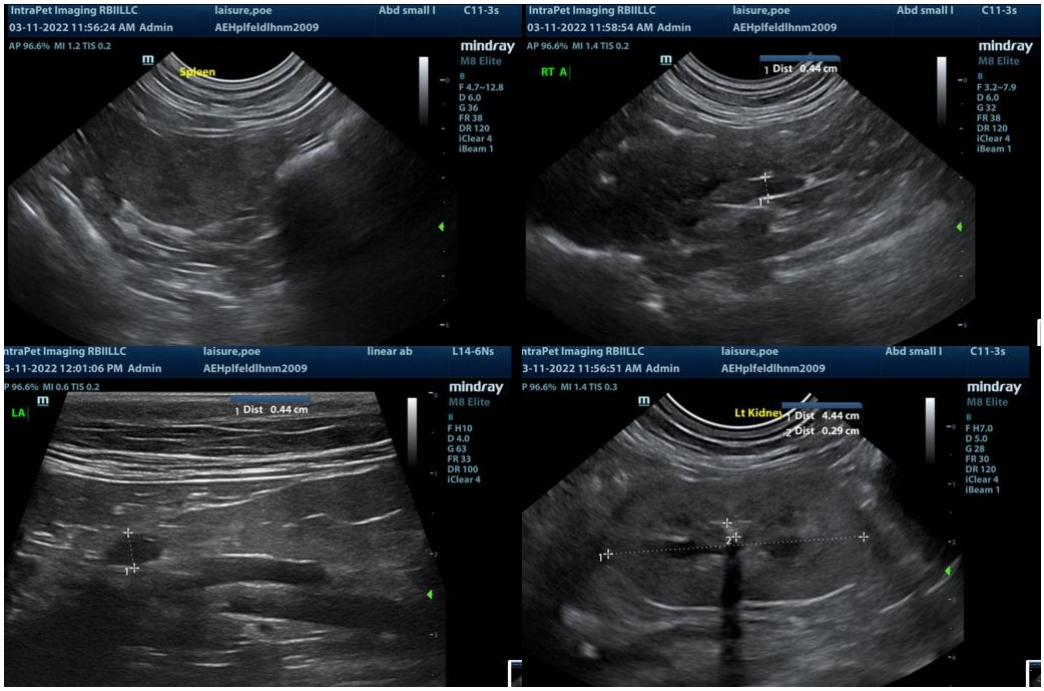

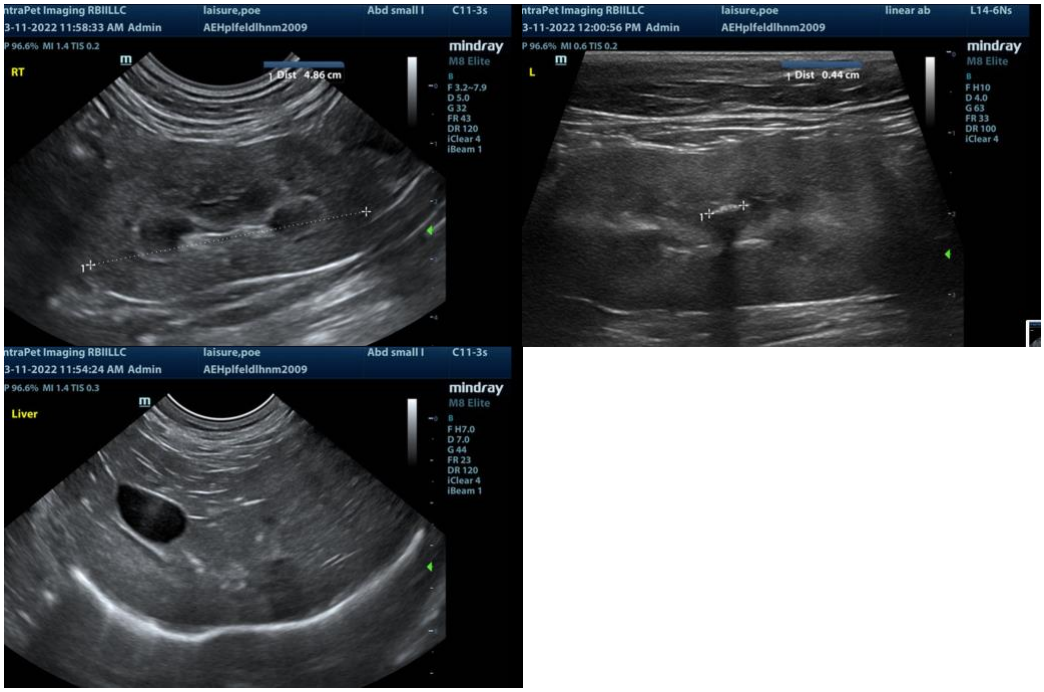

The information and recommendations provided are based on the images presented by the referring veterinarian. No evaluation can be communicated regarding pathology that was not visible in the image/video clips provided.

Thank you for this referral. If the clinical or image interpretation does not parallel your findings or if I can be of any further assistance please contact me.

Eric Lindquist, DMV, DABVP, Cert. IVUSS, CEO of SonoPath.com
Eric.Lindquist@SonoPath.com