

**DATE**

3/11/22

**PRESENTING CLINICAL SIGNS**

History: Presented to Mason Dixon ER- suspect cranial thoracic mass.

**PATIENT**

Kali Leitch

Current Medications: none listed.

Date of Previous IntraPet Ultrasound:

Sedation: Not required to complete full diagnostic ultrasound.

Stat Report: Not requested.

**SPECIES**

Canine

Imaging Performed By: Andi Parkinson, RDMS.

**BREED**

Labrador

**LIMITED ULTRASONOGRAPHIC EXAMINATION****SEX**

Spayed Female

Variable thoracic images revealed an approximately 8.0 cm x 5.0 cm, mixed echogenic and cystic mass, deviating the heart. The mass appears adhered to the epicardium and appears to be deriving from the cranial mediastinum. The heart itself revealed normal volume. No peripheral air entrapment noted which would suggest likely lymph node origin. No free fluid was noted, however, cavitated fluid was present within the mass.

**AGE**

5/2/10

**ULTRASONOGRAPHIC FINDINGS**

- Cranial mediastinal and thoracic mass enveloping the heart

**WEIGHT**

62.3 Pounds

**INTERPRETATION OF THE FINDINGS & FURTHER RECOMMENDATIONS**

Thymoma, lymphoma ad granulomatous disease all possible. Abdominal sonogram recommended to assess for primary disease that may be related. Ultrasound guided FNA or core biopsy of the parenchymal portion of the mass and drainage of the cystic portion with cytospin all indicated. Guarded prognosis dependent upon sampling results. CT evaluation for potential surgical planning, however, the mass envelopes the heart and likely be difficult to remove cleanly.

**INTERPRETED BY**

Eric Lindquist, DMV  
DABVP, Cert. IVUSS

**HOSPITAL NAME**

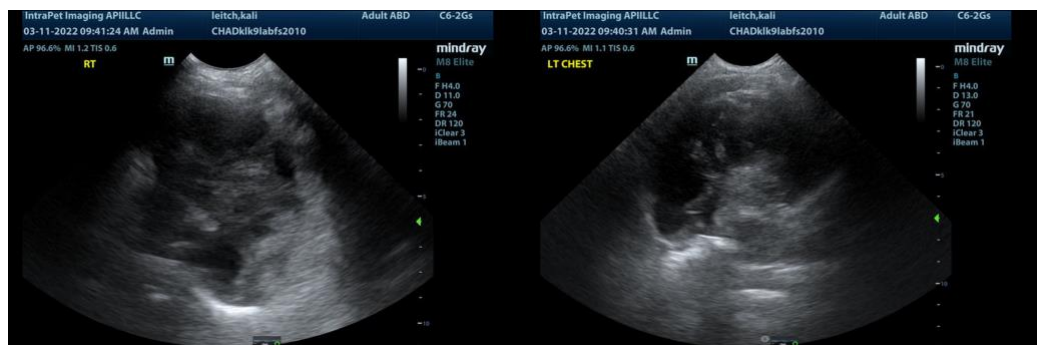
Chadwell AH

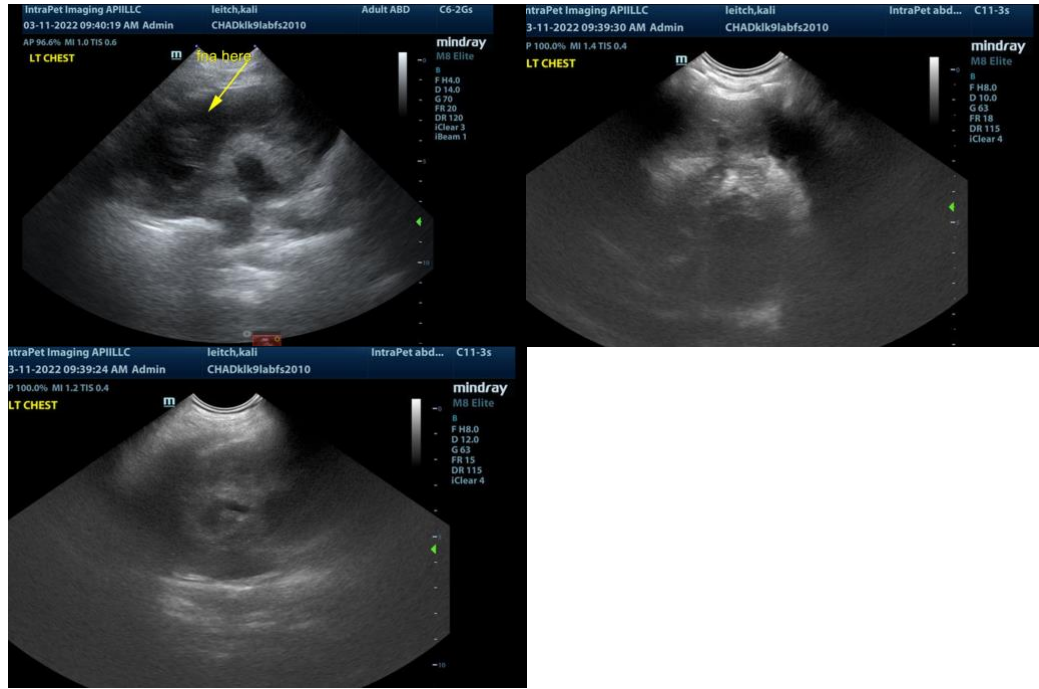
**REFERRING VET**

Dr. Gold

**INVOICE**

14289





**The information and recommendations provided are based on the images presented by the referring veterinarian. No evaluation can be communicated regarding pathology that was not visible in the image/video clips provided.**

Thank you for this referral. If the clinical or image interpretation does not parallel your findings or if I can be of any further assistance please contact me.

**Eric Lindquist**, DMV, DABVP, Cert. IVUSS, CEO of SonoPath.com  
Eric.Lindquist@SonoPath.com