

**PATIENT**

Twix Amanat

**SPECIES**

Feline

**BREED**

Persian

**SEX**

Neutered Male

**AGE**

14 Years 3 Months

**WEIGHT**

9.3 pounds

**INTERPRETED BY**

Eric Lindquist, DMV,  
DABVP(CFM), Cert.  
IVUSS

**IMAGING PERFORMED BY**

Kerri Becker

**HOSPITAL NAME**

Whippany Vet

**REFERRING VET**

Dr. Enoch

**INVOICE**

14209

**DATE**

03/10/26

**PRESENTING CLINICAL SIGNS**

- Recheck echo done Jan 2026
- BP 263/148 map 196 P did miss some med doses recently due to personal issues in family, faint murmur, underweight
- Telmisartan SQF 2x wk for CKD

Abnormal PE/Chem/CBC/UA Results: bun=38 creat=2.7 bnp=438

**ULTRASONOGRAPHIC EXAMINATION OF THE HEART**

FELINE CARDIAC PARAMETERS	BODY WEIGHT (lbs)	HR (BPM)	IVSd (cm)	LVIDd (cm)	LVWd (cm)	FS (%)	EF (%)
NORMAL PARAMETER	-----	150-240	0.3-0.6	1.0-2.1	0.25-0.6	35-67	80-100
PATIENT	9.3	206	0.48	1.45	0.48	49	84
FELINE CARDIAC PARAMETERS	LA/AO (M-mode)	LA/AO HEART BASE (Sisson)	LAD LA MAX 4 Chamber		LVOT VEL. (m/s)	RVOT VEL. (m/s)	IVRT (m/)
NORMAL PARAMETER	<1.5	1.6	0.7-1.7		<1.6	<1.3	40-60
PATIENT	1.4	1.3	--		1.2	0.6	NM

Adapted from June Boon, Veterinary Echocardiography, 1998  
Sisson D et al. JVIM 1991; 5: 232, Jacobs et al. Am J Vet Res 1985; 46:1705

EPSS: 01// E-wave Velocity: 0.9

**Cardiac Presentation**

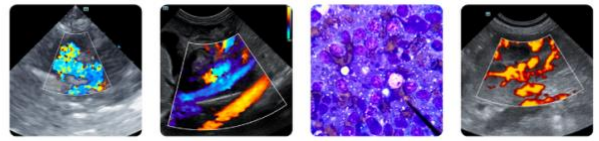
The cardiac presentation revealed normal volumes in the left atrium and right ventricle. Myocardial remodeling was noted, similar to the prior sonogram. Contractility was adequate. No pericardial or pleural effusion was evident. The left and right ventricular outflow velocities were unremarkable. A minor amount of turbulence was noted at the left ventricular outflow tract yet this is not clinically significant.

**ULTRASONOGRAPHIC FINDINGS**

- Trivial LVOT turbulence with myocardial remodeling.
- Stable heart.

**INTERPRETATION OF THE FINDINGS & FURTHER RECOMMENDATIONS**

No evidence of pathology. No therapy is recommended other than controlling the systemic hypertension.



**PATIENT**

Twix Amanat

**SPECIES**

Feline

**BREED**

Persian

**SEX**

Neutered Male

**AGE**

14 Years 3 Months

**WEIGHT**

9.3 pounds

**INTERPRETED BY**

Eric Lindquist, DMV,  
 DABVP(CFM), Cert.  
 IVUSS

**IMAGING PERFORMED BY**

Kerri Becker

**HOSPITAL NAME**

Whippany Vet

**REFERRING VET**

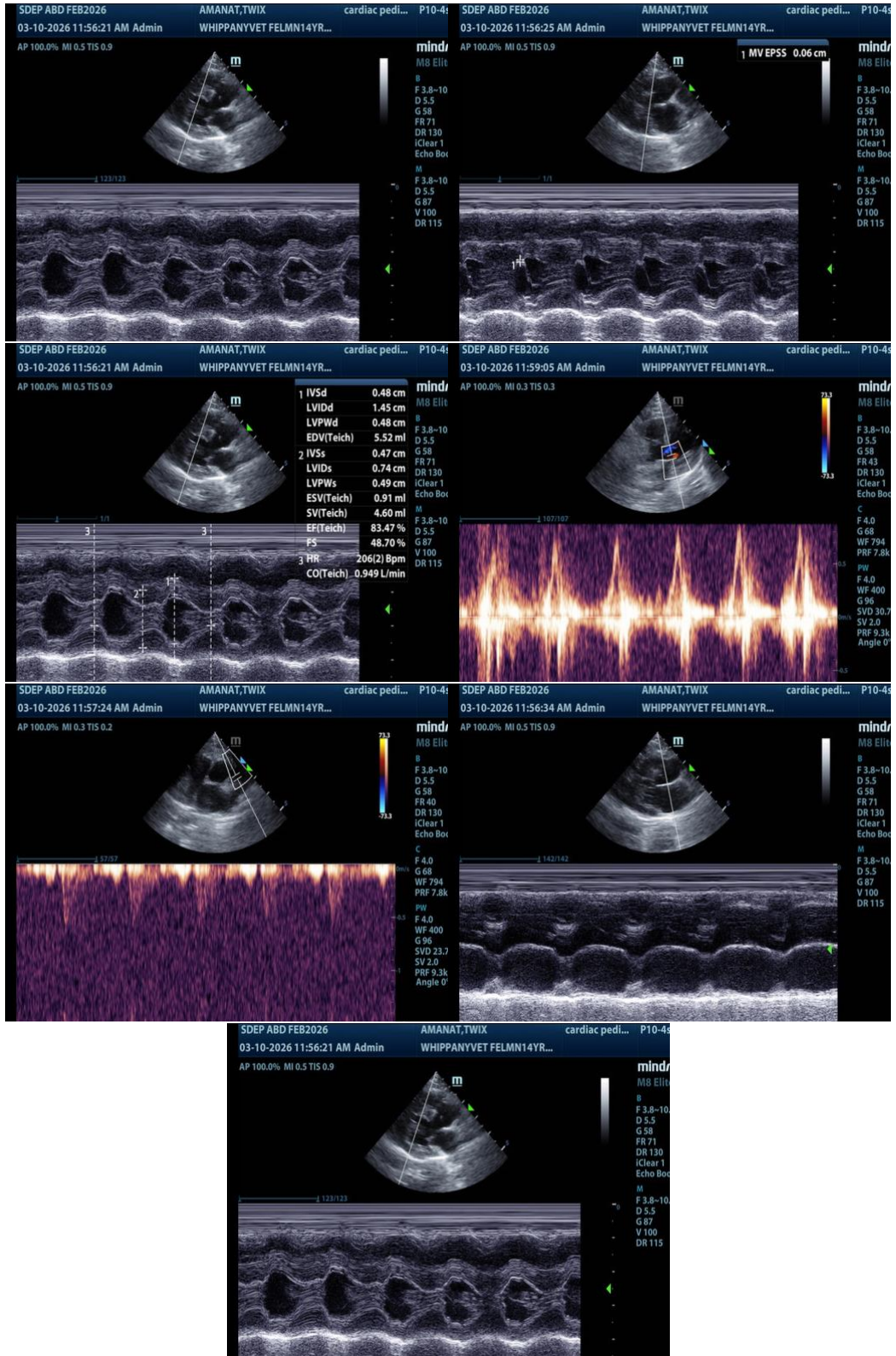
Dr. Enoch

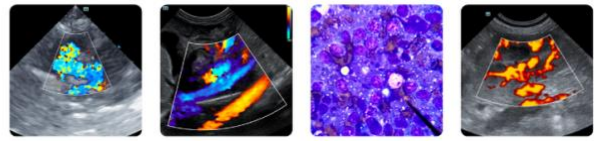
**INVOICE**

14209

**DATE**

03/10/26





**PATIENT**

Twix Amanat

The information and recommendations provided are based on the images presented by the referring veterinarian/sonographer. No evaluation can be communicated regarding pathology that was not visible in the image/video clips provided.

**SPECIES**

Feline

Thank you for this referral. If the clinical or image interpretation does not parallel your findings or if I can be of any further assistance, please contact me.

**BREED**

Persian

**Eric Lindquist, DMV, DABVP(CFM), Cert. IVUSS,**

CEO, Owner, Founder -- SonoPath.com

[info@SonoPath.com](mailto:info@SonoPath.com)

**SEX**

Neutered Male

**AGE**

14 Years 3 Months

**WEIGHT**

9.3 pounds

**INTERPRETED BY**

Eric Lindquist, DMV,  
DABVP(CFM), Cert.  
IVUSS

**IMAGING PERFORMED BY**

Kerri Becker

**HOSPITAL NAME**

Whippany Vet

**REFERRING VET**

Dr. Enoch

**INVOICE**

14209

**DATE**

03/10/26