



## PATIENT

Twinkle Dworakowska

## SPECIES

Canine

## BREED

Chihuahua

## SEX

Spayed Female

## AGE

18

## WEIGHT

8.1 Pounds

## INTERPRETED BY

Eric Lindquist, DMV,  
DABVP (CFM), Cert.  
IVUSS

## IMAGING PERFORMED BY

Seth Edgar, DVM

## HOSPITAL NAME

Overpeck Creek AH

## REFERRING VET

Seth Edgar, DVM

## INVOICE

36167

## DATE

3/10/26

## PRESENTING CLINICAL SIGNS

Recheck limited study for the liver, gall bladder, and adrenal glands. Some quick scans in the region of the pancreas Last study was 12/18/25.

### Current Meds:

- Lasix 12.5mg @ 3/4 tab q12
- Vetmedin 2.5 @ 1/2 tab q12
- Tussigon 5mg/ml @ 1.25ml q6 PRN
- Enalapril 2.5 @1 tab q24
- Ursodiol 50mg: 1/2 tab po bid
- Trazodone 50mg: Give 1/4-1/2 tablet as needed for anxiety

Most recent lab work from 2/15/26 showed: HCT 40.1(L), PLT 602 (H), Glu 129 (H), SDMA 20 (H), ALP 2270 (H)(approx 50% decrease), Cholesterol 438 (H), Lipase 258 (H), USG 1.019, tT4 0.8 (L). T4 panel to cornell pending.

## ULTRASONOGRAPHIC EXAMINATION OF THE ABDOMEN

### Urinary System

The visible portion of the **left kidney** was unremarkable, measuring approximately 3.5 cm.

The **right kidney** revealed moderate age-related changes with nonobstructive nephrolithiasis. A 4.0 mm cyst was noted at the caudal pole of the right kidney.

### Adrenal Glands

The **left adrenal gland** was slightly swollen and mildly irregular. The left adrenal gland measured 0.77 cm at the caudal pole and 0.65 cm at the cranial pole.

The **right adrenal gland** was nodular. The right adrenal gland measured 2.1 cm x 1.08 cm at the caudal pole and 0.91 cm at the cranial pole.

### Liver

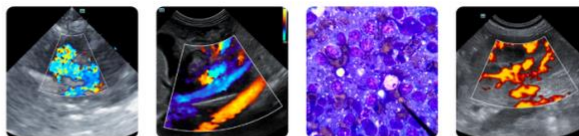
The **liver** was mildly irregular with slight coarse architecture. The hepatic parenchyma presented increased portal markings. An anechoic cyst (1.7 cm) was noted in the left lateral lobe, appears to be stable. Minor excessive gallbladder debris and overdistention, however, mucocele criteria is not present. Minor polypoid changes were noted in the gallbladder.

### Gastrointestinal

The upper **gastrointestinal tract** was unremarkable, curvilinear patterns were maintained. The colon was unremarkable.

### Pancreas

The visible **pancreas** was unremarkable.



## PATIENT

Twinkle Dworakowska

## SPECIES

Canine

## BREED

Chihuahua

## SEX

Spayed Female

## AGE

18

## WEIGHT

8.1 Pounds

## INTERPRETED BY

Eric Lindquist, DMV,  
DABVP (CFM), Cert.  
IVUSS

## IMAGING PERFORMED BY

Seth Edgar, DVM

## HOSPITAL NAME

Overpeck Creek AH

## REFERRING VET

Seth Edgar, DVM

## INVOICE

36167

## DATE

3/10/26

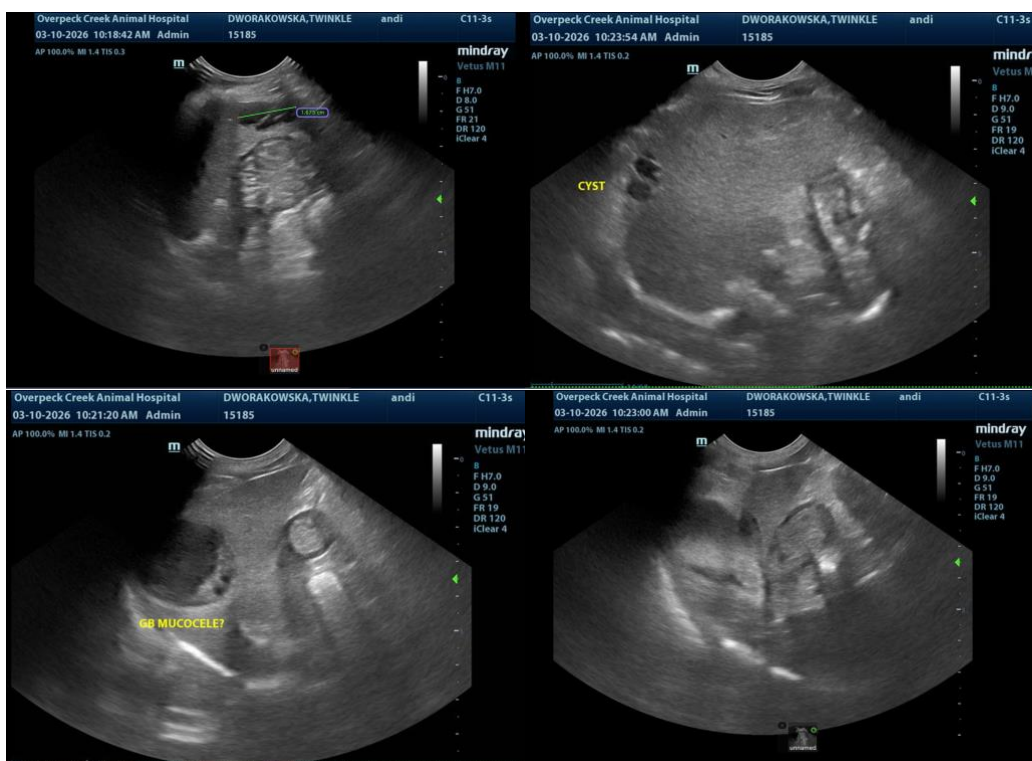
## ULTRASONOGRAPHIC FINDINGS

- Emerging gallbladder mucocele
- Hepatic cyst and benign hepatopathy
- Nodular irregular adrenal glands- hyperplasia is likely, no evidence of vascular invasion
- Age-related right renal changes

## INTERPRETATION OF THE FINDINGS & FURTHER RECOMMENDATIONS

Note, the left adrenal gland is largely similar to the prior sonogram. The adrenal glands are stable with nodular hyperplasia pattern. Clinical significance would be based on any systemic hypertension or appearance of cushings disease. Recommend continuing ursodiol therapy over the next 6-8 weeks and recheck sonogram at that time.

\*\*No other organs were visualized on the images provided.





## PATIENT

Twinkle Dworakowska

## SPECIES

Canine

## BREED

Chihuahua

## SEX

Spayed Female

## AGE

18

## WEIGHT

8.1 Pounds

## INTERPRETED BY

Eric Lindquist, DMV,  
DABVP (CFM), Cert.  
IVUSS

## IMAGING PERFORMED BY

Seth Edgar, DVM

## HOSPITAL NAME

Overpeck Creek AH

## REFERRING VET

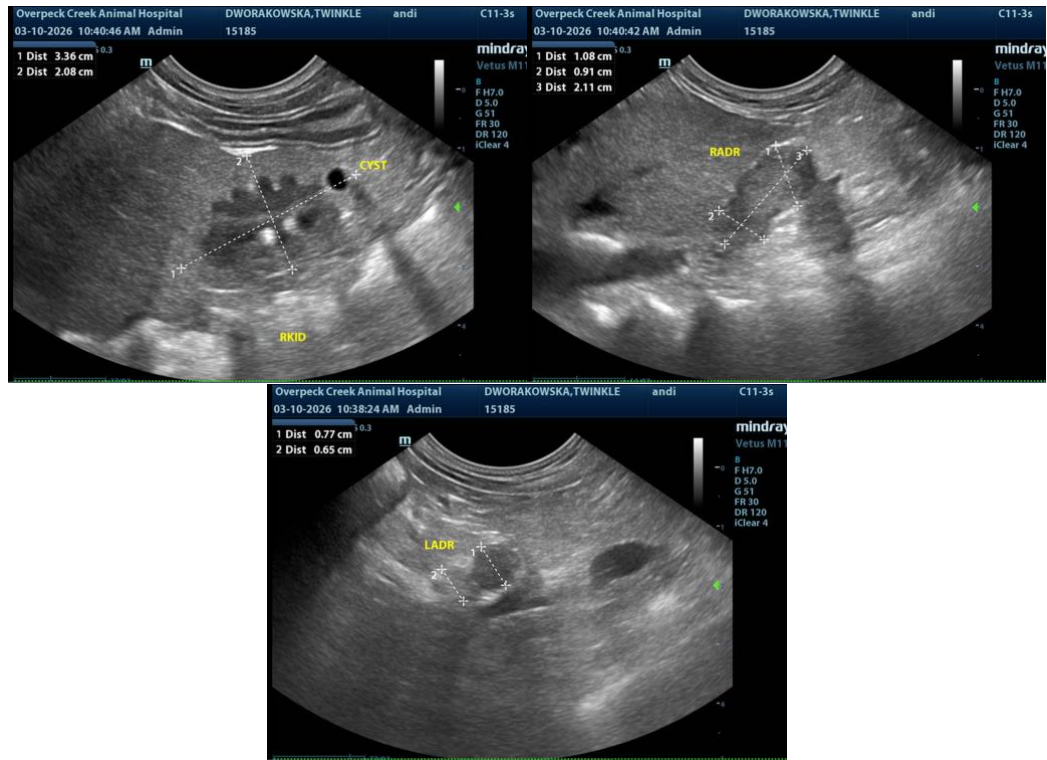
Seth Edgar, DVM

## INVOICE

36167

## DATE

3/10/26



The information and recommendations provided are based on the images presented by the referring veterinarian/sonographer. No evaluation can be communicated regarding pathology that was not visible in the image/video clips provided.

Thank you for this referral. If the clinical or image interpretation does not parallel your findings or if I can be of any further assistance please contact me.

Eric Lindquist, DMV, DABVP(CFM), Cert. IVUSS,  
CEO, Owner, Founder -- SonoPath.com  
[info@SonoPath.com](mailto:info@SonoPath.com)