



PATIENT

Lulu Brits

SPECIES

Canine

BREED

Chihuahua

SEX

Female

AGE

10 years

WEIGHT

5.7 lbs

INTERPRETED BY

Eric Lindquist, DMV
DABVP, Cert. IVUSS

IMAGING PERFORMED BY

Dr. Samad Khan

HOSPITAL NAME

The Veterinary Surgery

REFERRING VET

Dr. Khan

INVOICE

73367

DATE

3/10/26

PRESENTING CLINICAL SIGNS

- Breathing difficulty. Radiology report attached. Cough

ULTRASONOGRAPHIC EXAMINATION OF THE HEART

The echocardiogram in this patient demonstrated normal left sided volumes and normal contractility. There was minor mitral valve prolapse noted with slight vegetative thickening of the mitral valve. If a murmur is present it is likely deriving from the mitral valve. However, this should be confirmed on color flow and spectral Doppler. The right atrium was unremarkable. Minor right ventricular eccentric hypertrophy was noted with pulmonary artery dilation. This is consistent with cor pulmonale. No pleural or pericardial effusion was noted. There were no overt masses noted in the acoustic window provided.

CANINE CARDIAC PARAMETERS	MR VMAX (m/s)	TR VMAX (m/s)	LA/AO	LA/AO (Heart Base)	FS (%)	EF (%)	EPSS (cm)
NORMAL PARAMETER	4.5-5.5	<2.7	1.3	<1.6	28-40	40-100	<0.6
PATIENT	NM	NM	1.0	1.0	45	NM	0.1
CANINE CARDIAC PARAMETERS	HR (BPM)	AV VMAX (m/s)	PV MAX (m/s)	BODY WEIGHT (kg)	LA 2D short axis Base view (cm)	LVIDd Avg; 2D and m-mode short axis (cm)	LVIDs Avg; 2D and m-mode short axis (cm)
NORMAL PARAMETER	50-100	0.7-1.7	0.7-1.6	BELOW	BELOW	BELOW	BELOW
PATIENT	80	NM	NM	5.7 lbs	NM	2.2	

ULTRASONOGRAPHIC FINDINGS

Thickened mitral valve and cor pulmonale.

Otherwise, structurally unremarkable abdomen.

INTERPRETATION OF THE FINDINGS & FURTHER RECOMMENDATIONS

Likely stage B1 valvular disease if murmur is present, yet this should be confirmed on color flow Doppler. No specific cardiac medications are recommended.



PATIENT

Lulu Brits

SPECIES

Canine

BREED

Chihuahua

SEX

Female

AGE

10 years

WEIGHT

5.7 lbs

INTERPRETED BY

Eric Lindquist, DMV
DABVP, Cert. IVUSS

**IMAGING
PERFORMED BY**

Dr. Samad Khan

HOSPITAL NAME

The Veterinary Surgery

REFERRING VET

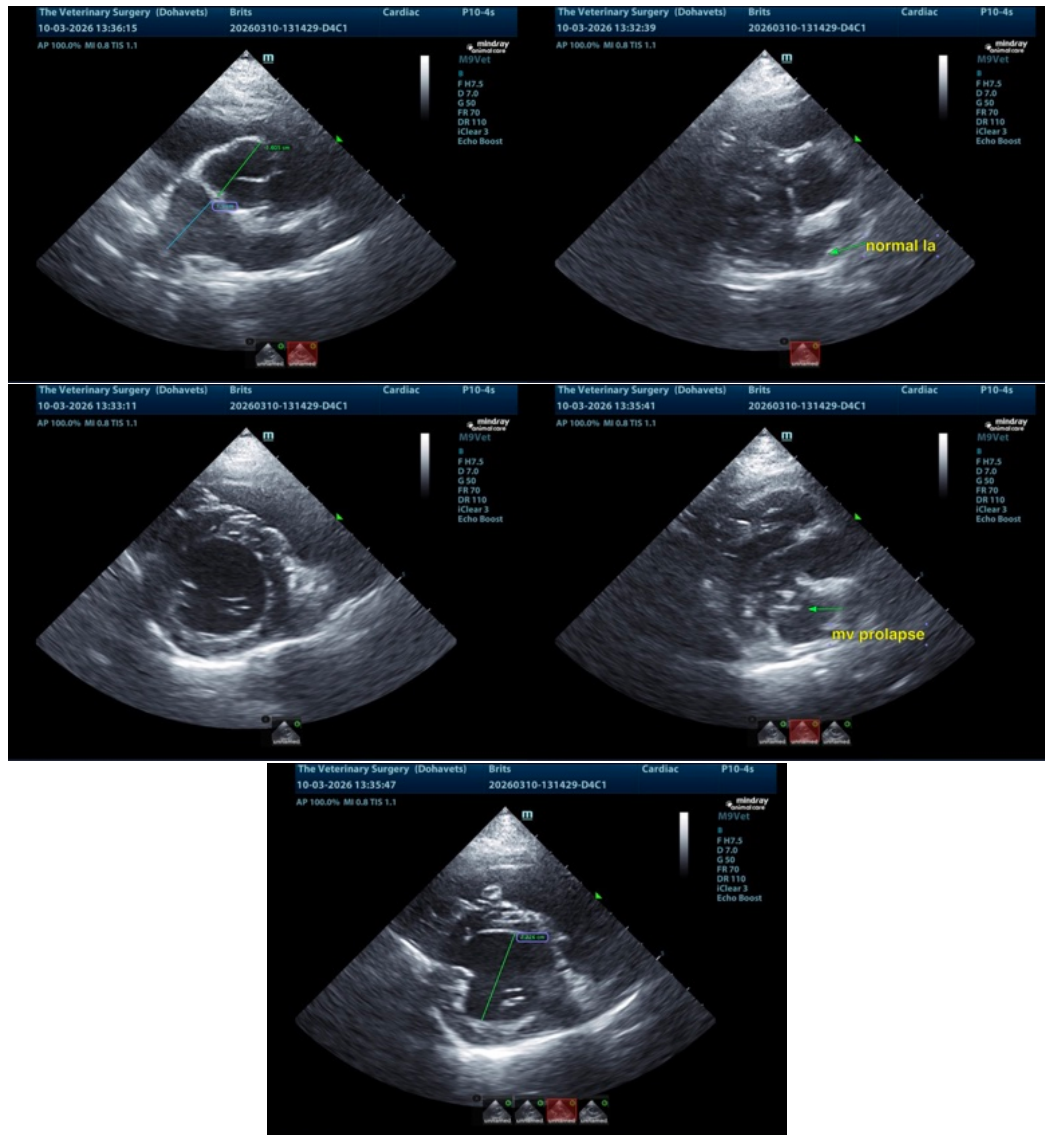
Dr. Khan

INVOICE

73367

DATE

3/10/26



The information and recommendations provided are based on the images presented by the referring veterinarian/sonographer. No evaluation can be communicated regarding pathology that was not visible in the image/video clips provided.

Thank you for this referral. If the clinical or image interpretation does not parallel your findings or if I can be of any further assistance please contact me.

Eric Lindquist, DMV, DABVP (CFM), Cert. IVUSS, CEO of SonoPath.com

info@SonoPath.com