



PATIENT

Bingo Lopresti

SPECIES

Canine

BREED

Australian Shepherd
mix

SEX

Neutered male

AGE

9 years

WEIGHT

45 lbs

INTERPRETED BY

Eric Lindquist, DMV
DABVP, Cert. IVUSS

IMAGING PERFORMED BY

Dr. Wolfe

HOSPITAL NAME

HomeVets

REFERRING VET

Dr. Wolfe

INVOICE

72363

DATE

3/10/26

PRESENTING CLINICAL SIGNS

- P had an ALT elevation that resolved, but US still pursued for senior screening purposes.
- Dec 2025 ALT = 148 Feb 2026 ALT = 64 remainder of BW wnl

ULTRASONOGRAPHIC EXAMINATION OF THE ABDOMEN

Urinary System

The **urinary bladder**, trigone, and pelvic urethra presented normal thicknesses and normal tone. The ureters were not visible which is normal. No uroliths or sediment were visualized and anechoic urine was present. No evidence of inflammatory or neoplastic changes was noted. Ureteral papillae were normal.

The **kidneys** revealed normal size and structure, corticomedullary definition and ratio for this age. The cortices presented largely uniform texture with normal echogenic relationship to liver and spleen. Medullary structure differed distinctly from the cortex and no evidence of pelvic dilation was present. The capsules were acceptably uniform without significant irregularities. The left kidney measured 5.7 cm.

Adrenal Glands

Both **adrenal glands** were visualized and recognized as having normal shape, size, position and echogenicity for this breed. The phrenic vasculature, glandular echogenicity and detail were unremarkable. Capsule, cortex, and medullary definition were normal for this age patient. The left adrenal gland measured 0.4 cm at the caudal pole and 0.35 cm at the cranial pole. The right adrenal gland measured 1.0 cm at the cranial pole and 0.65 cm at the caudal pole.

Spleen

The **spleen** was mildly enlarged and uniform.

Liver

The **liver** was slightly subnormal in size. The gallbladder presented acceptably thin walls with primarily anechoic content. The cystic and common bile ducts were normal. No pathological hepatic lymphadenopathy was evident. No overt structural evidence of inflammatory, infiltrative or regenerative pathology was evident.

Gastrointestinal

Examination of the **gastrointestinal tract** revealed a stomach and intestine free of stasis, of normal wall thickness, acceptable curvilinear mural detail, and peristaltic activity. Small and large intestine demonstrated normal luminal chyme and stool consistency respectively. No obstructive or overt infiltrative disease was noted. No associated abnormal lymphatic activity was noted.



PATIENT

Bingo Lopresti

SPECIES

Canine

BREED

Australian Shephard
mix

SEX

Neutered male

AGE

9 years

WEIGHT

45 lbs

INTERPRETED BY

Eric Lindquist, DMV
DABVP, Cert. IVUSS

Pancreas

The base and limbs of the **pancreas** were observed to be largely isoechoic to surrounding omental fat. Pancreatic duct and capsular contour were acceptably normal and parenchyma respected normal curvilinear patterns. No overt evidence of active inflammatory or neoplastic disease was noted.

ULTRASONOGRAPHIC FINDINGS

Structurally unremarkable abdomen.

Non-specific liver enzyme elevations, likely reactive hepatopathy.

INTERPRETATION OF THE FINDINGS & FURTHER RECOMMENDATIONS

The hepatic clinical sonographic presentation is most consistent with Reactive Hepatopathy which is the most common cause of liver enzyme elevation in dogs and cats. The presumption is that gut and other organ antigen stimuli may be causing a low-grade immune response through portal system with which the liver is reacting to causing low-grade enzyme elevations. US-guided FNA could be performed to assess if low grade lymphoplasmacytic inflammation is present that would support this theory. If FNA is performed, please ask the cytologist to emphasize the primary inflammatory cell type. Empirical treatment measures to address this issue can include diet change to hydrolyzed diet, probiotics, deworming, nutraceuticals (SAME, Actigall...), dental exam and cleaning, and potentially antibiotics such as Clavamox. Metronidazole and Tylosin have traditionally been utilized for this purpose but new studies show that both these antibiotics can disrupt the normal intestinal bacterial flora (intestinal dysbiosis) for weeks and up to 4-6 months. Therefore, Metronidazole and Tylosin should be utilized as a last resort if other efforts have not been effective and sonographic organ appearance remains benign.

IMAGING PERFORMED BY

Dr. Wolfe

HOSPITAL NAME

HomeVets

REFERRING VET

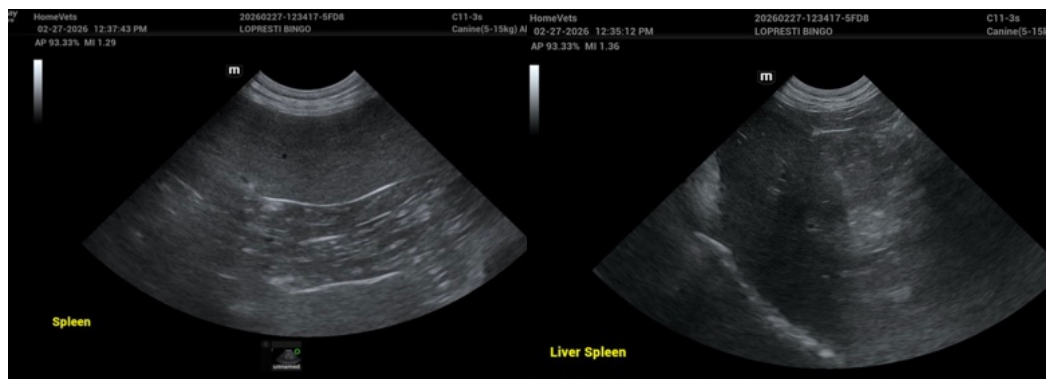Dr. Wolfe

INVOICE

72363

DATE

3/10/26





PATIENT

Bingo Lopresti

SPECIES

Canine

BREED

Australian Shephard
mix

SEX

Neutered male

AGE

9 years

WEIGHT

45 lbs

INTERPRETED BY

Eric Lindquist, DMV
DABVP, Cert. IVUSS

**IMAGING
PERFORMED BY**

Dr. Wolfe

HOSPITAL NAME

HomeVets

REFERRING VET

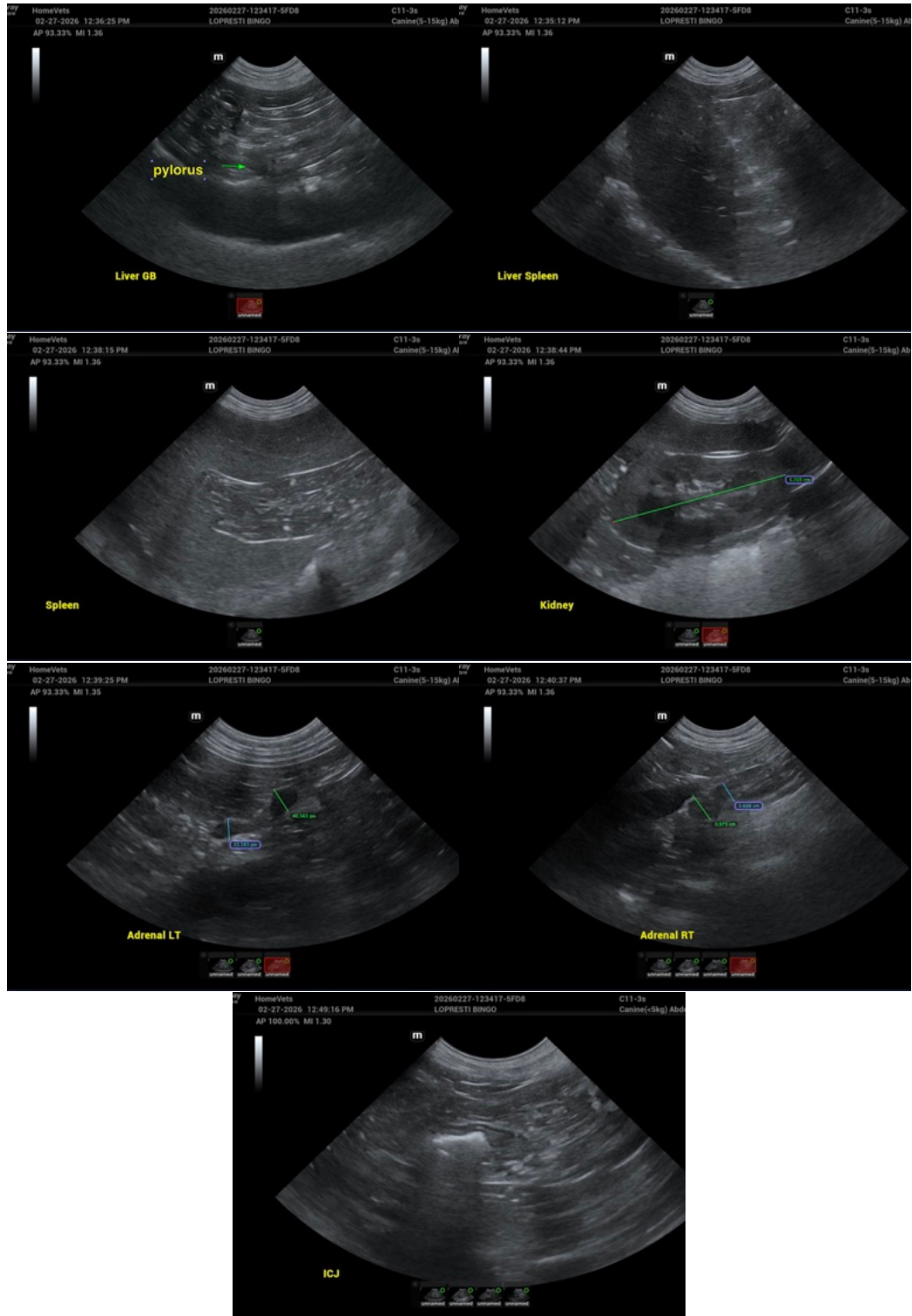
Dr. Wolfe

INVOICE

72363

DATE

3/10/26





PATIENT

Bingo Lopresti

SPECIES

Canine

BREED

Australian Shephard
mix

SEX

Neutered male

AGE

9 years

WEIGHT

45 lbs

INTERPRETED BY

Eric Lindquist, DMV
DABVP, Cert. IVUSS

IMAGING PERFORMED BY

Dr. Wolfe

HOSPITAL NAME

HomeVets

REFERRING VET

Dr. Wolfe

INVOICE

72363

DATE

3/10/26

The information and recommendations provided are based on the images presented by the referring veterinarian/sonographer. No evaluation can be communicated regarding pathology that was not visible in the image/video clips provided.

Thank you for this referral. If the clinical or image interpretation does not parallel your findings or if I can be of any further assistance please contact me.

Eric Lindquist, DMV, DABVP (CFM), Cert. IVUSS, CEO of SonoPath.com

info@SonoPath.com