



PATIENT

Knolland Grinvalds

SPECIES

Feline

BREED

DSH

SEX

Neutered Male

AGE

11 Years

WEIGHT

9.7 Pounds

PRESENTING CLINICAL SIGNS

History: On annual bw pro BNP 1,353, thyroid normal

Abnormal PE/Chem/CBC/UA Results: SG: 1.050

ULTRASONOGRAPHIC EXAMINATION OF THE HEART

FELINE CARDIAC PARAMETERS	BODY WEIGHT (kg)	HR (BPM)	IVSd (cm)	LVIDd (cm)	LWVd (cm)	FS (%)	EF (%)
NORMAL PARAMETER	-----	150-240	0.3-0.6	1.0-2.1	0.25-0.6	35-67	80-100
PATIENT	--	NM	0.33	2.08	0.34	21	44
FELINE CARDIAC PARAMETERS	LA/AO (Boon)	LA/AO HEART BASE (Sisson)	LA 2D 4-chamber long axis AS to FW (Sisson) (cm)	LVOT VEL. (m/s)	RVOT VEL. (m/s)	IVRT (m/)	
NORMAL PARAMETER	<1.5	0.88-1.79	0.7-1.7	<1.6	<1.3	40-60	
PATIENT	>2.0	3.08	2.5	--	.62	NM	
Adapted from June Boon, Veterinary Echocardiography, 1998							
Sisson D et al. JVIM 1991; 5: 232, Jacobs et al. Am J Vet Res 1985; 46:1705							

INTERPRETED BY

Eric Lindquist, DMV
DABVP, Cert. IVUSS

IMAGING PERFORMED BY

Val Shumskaya

HOSPITAL NAME

The Gentle Vet

REFERRING VET

Dr. Dulude

INVOICE

21546

DATE

3/10/23

Cardiac Presentation

The cardiac presentation in this patient presented significant volume overload of the left atrium and left ventricle with hypocontractility. Right atrial enlargement was also noted. Mitral and tricuspid insufficiency were present. The ventricular septum appeared to be adequately contracted, yet the free wall was stiff.

ULTRASONOGRAPHIC FINDINGS

- Unclassified cardiomyopathy with volume overload

INTERPRETATION OF THE FINDINGS & FURTHER RECOMMENDATIONS

Myocarditis may be playing a role in this patient. Infectious agents should be investigated. Recommend Pimobendan 0.3 mg/kg BID, Ace-inhibitor 0.5 mg/kg SID, Lasix 6.25 mg BID and recheck echo in 2 weeks. Plavix therapy can be justified. This patient is at the verge of full left sided heart failure.



PATIENT

Knolland Grinvalds

SPECIES

Feline

BREED

DSH

SEX

Neutered Male

AGE

11 Years

WEIGHT

9.7 Pounds

INTERPRETED BY

Eric Lindquist, DMV
DABVP, Cert. IVUSS

IMAGING PERFORMED BY

Val Shumskaya

HOSPITAL NAME

The Gentle Vet

REFERRING VET

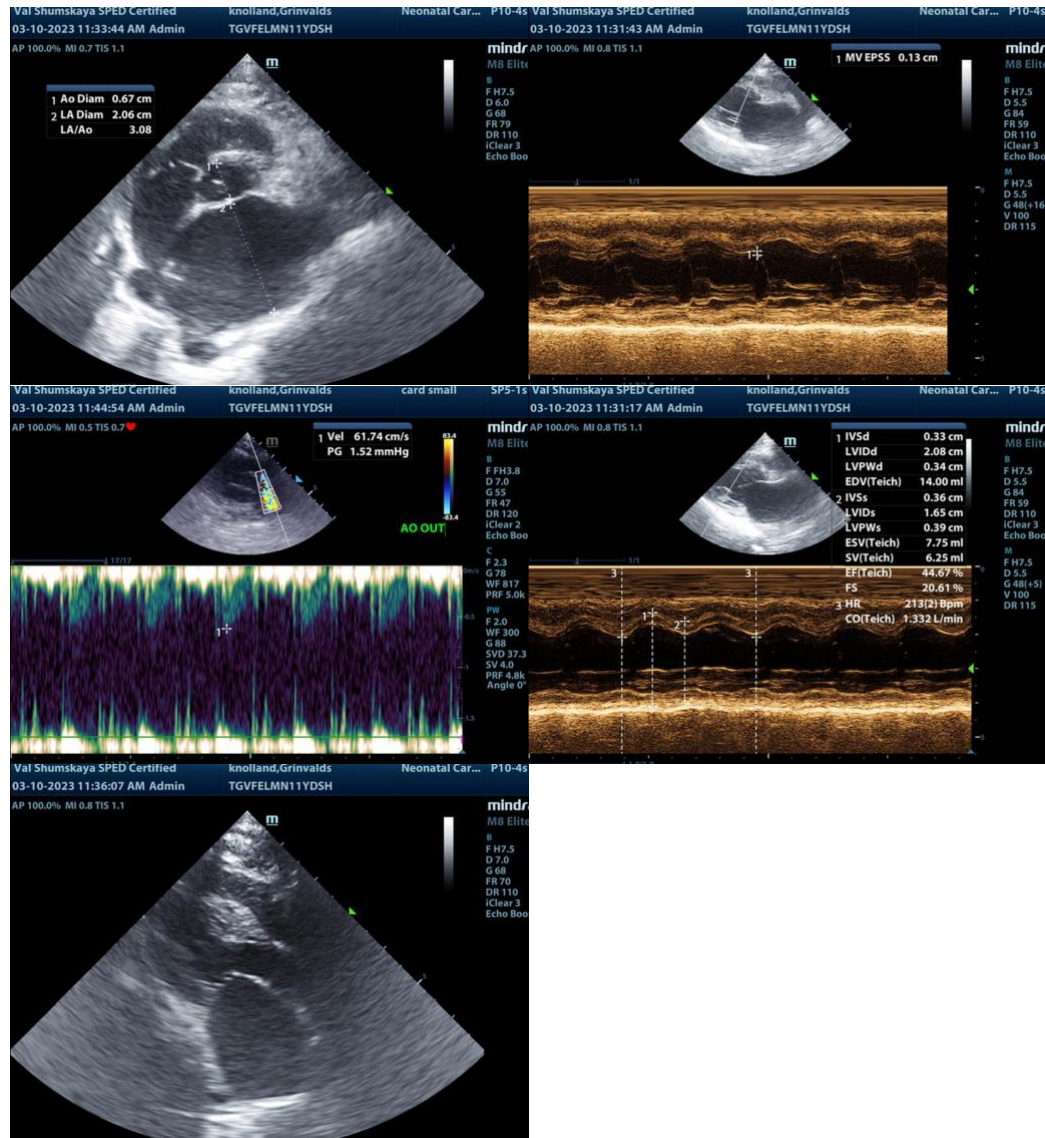
Dr. Dulude

INVOICE

21546

DATE

3/10/23



The information and recommendations provided are based on the images presented by the referring veterinarian. No evaluation can be communicated regarding pathology that was not visible in the image/video clips provided.

Thank you for this referral. If the clinical or image interpretation does not parallel your findings or if I can be of any further assistance please contact me.

Eric Lindquist, DMV, DABVP, Cert. IVUSS, CEO of SonoPath.com
info@SonoPath.com