



## PATIENT

Duke Ghani

## SPECIES

Canine

## BREED

Boxer

## SEX

Neutered Male

## AGE

8 Years

## WEIGHT

65 Pounds

## INTERPRETED BY

Eric Lindquist, DMV  
DABVP, Cert. IVUSS

## IMAGING PERFORMED BY

Meredith Swart

## HOSPITAL NAME

Swart Veterinary  
Imaging

## REFERRING VET

Meredith Swart

## INVOICE

21552

## DATE

3/10/23

## PRESENTING CLINICAL SIGNS

History: New patient to rDVM. No real medical history. No murmur ausculted but owner reports low grade cough so echo is to r/o heart given breed. Patient very reactive and fearful so was sedated with butorphanol and hub of ace.

Abnormal PE/Chem/CBC/UA Results: WNL

## ULTRASONOGRAPHIC EXAMINATION OF THE HEART

CANINE CARDIAC PARAMETERS	MR VMAX (m/s)	TR VMAX (m/s)	LA/AO (Boon method)	LA/AO (Heart Base; Swe)	FS (%)	EF (%)	EPSS (cm)
NORMAL PARAMETER	4.5-5.5	<2.7	1.3	<1.3	28-40	40-100	<0.6
PATIENT	--	--	1.25	1.7	20%	--	0.59
CANINE CARDIAC PARAMETERS	HR (BPM)	AV VMAX (m/s)	PV MAX (m/s)	BODY WEIGHT (kg)	LA 2D short axis Base view (cm)	LVIDd Avg; 2D and m-mode short axis (cm)	LVIDs Avg; 2D and m-mode short axis (cm)
NORMAL PARAMETER	50-100	0.7-1.7	0.7-1.6				
PATIENT	--	--	.90	--	3.8	3.75	--

## Cardiac Presentation

The echocardiogram in this patient demonstrated normal **left atrial** size based on 3 separate methods of LA evaluation. Trivial mitral insufficiency was noted on color flow assessment. The **left ventricle** presented normal left ventricular internal diameter. The **myocardium** presented normal echogenicity without subjective evidence of significant fibrotic or ischemic disease. **Contractility** was mildly subnormal. This may be owing to arrhythmia, systemic disease, hypothyroidism, Addisons or other causes, however structurally and functionally the heart appeared unremarkable. The **right atrium** and auricle revealed normal size, structure and content. No evidence of masses was noted. **Tricuspid** valvular assessment demonstrated adequate linear morphology and kinesis. The **right ventricle** was of normal size (1/3 diameter of LV), chordae structure, myocardial echogenicity and thickness. **Pulmonary outflow** tract assessment revealed normal valve structure, laminar flow, and diameter (approx.1:1 pa/ao ratio). No visible **pericardial** or free pleura fluid was noted. The cranial **mediastinum and pericardial and extra-cardiac regions** were free of masses in the visible window. Periodic arrhythmia was noted in this patient- EKG is warranted.

## ULTRASONOGRAPHIC FINDINGS

- Contractility was mildly subnormal. This may be owing to arrhythmia, systemic disease, hypothyroidism, Addisons or other causes, however structurally and functionally the heart appeared unremarkable.



**PATIENT**

Duke Ghani

- Trivial mitral insufficiency
- Periodic arrhythmia- EKG is warranted

**SPECIES**

Canine

**BREED**

Boxer

**SEX**

Neutered Male

**AGE**

8 Years

**WEIGHT**

65 Pounds

**INTERPRETED BY**

Eric Lindquist, DMV  
DABVP, Cert. IVUSS

**IMAGING PERFORMED BY**

Meredith Swart

**HOSPITAL NAME**

Swart Veterinary  
Imaging

**REFERRING VET**

Meredith Swart

**INVOICE**

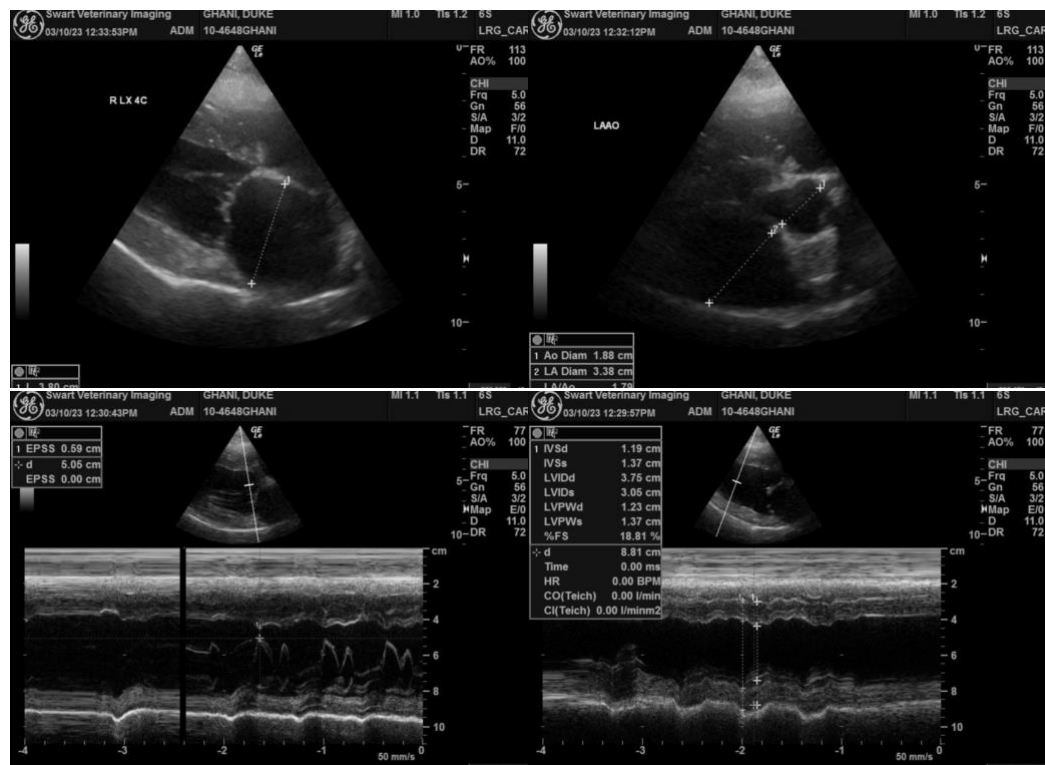
21552

**DATE**

3/10/23

**INTERPRETATION OF THE FINDINGS & FURTHER RECOMMENDATIONS**

The cough is noncardiogenic in this patient. I recommend Holter monitor given the breed predisposition to arrhythmogenic disease and arrhythmia noted. Thyroid assessment and baseline cortisol would be indicated to rule out concurrent Addisons disease. Systemic disease evaluation is warranted to assess the underlying cause of hypocontractility. No treatment at this time. Recheck echo in 6 months or earlier if clinically indicated.





**PATIENT**

Duke Ghani

**SPECIES**

Canine

**BREED**

Boxer

**SEX**

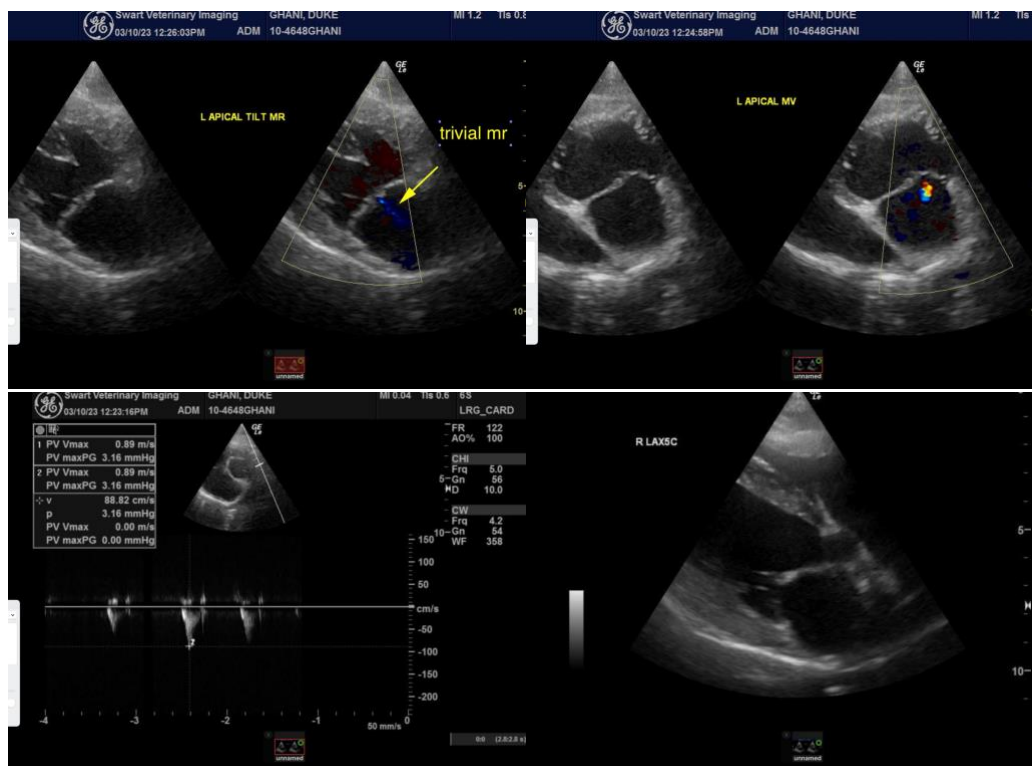
Neutered Male

**AGE**

8 Years

**WEIGHT**

65 Pounds



**INTERPRETED BY**

Eric Lindquist, DMV  
DABVP, Cert. IVUSS

**IMAGING PERFORMED BY**

Meredith Swart

**HOSPITAL NAME**

Swart Veterinary  
Imaging

**REFERRING VET**

Meredith Swart

**INVOICE**

21552

**DATE**

3/10/23

The information and recommendations provided are based on the images presented by the referring veterinarian. No evaluation can be communicated regarding pathology that was not visible in the image/video clips provided.

Thank you for this referral. If the clinical or image interpretation does not parallel your findings or if I can be of any further assistance please contact me.

**Eric Lindquist**, DMV, DABVP, Cert. IVUSS, CEO of SonoPath.com  
info@SonoPath.com