



PATIENT PRESENTING CLINICAL SIGNS

Argon Uccello

History: re check from yesterday, showed minor retention of ingesta even though patient was fasted, checking to make sure stomach is empty

SPECIES

Canine

ULTRASONOGRAPHIC EXAMINATION OF THE ABDOMEN

Gastrointestinal

BREED

Chihuahua Mix

The GI tract is empty without further retention of ingesta. No evidence of foreign bodies.

SEX

Neutered male

ULTRASONOGRAPHIC FINDINGS

Empty gastrointestinal tract.

AGE

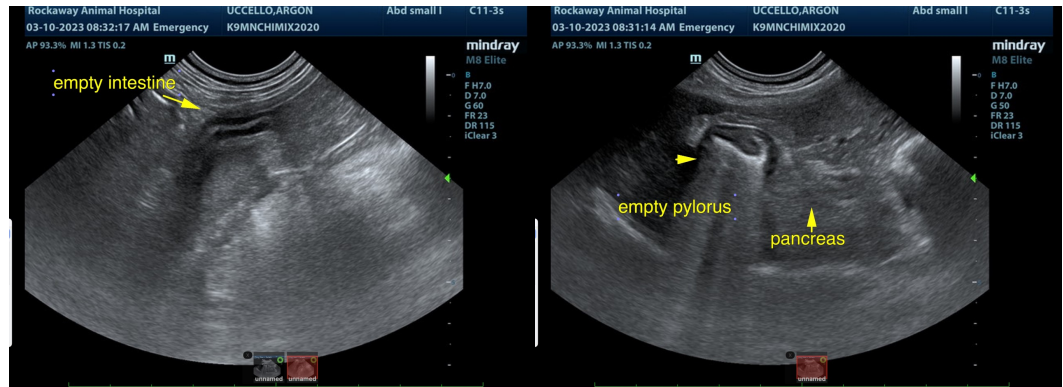
2 years

INTERPRETATION OF THE FINDINGS & FURTHER RECOMMENDATIONS

There is no evidence of foreign bodies.

WEIGHT

13 lbs



INTERPRETED BY

Eric Lindquist, DMV
DABVP, Cert. IVUSS

IMAGING PERFORMED BY

Jenn

HOSPITAL NAME

Rockaway AH

The information and recommendations provided are based on the images presented by the referring veterinarian/sonographer. No evaluation can be communicated regarding pathology that was not visible in the image/video clips provided.

REFERRING VET

Dr. Maniar

Thank you for this referral. If the clinical or image interpretation does not parallel your findings or if I can be of any further assistance please contact me.

Eric Lindquist, DMV, DABVP, Cert. IVUSS, CEO of SonoPath.com
info@SonoPath.com

INVOICE

43249

DATE

3/10/23