



PATIENT PRESENTING CLINICAL SIGNS

Scrappy Freeman

History: anorexia, vomiting, distended abdomen, elevated liver enzymes; AUS 2 years ago confirmed large liver- aspirates declined at the time. Meds: cerenia, famotidine, metronidazole, denamarin, B-vitamins.

SPECIES

Abnormal PE/Chem/CBC/UA Results: 3/8: ALT 538, ALKP 798, 3/9: ALT 328, ALKP 662

Canine

BREED

Rat Terrier

ULTRASONOGRAPHIC EXAMINATION OF THE ABDOMEN

Urinary System

The **urinary bladder**, trigone, and pelvic urethra presented normal thicknesses and normal tone. The pelvic urethra was imaged 3.0 cm beyond the cystourethral junction. The ureters were not visible which is normal. No uroliths or sediment were visualized and anechoic urine was present. No evidence of inflammatory or neoplastic changes was noted. Ureteral papillae were normal.

SEX

Neutered male

AGE

10 years

The **kidneys** revealed largely normal size and structure, corticomedullary definition and ratio (cortex 1/3 of medulla) were essentially maintained with some age-related loss of curvilinear patterns regarding the capsule and C/M junction. The cortices presented largely uniform texture with some increased echogenicity expected for this age patient. Medullary structure differed distinctly from that of the cortex and no evidence of pelvic dilation was present. The left kidney measured 6.12 cm. The right kidney measured 6.2 cm.

WEIGHT

28.7 lbs

Adrenal Glands

Both **adrenal glands** were visualized and recognized as having normal shape, size, position and echogenicity for this breed. The phrenic vasculature, glandular echogenicity and detail were unremarkable. Capsule, cortex, and medullary definition were normal for this age patient. The right adrenal gland measured 2.62 x 1.4 cm at the cranial pole and 0.74 cm at the caudal pole. The left adrenal gland measured 2.29 x 0.51 cm at the caudal pole and 0.69 cm at the cranial pole.

INTERPRETED BY

Eric Lindquist, DMV
DABVP, Cert. IVUSS

IMAGING PERFORMED BY

Diane McFadden, RVT

HOSPITAL NAME

Newton VH

Spleen

The **spleen** was mildly swollen and slightly congested likely owing to portal hypertension.

INVOICE

96726

Liver

The **liver** images submitted revealed subjectively normal liver size, contour, and structure. Parenchymal echogenicity was naturally coarse and hypoechoic to the spleen. Multi-focal nodular changes with increased portal markings. Vascular and biliary tracts were of normal volume with no evidence of congestion. The gallbladder and common bile duct were unremarkable.

DATE

3/10/22

Gastrointestinal

The **gastrointestinal tract** revealed diffuse, hyperechoic fogging or overlay throughout the small intestine as well as areas of mucosal striations and speckling. This striation + fogging effect appeared to exclusively affect the mucosal layer with the submucosa, muscularis and serosa left in-act. Reactive



PATIENT

Scrappy Freeman

mesentery was present associated with the serosa indicative of active inflammation. This is most consistent with protein losing enteropathy/lymphangectasia. Full thickness biopsies or endoscopic-guided biopsies would be ideal to confirm. No obstructive disease or obvious suspicion of neoplasia.

SPECIES

Canine

Pancreas

Heterogenous mesenteric changes were noted around the **pancreas**.

BREED

Rat Terrier

Free Abdomen

A large amount of echogenic ascites was noted. Enhanced mesentery was noted throughout the cranial abdomen.

SEX

Neutered male

ULTRASONOGRAPHIC FINDINGS

AGE

10 years

Hepatic cirrhosis pattern with secondary ascites owing to portal hypertension.

Diffuse liver disease.

Concurrent pancreatitis and gastroenteritis pattern.

WEIGHT

28.7 lbs

Mucosal fogging throughout the GI tract.

INTERPRETED BY

Eric Lindquist, DMV
DABVP, Cert. IVUSS

INTERPRETATION OF THE FINDINGS & FURTHER RECOMMENDATIONS

There is a mild potential for hepatic neoplasia. The prognosis is poor. Plasma transfusion, GI protectants and hepatic support are all indicated.

IMAGING

PERFORMED BY

Diane McFadden, RVT

HOSPITAL NAME

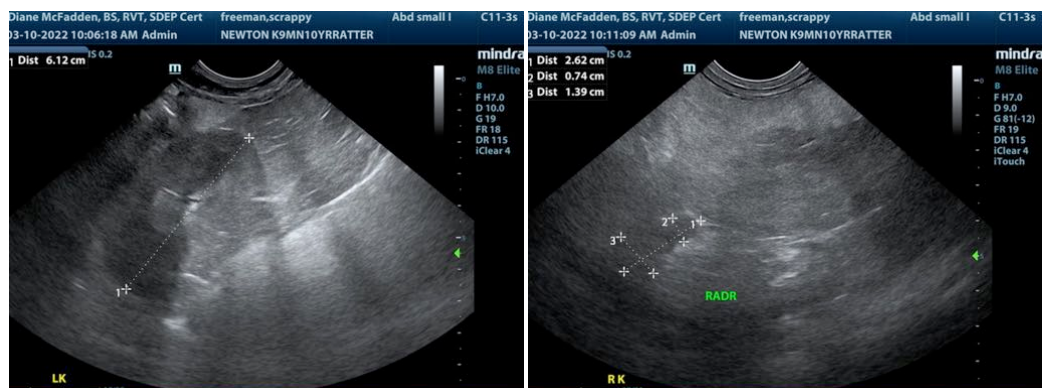
Newton VH

INVOICE

96726

DATE

3/10/22





PATIENT

Scrappy Freeman

SPECIES

Canine

BREED

Rat Terrier

SEX

Neutered male

AGE

10 years

WEIGHT

28.7 lbs

INTERPRETED BY

Eric Lindquist, DMV
DABVP, Cert. IVUS

IMAGING PERFORMED BY

Diane McFadden, RVT

HOSPITAL NAME

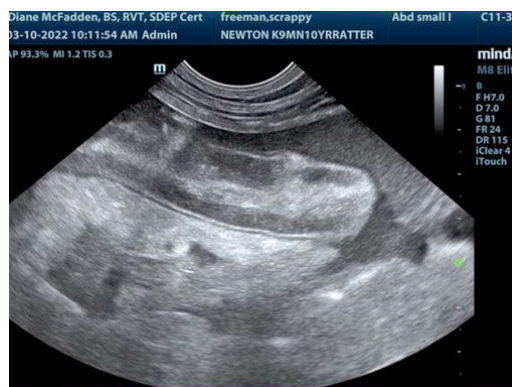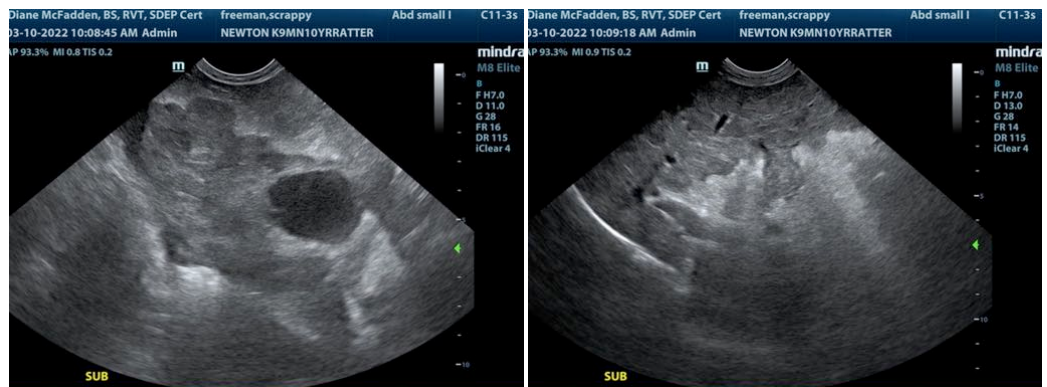
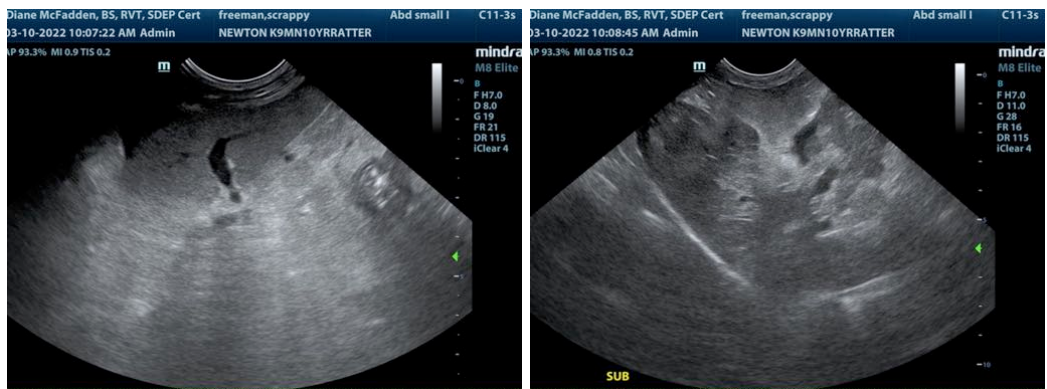
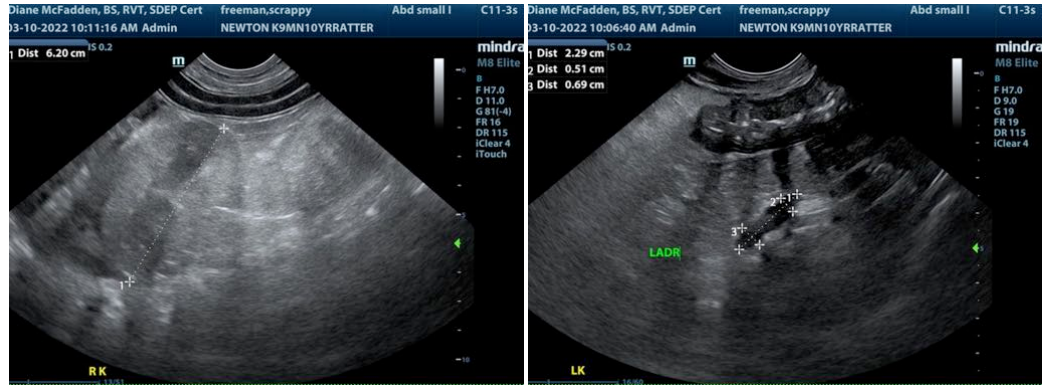
Newton VH

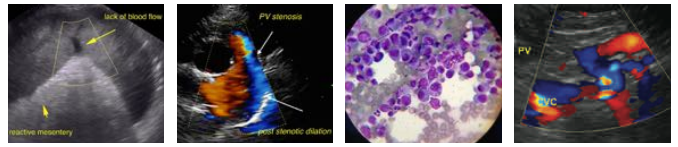
INVOICE

96726

DATE

3/10/22





PATIENT

Scrappy Freeman

The information and recommendations provided are based on the images presented by the referring veterinarian/sonographer. No evaluation can be communicated regarding pathology that was not visible in the image/video clips provided.

SPECIES

Canine

Thank you for this referral. If the clinical or image interpretation does not parallel your findings or if I can be of any further assistance please contact me.

BREED

Rat Terrier

Eric Lindquist, DMV, DABVP, Cert. IVUSS, CEO of SonoPath.com
Info@SonoPath.com

SEX

Neutered male

AGE

10 years

WEIGHT

28.7 lbs

INTERPRETED BY

Eric Lindquist, DMV
DABVP, Cert. IVUSS

**IMAGING
PERFORMED BY**

Diane McFadden, RVT

HOSPITAL NAME

Newton VH

INVOICE

96726

DATE

3/10/22