



PATIENT

Ellie Roberts

PRESENTING CLINICAL SIGNS

lethargic, increased drinking has not eaten for 2 days

SPECIES

Feline

ULTRASONOGRAPHIC EXAMINATION OF THE ABDOMEN

Urinary System

The **urinary bladder**, trigone, and pelvic urethra presented normal thicknesses and normal tone. The ureters were not visible which is normal. No uroliths or sediment were visualized and anechoic urine was present. No evidence of inflammatory or neoplastic changes were noted. Ureteral papillae were normal. The pelvic urethra was imaged 1.0 cm beyond the cystourethral junction.

BREED

DSH

SEX

Spayed Female

The right kidney was subnormal in size, measuring 2.77 cm. The left kidney measured 3.27 cm. The **kidneys** revealed largely normal structure, corticomedullary definition and ratio (cortex 1/3 of medulla) were essentially maintained with some age-related loss of curvilinear patterns regarding the capsule and C/M junction. The cortices presented largely uniform texture with some increased echogenicity expected for his age patient. Medullary structure differed distinctly from that of the cortex. Moderate pyelectasia noted on the left.

AGE

17 Years

Adrenal Glands

The regions of the **adrenal glands** were unremarkable.

WEIGHT

7 Pounds

Spleen

The **spleen** presented a smooth homogeneous parenchyma hyperechoic to liver and renal cortical parenchyma. The capsule was smooth without noticeable expansion or deviation from within the spleen or adjacent pathology. The splenic vasculature demonstrated normal volume without signs of congestion or thrombosis. No sonographic evidence of acute or chronic inflammatory, neoplastic, or infarctual changes were noted.

INTERPRETED BY

Eric Lindquist, DMV

DABVP, Cert. IVUSS

Liver

The **liver** was diffusely hyperechoic and mildly coarse in architecture compared to falciform fat. The gallbladder and common bile duct were unremarkable.

IMAGING PERFORMED BY

Jenn

Gastrointestinal

Examination of the **gastrointestinal tract** revealed a stomach and intestine free of stasis, of normal wall thickness, acceptable curvilinear mural detail, and peristaltic activity. Small and large intestine demonstrated normal luminal chyme and stool consistency respectively. No obstructive or overt infiltrative disease was noted. No associated abnormal lymphatic activity was noted.

HOSPITAL NAME

Rockaway AH

Pancreas

The base and limbs of the **pancreas** were observed to be largely isoechoic to surrounding omental fat. Pancreatic duct and capsular contour were acceptably normal and parenchyma respected normal curvilinear patterns. No overt evidence of active inflammatory or neoplastic disease was noted.

REFERRING VET

Dr. Maniar

INVOICE

36052

ULTRASONOGRAPHIC FINDINGS

- Geriatric abdomen with mild hepatic remodeling

DATE

3/10/22



PATIENT

Ellie Roberts

INTERPRETATION OF THE FINDINGS & FURTHER RECOMMENDATIONS

The cause of anorexia is unclear. Other causes such as orthopedic pain, thoracic and CNS disease should be considered.

SPECIES

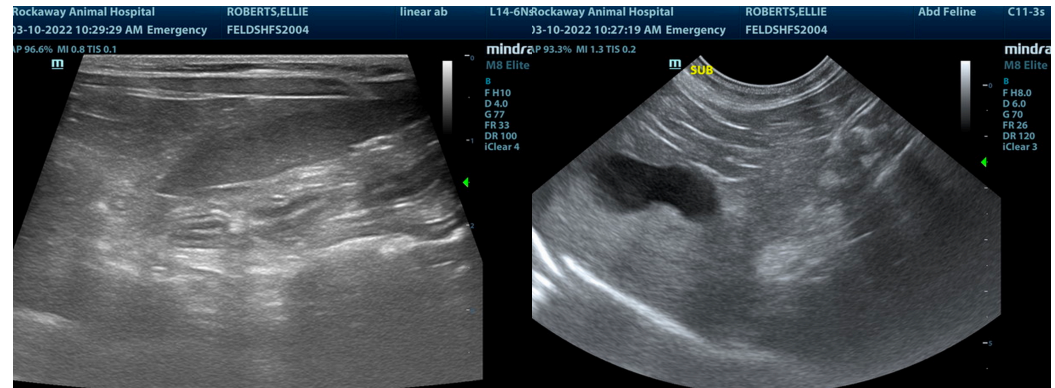
Feline

BREED

DSH

SEX

Spayed Female

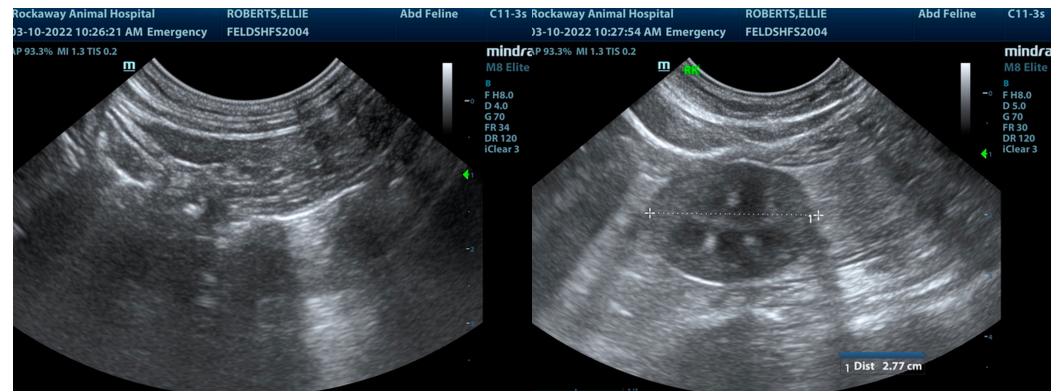


AGE

17 Years

WEIGHT

7 Pounds



INTERPRETED BY

Eric Lindquist, DMV

DABVP, Cert. IVUSS

IMAGING PERFORMED BY

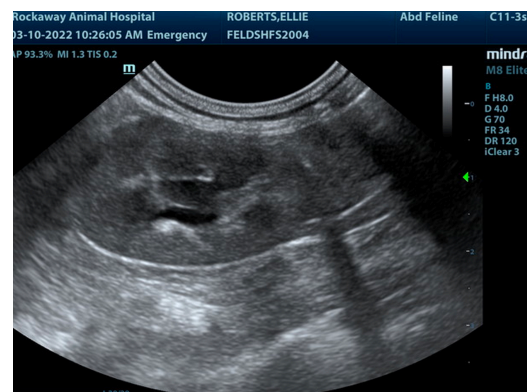Jenn

HOSPITAL NAME

Rockaway AH

REFERRING VET

Dr. Maniar



The information and recommendations provided are based on the images presented by the referring veterinarian/sonographer. No evaluation can be communicated regarding pathology that was not visible in the image/video clips provided.

INVOICE

36052

Thank you for this referral. If the clinical or image interpretation does not parallel your findings or if I can be of any further assistance please contact me.

Eric Lindquist, DMV, DABVP, Cert. IVUSS, CEO of SonoPath.com

DATE

3/10/22

info@SonoPath.com