



**PATIENT**

Charlie Miller

**PRESENTING CLINICAL SIGNS**

History: Hx of seizures (no meds), elevated liver values, no other symptoms. No current meds.  
 Abnormal PE/Chem/CBC/UA Results: ALT 507, ALKP 160

**SPECIES**

Canine

**ULTRASONOGRAPHIC EXAMINATION OF THE ABDOMEN**

**Urinary System**

**BREED**

Mix

The **urinary bladder**, trigone, and pelvic urethra presented normal thicknesses and normal tone. The ureters were not visible which is normal. No uroliths or sediment were visualized and anechoic urine was present. No evidence of inflammatory or neoplastic changes was noted. Ureteral papillae were normal.

**SEX**

Neutered male

The residual prostate was uniform and measured 0.78 cm. The iliac trifurcation was unremarkable.

**AGE**

14 years

The **kidneys** revealed largely normal size and structure, corticomedullary definition and ratio (cortex 1/3 of medulla) were essentially maintained with some age-related loss of curvilinear patterns regarding the capsule and C/M junction. The cortices presented largely uniform texture with some increased echogenicity expected for this age patient. Medullary structure differed distinctly from that of the cortex and no evidence of pelvic dilation was present. The right kidney measured 4.71 cm. The left kidney measured 4.42 cm.

**WEIGHT**

14 lbs

**Adrenal Glands**

Both **adrenal glands** were visualized and recognized as having normal shape, size, position and echogenicity for this breed. The phrenic vasculature, glandular echogenicity and detail were unremarkable. Capsule, cortex, and medullary definition were normal for this age patient. The right adrenal gland measured 1.29 x 0.65 cm at the cranial pole and 0.41 cm at the caudal pole. The left adrenal gland measured 1.77 x 0.56 cm at the cranial pole and 0.74 cm at the caudal pole.

**INTERPRETED BY**

Eric Lindquist, DMV  
 DABVP, Cert. IVUSS

**IMAGING PERFORMED BY**

Shari Reffi, CVT

**Spleen**

The **spleen** presented a smooth homogeneous parenchyma hyperechoic to liver and renal cortical parenchyma. The capsule was smooth without noticeable expansion or deviation from within the spleen or adjacent pathology. The splenic vasculature demonstrated normal volume without signs of congestion or thrombosis. No sonographic evidence of acute or chronic inflammatory, neoplastic, or infarctual changes was noted.

**HOSPITAL NAME**

American AH

**REFERRING VET**

Dr. Stockmal

**Liver**

The **liver** in this patient revealed a 6.3 cm expansive, hyperechoic mass at the caudate process. Regional inflammation was noted around the liver mass. The mass deviated the diaphragm dorsally. The gallbladder presented acceptably thin walls with primarily anechoic content. The cystic and common bile ducts were normal.

**INVOICE**

96765

**DATE**

3/10/22



**PATIENT**

**Gastrointestinal**

Charlie Miller

Pyloric hypertrophy was noted with mild muscularis hypertrophy and echogenic mucosal remodeling. The remainder of the intestinal tract was unremarkable.

**SPECIES**

Canine

**Pancreas**

**BREED**

Mix

The base and limbs of the **pancreas** were observed to be largely isoechoic to surrounding omental fat. Some parenchymal remodeling, however, with mild deviation from curvilinear normalcy was observed. Pancreatic duct and capsular irregularities were present consistent with age related changes. If pain upon imaging (+ Murphy sign) was present or if the patient is focally painful in subxiphoid palpation then low-grade smoldering chronic pancreatitis should be suspected.

**SEX**

Neutered male

**ULTRASONOGRAPHIC FINDINGS**

**AGE**

14 years

Right medial hepatic mass.

Secondary pancreatitis is suspected.

**WEIGHT**

14 lbs

**INTERPRETATION OF THE FINDINGS & FURTHER RECOMMENDATIONS**

Subxiphoid palpation is recommended to assess for pain-solicited response. If pain is noted low grade pancreatitis is suspected.

**INTERPRETED BY**

Eric Lindquist, DMV  
DABVP, Cert. IVUSS

The right medial liver mass does not appear resectable. FNA could be considered for further definition. CT evaluation could be considered for further assessment as well as brain CT given the seizure activity, metastatic or separate primary disease may be present in the CNS. The prognosis is poor long term.

**IMAGING PERFORMED BY**

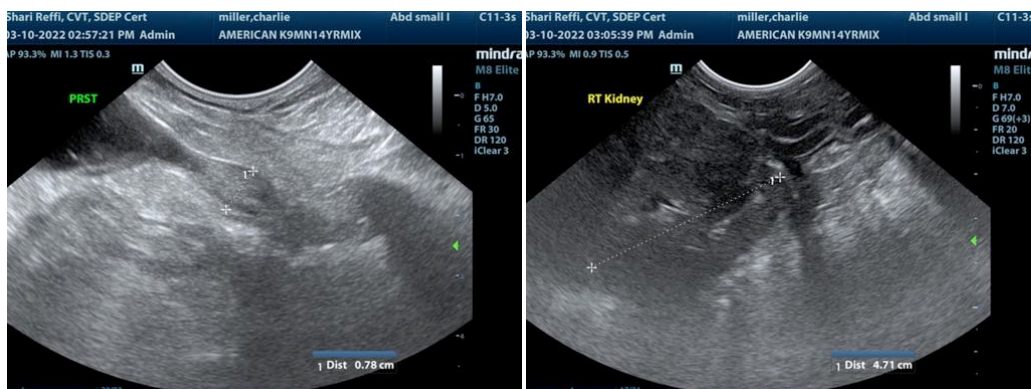
Shari Reffi, CVT

**HOSPITAL NAME**

American AH

**REFERRING VET**

Dr. Stockmal



**INVOICE**

96765

**DATE**

3/10/22



**PATIENT**

Charlie Miller

**SPECIES**

Canine

**BREED**

Mix

**SEX**

Neutered male

**AGE**

14 years

**WEIGHT**

14 lbs

**INTERPRETED BY**

Eric Lindquist, DMV  
DABVP, Cert. IVUSS

**IMAGING PERFORMED BY**

Shari Reffi, CVT

**HOSPITAL NAME**

American AH

**REFERRING VET**

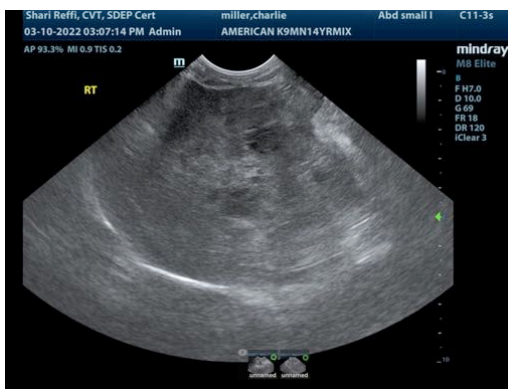
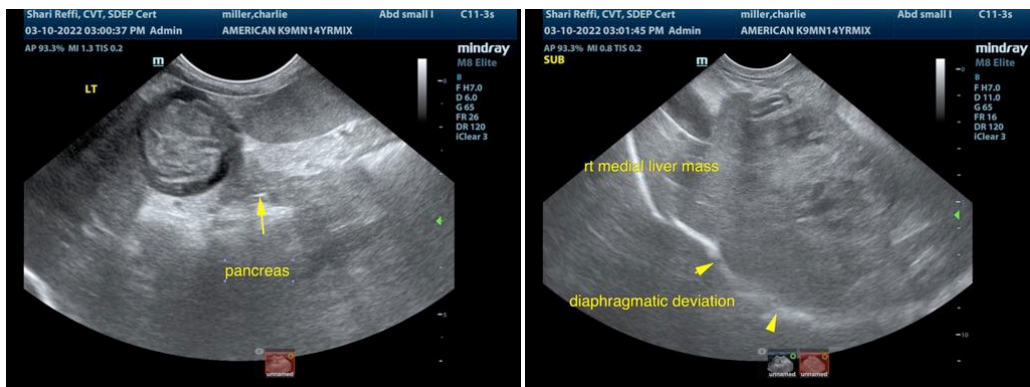
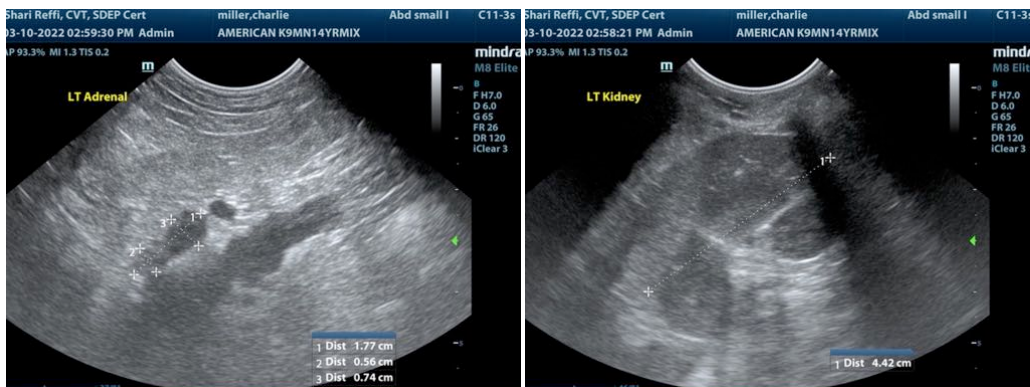
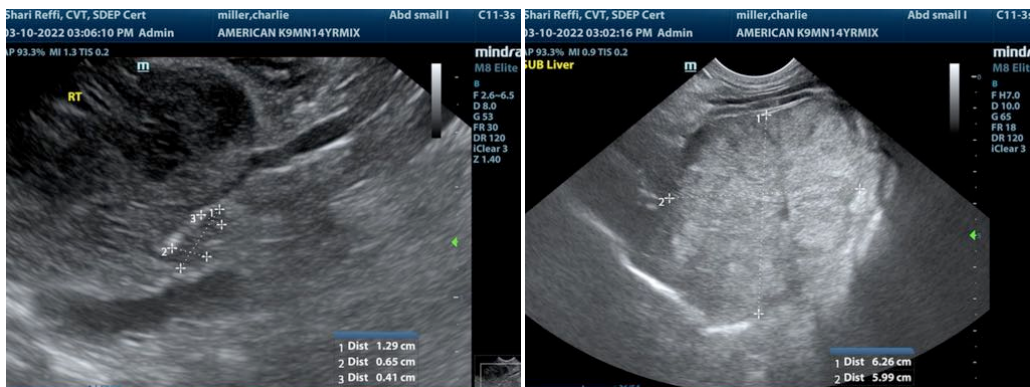
Dr. Stockmal

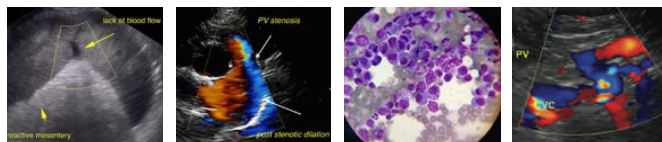
**INVOICE**

96765

**DATE**

3/10/22





**PATIENT**

Charlie Miller

The information and recommendations provided are based on the images presented by the referring veterinarian/sonographer. No evaluation can be communicated regarding pathology that was not visible in the image/video clips provided.

**SPECIES**

Canine

Thank you for this referral. If the clinical or image interpretation does not parallel your findings or if I can be of any further assistance please contact me.

**BREED**

Mix

**Eric Lindquist, DMV, DABVP, Cert. IVUSS, CEO of SonoPath.com**  
Info@SonoPath.com

**SEX**

Neutered male

**AGE**

14 years

**WEIGHT**

14 lbs

**INTERPRETED BY**

Eric Lindquist, DMV  
DABVP, Cert. IVUSS

**IMAGING  
PERFORMED BY**

Shari Reffi, CVT

**HOSPITAL NAME**

American AH

**REFERRING VET**

Dr. Stockmal

**INVOICE**

96765

**DATE**

3/10/22