



PATIENT

Tiffany Valentin

SPECIES

Canine

BREED

Maltese

SEX

Spayed female

AGE

14 years

WEIGHT

11 lbs

INTERPRETED BY

Eric Lindquist, DMV
DABVP, Cert. IVUSS

IMAGING PERFORMED BY

Dr. Ferrer

HOSPITAL NAME

Paseos VC

REFERRING VET

Dr. Davila

INVOICE

43055

DATE

3/1/23

PRESENTING CLINICAL SIGNS

History: The patient is referred to us from Centro de Salud Veterinaria because of an enlarged palpable thyroid gland. Currently, the patient is on thyro-tabs (0.1 mg) 1/2 tablet SID. FNA of the mass was done and the cytology it is pending

Abnormal PE/Chem/CBC/UA Results: PE: Neck mass on the right side where the thyroid gland is located.

ULTRASONOGRAPHIC EXAMINATION OF THE CERVICAL REGION

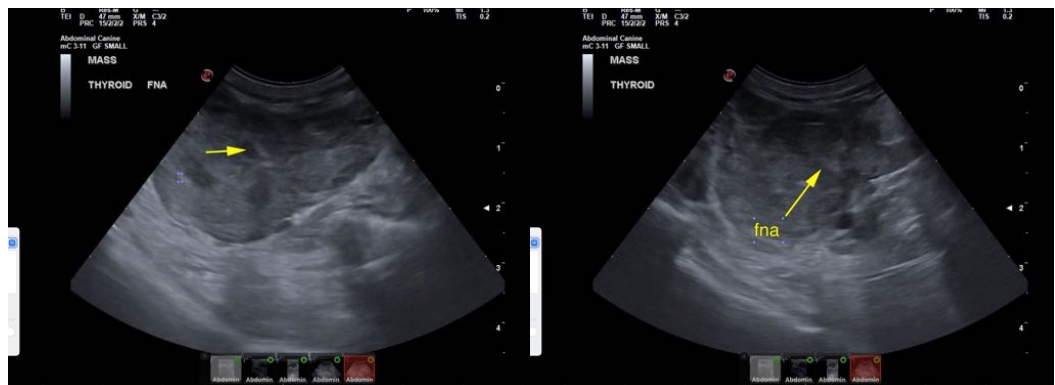
A mixed, hypoechoic, microcystic and nodular 3.5 cm mass was noted in the cervical region. It appears to be deriving from the area of the right thyroid lobe. It is expansive, nodular and envelops regional tissues and invades regional vessels. The trachea and esophagus appear unremarkable.

ULTRASONOGRAPHIC FINDINGS

Mass in the region of the right thyroid lobe with regional vascular invasion and capsular escape and invasion of regional tissues.

INTERPRETATION OF THE FINDINGS & FURTHER RECOMMENDATIONS

25-gauge FNA was performed without complication. The mass does not appear resectable. CT evaluation can be considered for further evaluation, but based on these findings I do not think this is a surgical option regardless of the underlying pathology and the tissue appears fairly aggressive. Thyroid carcinoma is suspected given the biological and sonographic behavior.





PATIENT

Tiffany Valentin

SPECIES

Canine

BREED

Maltese

SEX

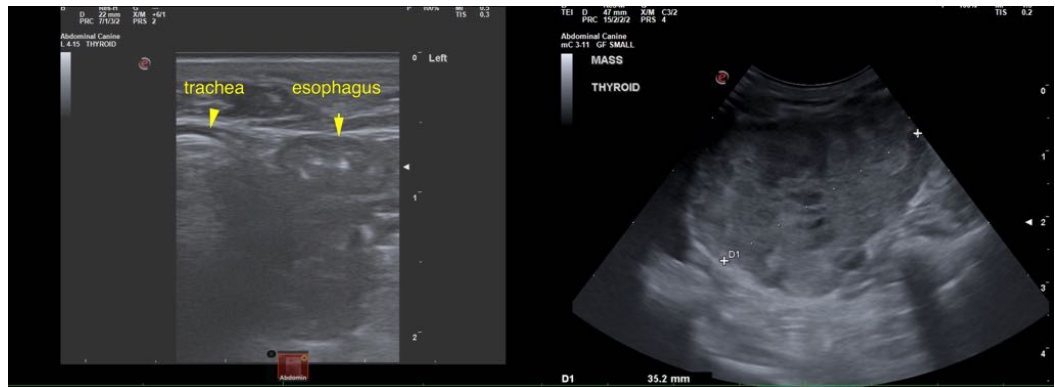
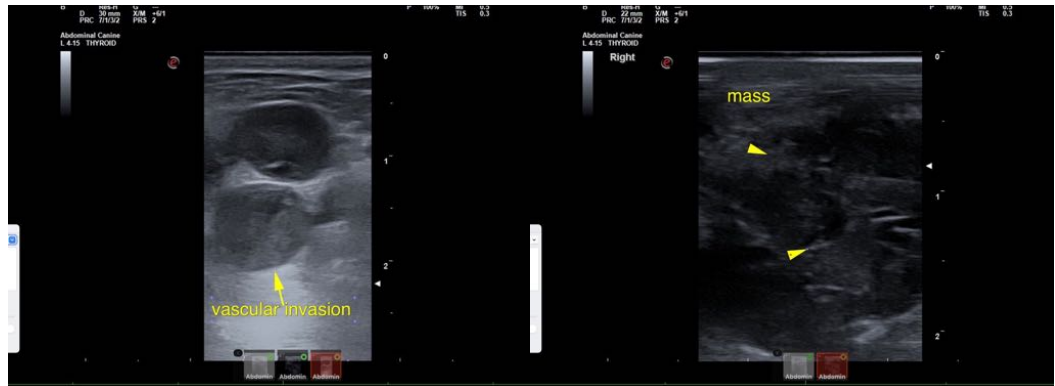
Spayed female

AGE

14 years

WEIGHT

11 lbs



INTERPRETED BY

Eric Lindquist, DMV
DABVP, Cert. IVUSS

IMAGING PERFORMED BY

Dr. Ferrer

HOSPITAL NAME

Paseos VC

REFERRING VET

Dr. Davila

INVOICE

43055

DATE

3/1/23

The information and recommendations provided are based on the images presented by the referring veterinarian/sonographer. No evaluation can be communicated regarding pathology that was not visible in the image/video clips provided.

Thank you for this referral. If the clinical or image interpretation does not parallel your findings or if I can be of any further assistance please contact me.

Eric Lindquist, DMV, DABVP, Cert. IVUSS, CEO of SonoPath.com
info@SonoPath.com