



**PATIENT**

Bailey Zabell

**SPECIES**

Canine

**BREED**

Lab X

**SEX**

Spayed Female

**AGE**

9 Years

**WEIGHT**

60 Pounds

**INTERPRETED BY**

Eric Lindquist, DMV

DABVP, Cert. IVUSS

**IMAGING PERFORMED BY**

Chaley Hunt, LVT

**HOSPITAL NAME**

Columbia AC

**REFERRING VET**

Dr. Michelle Engel

**INVOICE**

45596

**DATE**

3/1/23

**PRESENTING CLINICAL SIGNS**

Senior lab work on Dec. 14, 2022. CBC-normal Chemistry-ALP 582 (5 - 160 U/L), was 355, 436 UA-USG-1.044 T4-normal. Spoke to owner regarding results-Had significantly elevated ALP and ALT in 2017. Was put on Denamarin and she didn't tolerate it well. Since 2017, ALP has been a little up and down. Recommended ultrasound as the next step.

**ULTRASONOGRAPHIC EXAMINATION OF THE ABDOMEN**

**Urinary System**

The **urinary bladder**, trigone, and pelvic urethra presented normal thicknesses and normal tone. The ureters were not visible which is normal. No uroliths or sediment were visualized and anechoic urine was present. No evidence of inflammatory or neoplastic changes were noted. Ureteral papillae were normal. The pelvic urethra was imaged 1.0 cm beyond the cystourethral junction.

The **kidneys** revealed largely normal size and structure, corticomedullary definition and ratio (cortex 1/3 of medulla) were essentially maintained with some age-related loss of curvilinear patterns regarding the capsule and C/M junction. The cortices presented largely uniform texture with some increased echogenicity expected for his age patient. Medullary structure differed distinctly from that of the cortex and no evidence of pelvic dilation was present. The right kidney measured 6.6 cm. The left kidney measured 6.0 cm.

**Adrenal Glands**

Both **adrenal glands** were visualized and recognized as having normal shape, size, position and echogenicity for this breed. The phrenic vasculature, glandular echogenicity and detail were unremarkable. Capsule, cortex, and medullary definition were normal for this age patient. The left adrenal gland measured 0.48 cm at the cranial pole and 0.55 cm at the caudal pole. The right adrenal gland measured 0.20 cm at the cranial pole and 0.95 cm at the caudal pole.

**Spleen**

The **spleen** was largely smooth with subtle heterogeneous parenchymal changes while maintaining normal echogenic relationship to the liver and kidney. These changes are consistent with normal age-related alteration. The capsule was smooth without noticeable impingement from within the spleen or from pathology in the adjacent abdomen. The splenic vasculature demonstrated normal volume without signs of congestion or significant contraction. No evidence of active acute or chronic inflammatory, neoplastic, or infarctual changes were noted.

**Liver**

The **liver** was uniformly swollen with minor, excessive gallbladder debris and over distension with dependent and suspended bile without evidence of overt mucocele formation. However, excessive sludge was present. The liver presented coarse architecture with mildly increased portal markings and subtle, mixed echogenic changes. This is consistent with vacuolar hepatopathy and some level of remodeling and history of inflammatory component. There was no overt suspicion of neoplasia.

**Gastrointestinal**

Examination of the **gastrointestinal tract** revealed a stomach and intestine free of stasis, of normal wall thickness, acceptable curvilinear mural detail, and peristaltic activity. Small and large intestine demonstrated normal luminal chyme and stool consistency respectively. No obstructive or overt infiltrative disease was noted. No associated abnormal lymphatic activity was noted.



**PATIENT**

Bailey Zabell

**SPECIES**

Canine

**BREED**

Lab X

**SEX**

Spayed Female

**AGE**

9 Years

**WEIGHT**

60 Pounds

**INTERPRETED BY**

Eric Lindquist, DMV

DABVP, Cert. IVUSS

**IMAGING PERFORMED BY**

Chaley Hunt, LVT

**HOSPITAL NAME**

Columbia AC

**REFERRING VET**

Dr. Michelle Engel

**INVOICE**

45596

**DATE**

3/1/23

**Pancreas**

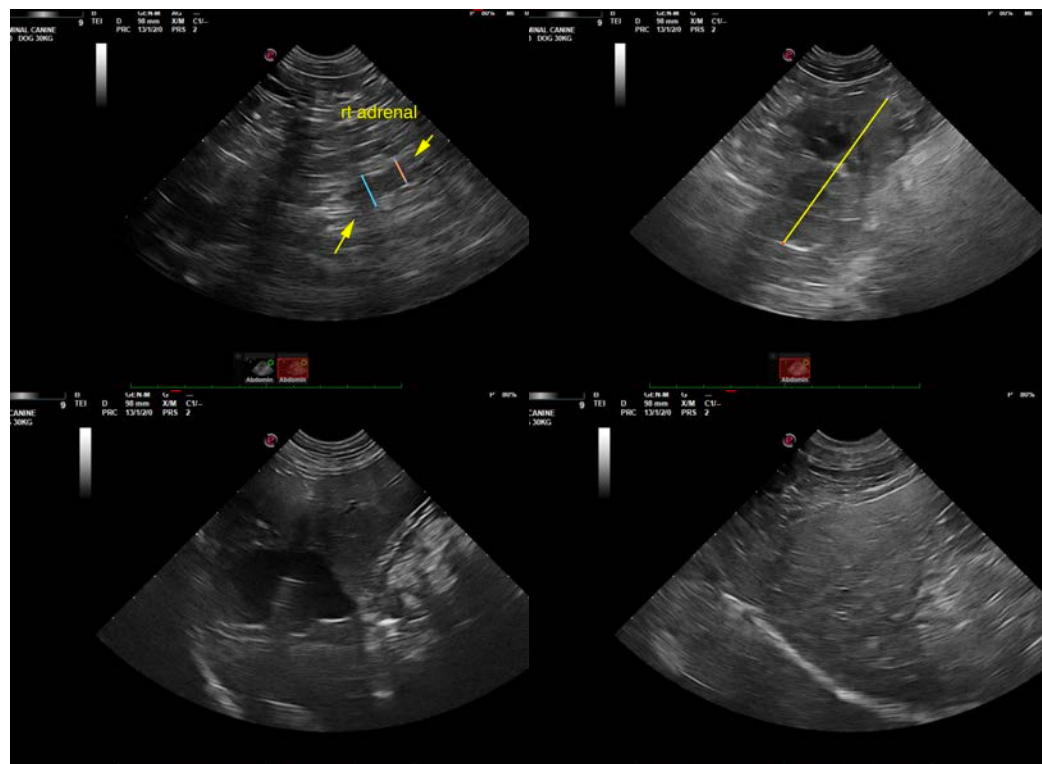
The base and limbs of the **pancreas** were observed to be largely isoechoic to surrounding omental fat. Pancreatic duct and capsular contour were acceptably normal and parenchyma respected normal curvilinear patterns. No overt evidence of active inflammatory or neoplastic disease was noted.

**ULTRASONOGRAPHIC FINDINGS**

- Vacuolar hepatopathy
- Age related renal changes
- Age related splenic changes

**INTERPRETATION OF THE FINDINGS & FURTHER RECOMMENDATIONS**

FNA of the liver could be considered for further definition, however subjectively it appears benign.





**PATIENT**

Bailey Zabell

**SPECIES**

Canine

**BREED**

Lab X

**SEX**

Spayed Female

**AGE**

9 Years

**WEIGHT**

60 Pounds

**INTERPRETED BY**

Eric Lindquist, DMV

DABVP, Cert. IVUSS

**IMAGING PERFORMED BY**

Chaley Hunt, LVT

**HOSPITAL NAME**

Columbia AC

**REFERRING VET**

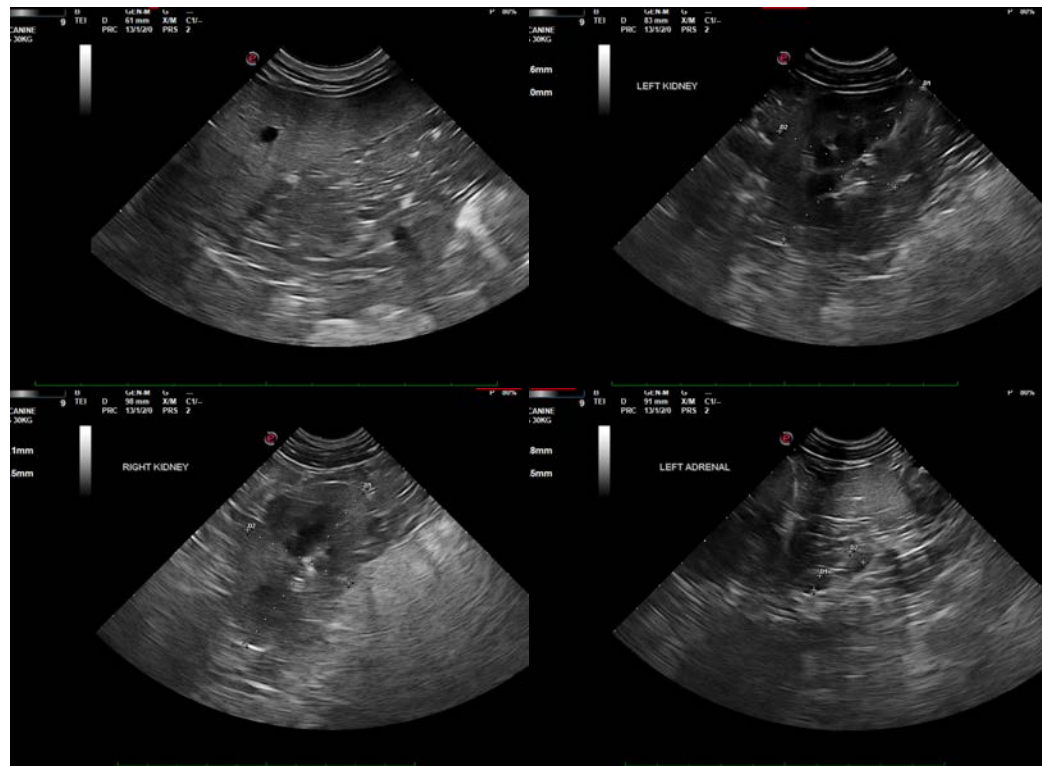
Dr. Michelle Engel

**INVOICE**

45596

**DATE**

3/1/23



The information and recommendations provided are based on the images presented by the referring veterinarian/sonographer. No evaluation can be communicated regarding pathology that was not visible in the image/video clips provided.

Thank you for this referral. If the clinical or image interpretation does not parallel your findings or if I can be of any further assistance please contact me.

Eric Lindquist, DMV, DABVP, Cert. IVUSS, CEO of SonoPath.com

[info@SonoPath.com](mailto:info@SonoPath.com)