



PATIENT	PRESENTING CLINICAL SIGNS
Lucy Mancini	Right kidney enlarged on palpation. Chronic cough, Dx with chronic bronchitis that improved on Prednisolone. Sedated with Gabapentin PO.
SPECIES	Abnormal PE/Chem/CBC/UA Results: PE: BCS 7/9, R kidney palpates larger than L kidney. Previous auscultation: bilateral crackles/rales, raspy. Mild nasal discharge with crusts. UA and BW: stable renal values. HW test not done. RADS (thorax): evidence of chronic bronchitis.
Feline	
BREED	ULTRASONOGRAPHIC EXAMINATION OF THE ABDOMEN
Domestic Shorthair	Urinary System
SEX	The urinary bladder , trigone, and pelvic urethra presented normal thicknesses and normal tone. The ureters were not visible which is normal. No uroliths or sediment were visualized and anechoic urine was present. No evidence of inflammatory or neoplastic changes was noted. Ureteral papillae were normal.
Spayed Female	
AGE	The kidneys revealed normal size and structure, corticomedullary definition and ratio for this age. The cortices presented largely uniform texture with normal echogenic relationship to liver and spleen. Medullary structure differed distinctly from the cortex and no evidence of pelvic dilation was present. The capsules were acceptably uniform without significant irregularities. The left kidney revealed a cortical infarct and cortical collapse. The left kidney measured 3.3 cm. The right kidney measured 3.86 cm.
4 years	
WEIGHT	
11.3 lbs	
INTERPRETED BY	Adrenal Glands
Eric Lindquist, DMV DABVP, Cert. IVUSS	Both adrenal glands were visualized and recognized as having normal shape, size, position and echogenicity for this breed. The phrenic vasculature, glandular echogenicity and detail were unremarkable. Capsule, cortex, and medullary definition were normal for this age patient. The left adrenal gland measured 0.5 cm.
IMAGING PERFORMED BY	Spleen
Dr. Ebersole	The spleen presented a smooth homogeneous parenchyma hyperechoic to liver and renal cortical parenchyma. The capsule was smooth without noticeable expansion or deviation from within the spleen or adjacent pathology. The splenic vasculature demonstrated normal volume without signs of congestion or thrombosis. No sonographic evidence of acute or chronic inflammatory, neoplastic, or infarctual changes was noted.
HOSPITAL NAME	
Scanvet	
REFERRING VET	
Dr. Kaltsas	
INVOICE	Liver
96511	The liver images submitted revealed subjectively normal liver size, contour, and structure. Parenchymal echogenicity was naturally coarse and hypoechoic to the spleen. Vascular and biliary tracts were of normal volume with no evidence of congestion. The gallbladder presented acceptably thin walls with primarily anechoic content. The cystic and common bile ducts were normal. No pathological hepatic lymphadenopathy was evident. No overt structural evidence of inflammatory, infiltrative or regenerative pathology was evident. Comet tail lung pattern was noted in the lung fields.
DATE	
3/1/22	



PATIENT

Gastrointestinal

Lucy Mancini

Examination of the **gastrointestinal tract** revealed a stomach and intestine free of stasis, of normal wall thickness, acceptable curvilinear mural detail, and peristaltic activity. Small and large intestine demonstrated normal luminal chyme and stool consistency respectively. No obstructive or overt infiltrative disease was noted. No associated abnormal lymphatic activity was noted.

SPECIES

Feline

Pancreas

BREED

Domestic Shorthair

The base and limbs of the **pancreas** were observed to be largely isoechoic to surrounding omental fat. Pancreatic duct and capsular contour were acceptably normal and parenchyma respected normal curvilinear patterns. No overt evidence of active inflammatory or neoplastic disease was noted.

SEX

Spayed Female

ULTRASONOGRAPHIC FINDINGS

AGE

4 years

Left renal infarct, stable. There was no evidence of active inflammation. Mild subnormal left renal size due to infarct.

Comet tail lung pattern.

WEIGHT

11.3 lbs

INTERPRETATION OF THE FINDINGS & FURTHER RECOMMENDATIONS

The infarct is the reason why the left kidney is smaller than the right, but appears to be stable. Urinalysis is warranted if not already performed to assess for any inflammatory sediment. No specific therapy is warranted unless inflammatory sediment is present in the urine. Chest radiographs are warranted to assess for any alveolar disease.

INTERPRETED BY

Eric Lindquist, DMV
DABVP, Cert. IVUSS

IMAGING PERFORMED BY

Dr. Ebersole

HOSPITAL NAME

Scanvet

REFERRING VET

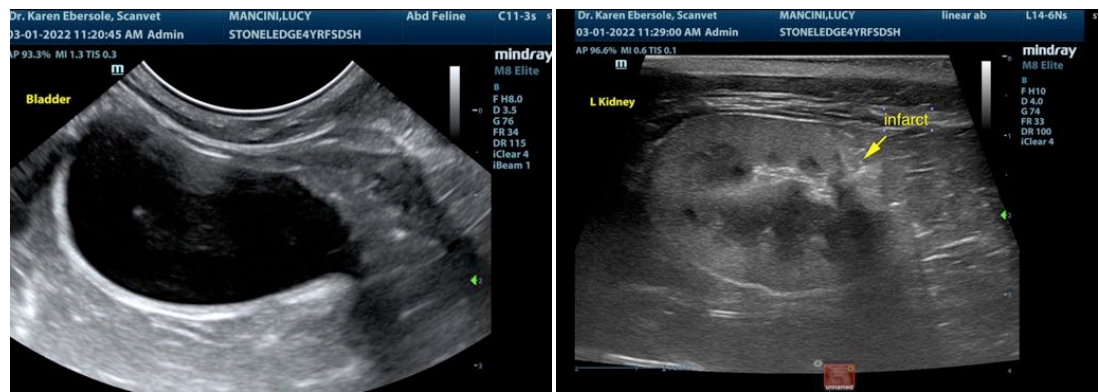
Dr. Kaltsas

INVOICE

96511

DATE

3/1/22





PATIENT

Lucy Mancini

SPECIES

Feline

BREED

Domestic Shorthair

SEX

Spayed Female

AGE

4 years

WEIGHT

11.3 lbs

INTERPRETED BY

Eric Lindquist, DMV
DABVP, Cert. IVUSS

IMAGING PERFORMED BY

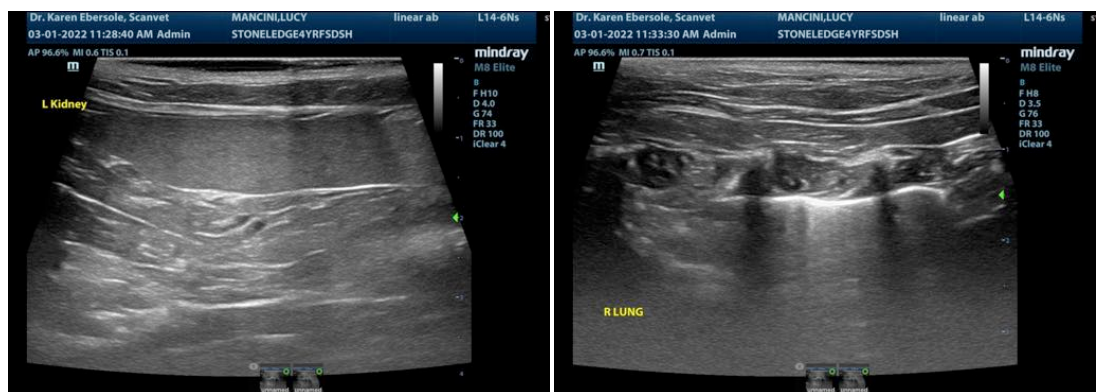
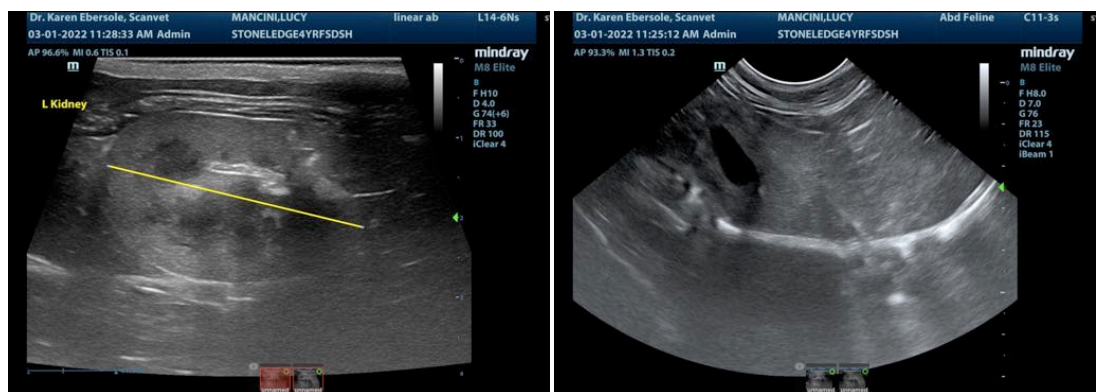
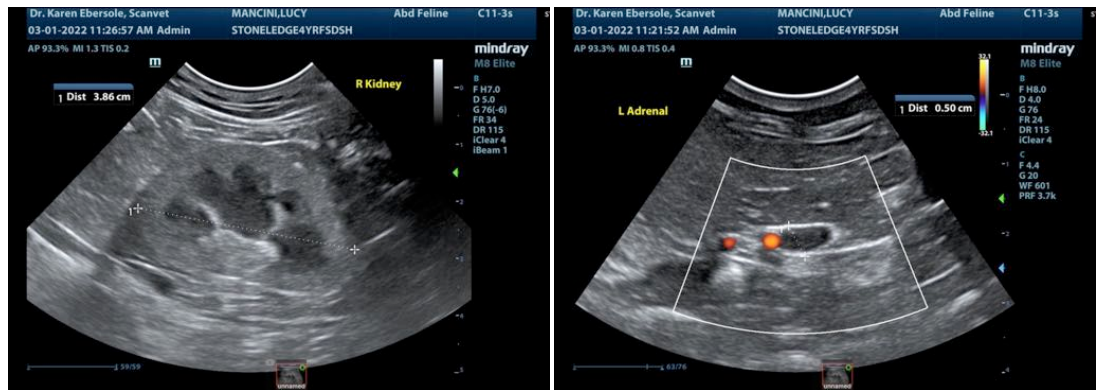
Dr. Ebersole

HOSPITAL NAME

Scanvet

REFERRING VET

Dr. Kaltsas



INVOICE

96511

DATE

3/1/22

The information and recommendations provided are based on the images presented by the referring veterinarian/sonographer. No evaluation can be communicated regarding pathology that was not visible in the image/video clips provided.

Thank you for this referral. If the clinical or image interpretation does not parallel your findings or if I can be of any further assistance please contact me.



PATIENT

Eric Lindquist, DMV, DABVP, Cert. IVUSS, CEO of SonoPath.com
info@SonoPath.com

Lucy Mancini

SPECIES

Feline

BREED

Domestic Shorthair

SEX

Spayed Female

AGE

4 years

WEIGHT

11.3 lbs

INTERPRETED BY

Eric Lindquist, DMV
DABVP, Cert. IVUSS

**IMAGING
PERFORMED BY**

Dr. Ebersole

HOSPITAL NAME

Scanvet

REFERRING VET

Dr. Kaltsas

INVOICE

96511

DATE

3/1/22