



PATIENT

Isabelle Torres

SPECIES

Feline

BREED

Domestic Shorthair

SEX

Spayed Female

AGE

17 years

WEIGHT

5.4 lbs

INTERPRETED BY

Eric Lindquist, DMV
DABVP, Cert. IVUSS

IMAGING PERFORMED BY

Dr. Goodman

HOSPITAL NAME

Evandale Blue Ash PH

REFERRING VET

Dr. Goodman

INVOICE

96521

DATE

3/1/22

PRESENTING CLINICAL SIGNS

History: Recheck cardiac ultrasound from 10/18/21. Previous cardiac ultrasounds performed 10/12/21, 1/26/2021, 6/29/2020. Patient is doing well at home. Intermittently on benazepril, has not received it in about a week. No blood pressure performed today.

ULTRASONOGRAPHIC EXAMINATION OF THE HEART

The echocardiogram in this patient revealed normal chamber volumes with minor left ventricular hypertrophy. This is similar to the prior echocardiogram. There was no progression noted. The contractility was adequate. No pericardial or pleural effusion was noted.

FELINE CARDIAC PARAMETERS	BODY WEIGHT (kg)	HR (BPM)	IVSd (cm)	LVIDd (cm)	LVWd (cm)	FS (%)	EF (%)
NORMAL PARAMETER	-----	150-240	0.3-0.6	1.0-2.1	0.25-0.6	35-67	80-100
PATIENT		NM	0.86	1.2	0.5	50	
FELINE CARDIAC PARAMETERS	LA/AO (Boon)	LA/AO HEART BASE (Sisson)	LA 2D 4-chamber long axis AS to FW (Sisson) (cm)	LVOT VEL. (m/s)	RVOT VEL. (m/s)	IVRT (m/)	
NORMAL PARAMETER	<1.5	0.88-1.79	0.7-1.7	<1.6	<1.3	40-60	
PATIENT	1.15	1.4			1.0	NM	
Adapted from June Boon, Veterinary Echocardiography, 1998 Sisson D et al. JVIM 1991; 5: 232, Jacobs et al. Am J Vet Res 1985; 46:1705							

ULTRASONOGRAPHIC FINDINGS

Minor left ventricular hypertrophy.
No evidence of significant disease.

INTERPRETATION OF THE FINDINGS & FURTHER RECOMMENDATIONS

No therapy is warranted.



PATIENT

Isabelle Torres

SPECIES

Feline

BREED

Domestic Shorthair

SEX

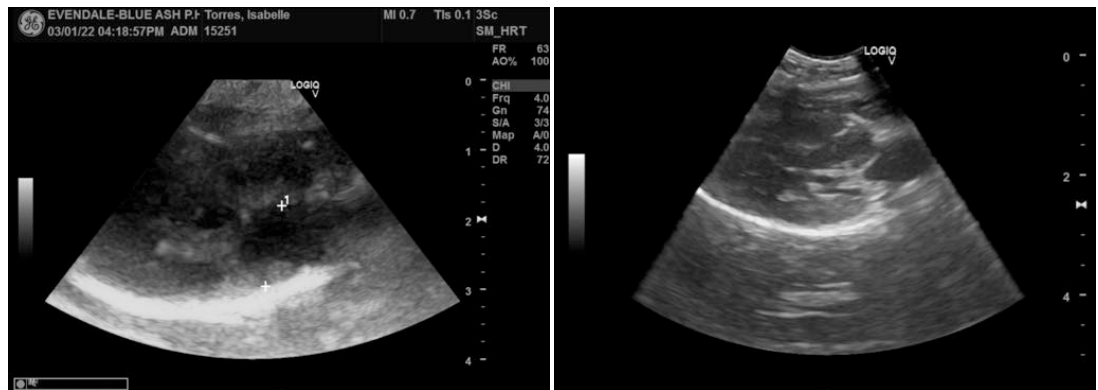
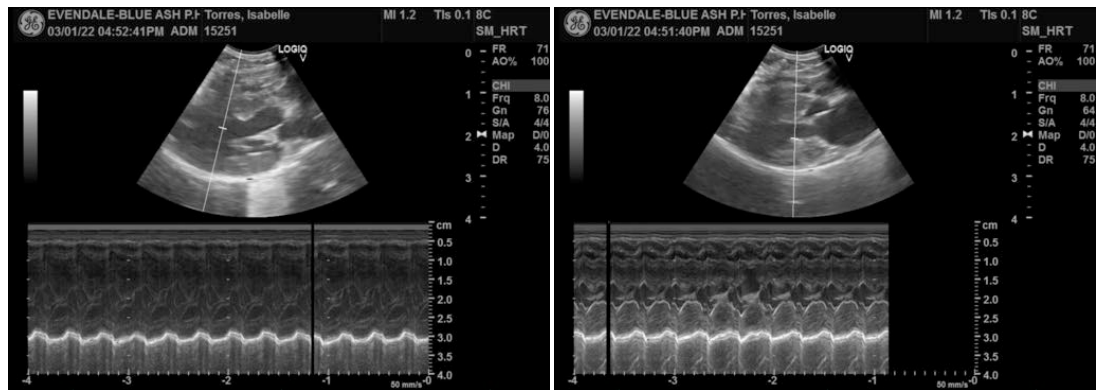
Spayed Female

AGE

17 years

WEIGHT

5.4 lbs



INTERPRETED BY

Eric Lindquist, DMV
DABVP, Cert. IVUSS

The information and recommendations provided are based on the images presented by the referring veterinarian/sonographer. No evaluation can be communicated regarding pathology that was not visible in the image/video clips provided.

IMAGING PERFORMED BY

Dr. Goodman

Thank you for this referral. If the clinical or image interpretation does not parallel your findings or if I can be of any further assistance please contact me.

HOSPITAL NAME

Evandale Blue Ash PH

Eric Lindquist, DMV, DABVP, Cert. IVUSS, CEO of SonoPath.com
info@SonoPath.com

REFERRING VET

Dr. Goodman

INVOICE

96521

DATE

3/1/22