



**PATIENT**

Chewbacca Ellrott

**PRESENTING CLINICAL SIGNS**

Vomiting, anorexia, weight loss.

BUN 79, creatinine 2.9, phos 17.5, amylase 2109, albumin 1.8

**SPECIES**

Canine

CBC HCT 32, RBC 4, Hb 10.9

Urinalysis 3+ protein, blood 3+ MA > 30.

**BREED**

Bichapoo

**ULTRASONOGRAPHIC EXAMINATION OF THE ABDOMEN**

*Urinary System*

**SEX**

Male

The **urinary bladder** was largely normal. However, a 1.0 x 0.5 cm coalesced clot or polyp was noted adjacent to the ureteral papillae. This appears to be attached to the mucosa and non vascular based on Power Doppler assessment.

**AGE**

4 years

The **prostate** was uniformly enlarged with lobar swelling appeared to impinge upon the urethra and mildly deviate the descending colon. The prostatic tissue was hyperechoic containing focal areas of decreased echogenicity. These changes are suggestive of either chronic inflammatory episodes, benign cystic pathology or both. Underlying neoplasia cannot be completely ruled-out but is lower on the differential list. This presentation is most consistent with benign prostatic hyperplasia with possible active prostatitis. Neutering or off-label Finasteride (Propecia) (0.1-0.5 mg/kg Sid) treatment is indicated +/- FNA or prostatic wash cytology and culture. The prostate measured 3.41 cm.

**INTERPRETED BY**

Eric Lindquist, DMV  
DABVP, Cert. IVUSS

The **kidneys** were normal in size and contour with trace pyelectasia. The left kidney measured 5.34 cm. The pyelectasia in the right kidney measured 1.16 x 0.5 cm.

**IMAGING PERFORMED BY**

Eric Lindquist, DMV  
DABVP, Cert. IVUSS

*Adrenal Glands*

The left **adrenal gland** was subjectively flattened, yet technically normal in size at 2.0 x 0.51 cm. The right adrenal gland was flattened and isoechoic measuring 1.6 x 0.37 cm.

**HOSPITAL NAME**

Andover AH

*Spleen*

**REFERRING VET**

Dr. Lind

The **spleen** presented a smooth homogeneous parenchyma hyperechoic to liver and renal cortical parenchyma. The capsule was smooth without noticeable expansion or deviation from within the spleen or adjacent pathology. The splenic vasculature demonstrated normal volume without signs of congestion or thrombosis. No sonographic evidence of acute or chronic inflammatory, neoplastic, or infarctual changes was noted.

**INVOICE**

96477

*Liver*

**DATE**

3/1/22

The **liver** images submitted revealed subjectively normal liver size, contour, and structure. Parenchymal echogenicity was naturally coarse and hypoechoic to the spleen. Vascular and biliary tracts were of normal volume with no evidence of congestion. Gallbladder polyps were noted.



**PATIENT**

**Gastrointestinal**

Chewbacca Ellrott

The **stomach** was thickened with a prominent mucosa and empty lumen. There was no loss of mural detail. This is consistent with uremic gastritis.

**SPECIES**

Canine

**Pancreas**

The base and limbs of the **pancreas** were observed to be largely isoechoic to surrounding omental fat. Pancreatic duct and capsular contour were acceptably normal and parenchyma respected normal curvilinear patterns. No overt evidence of active inflammatory or neoplastic disease was noted.

**BREED**

Bichapoo

**SEX**

Male

**ULTRASONOGRAPHIC FINDINGS**

Bladder polyp or clot.

BPH prostate.

**AGE**

4 years

Flattened adrenal glands.

Minor degenerative renal changes.

**INTERPRETED BY**

Eric Lindquist, DMV  
DABVP, Cert. IVUSS

**INTERPRETATION OF THE FINDINGS & FURTHER RECOMMENDATIONS**

Treatment for acute renal failure and screening for Addison's as well as Leptospirosis titers are warranted along with tick borne disease titers. Assessment for toxin exposure is warranted. Blood pressure +/- urine culture is indicated as well as 72 hour IV fluid protocol and reassessment of the azotemia. GI protectants are also indicated.

**IMAGING PERFORMED BY**

Eric Lindquist, DMV  
DABVP, Cert. IVUSS

**HOSPITAL NAME**

Andover AH

**REFERRING VET**

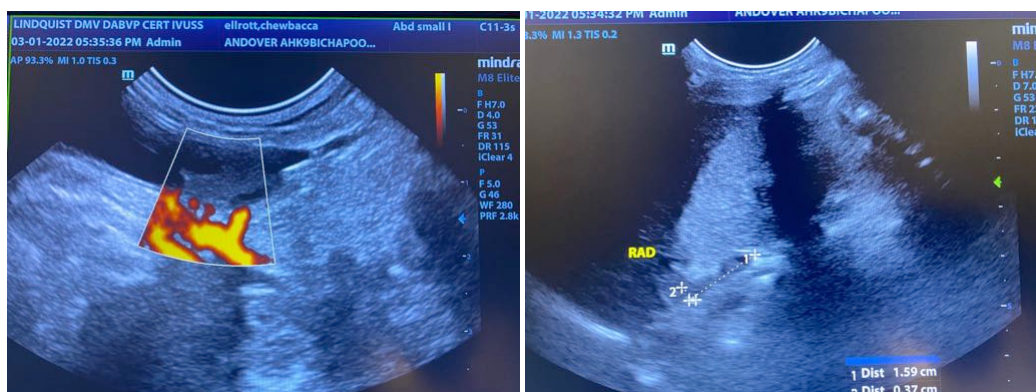
Dr. Lind

**INVOICE**

96477

**DATE**

3/1/22





**PATIENT**

Chewbacca Ellrott

**SPECIES**

Canine

**BREED**

Bichapoo

**SEX**

Male

**AGE**

4 years

**INTERPRETED BY**

Eric Lindquist, DMV DABVP, Cert. IVUSS

**IMAGING PERFORMED BY**

Eric Lindquist, DMV DABVP, Cert. IVUSS

**HOSPITAL NAME**

Andover AH

**REFERRING VET**

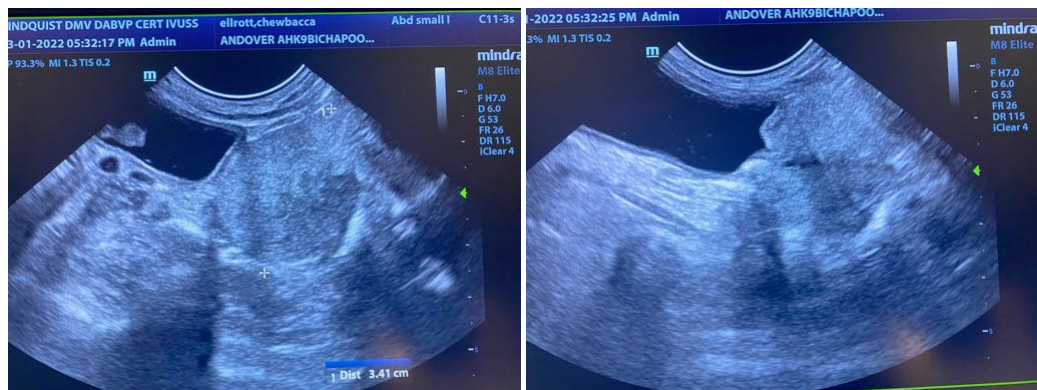
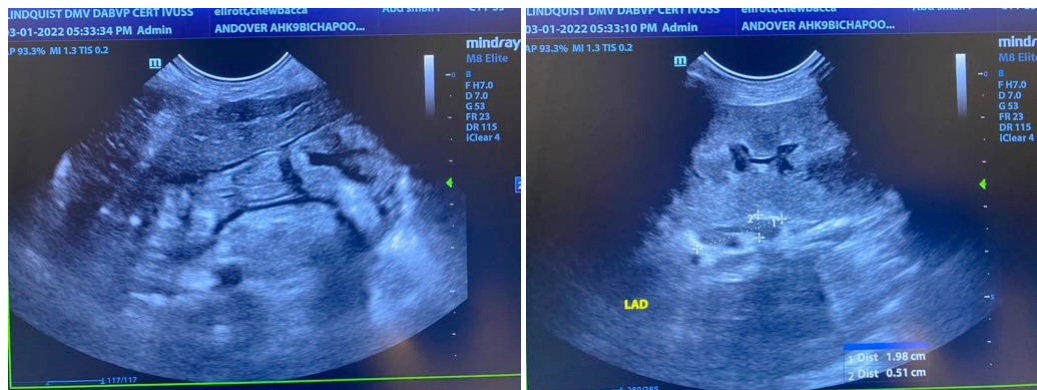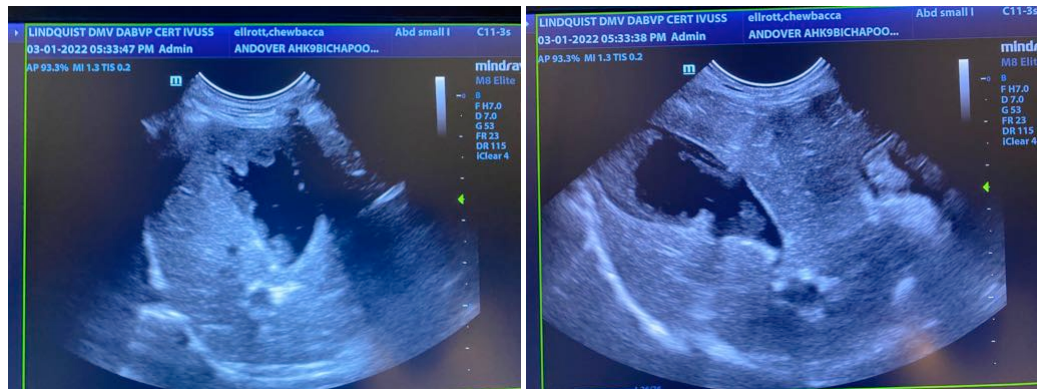
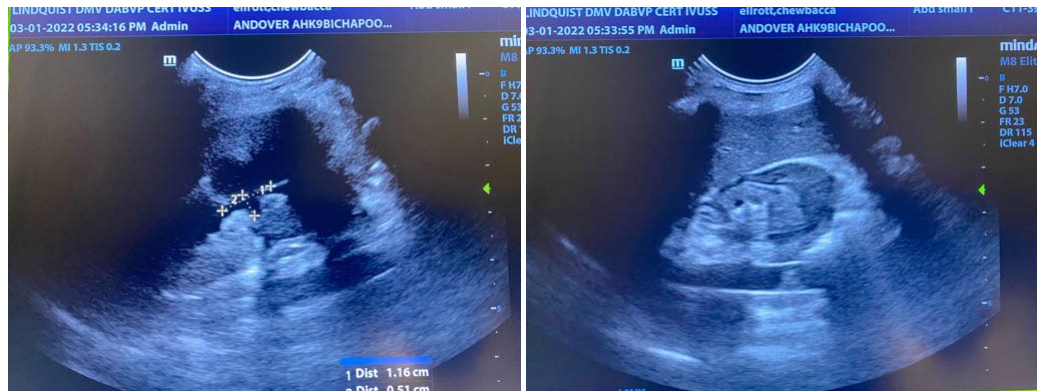Dr. Lind

**INVOICE**

96477

**DATE**

3/1/22





**PATIENT**

Chewbacca Ellrott

The information and recommendations provided are based on the images presented by the referring veterinarian/sonographer. No evaluation can be communicated regarding pathology that was not visible in the image/video clips provided.

**SPECIES**


Canine

Thank you for this referral. If the clinical or image interpretation does not parallel your findings or if I can be of any further assistance please contact me.

**Eric Lindquist, DMV, DABVP, Cert. IVUSS, CEO of SonoPath.com**  
Info@SonoPath.com

**BREED**

Bichapoo



The following is an applicable excerpt from the *Curbside Guide to Diagnosis & Treatment of Sonographic Disease* offered by [SonoPath.com](http://sonopath.com) Lindquist, Frank, Lobetti, and Modler.

**SEX**

Male

An essential quick guide for every general practitioner and sonographer.

<https://sonopath.com/products/curbside-guide-editing-due-release-12012015>

**AGE**

4 years

**Acute Renal Failure**

<http://www.sonopath.com/ARF>

**INTERPRETED BY**

Eric Lindquist, DMV  
DABVP, Cert. IVUSS

**IMAGING PERFORMED BY**

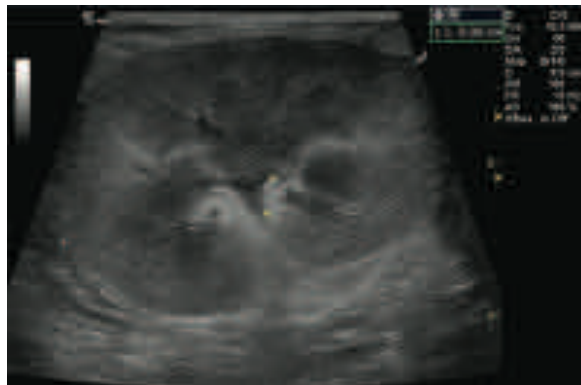Eric Lindquist, DMV  
DABVP, Cert. IVUSS

**HOSPITAL NAME**

Andover AH

**REFERRING VET**

Dr. Lind



Long axis of the kidney in a cat with a renal transplant and acute renal failure. Note the generalized swelling of the kidney with loss of corticomedullary definition. The renal pelvis shows mild dilation with anechoic content (arrow heads). The renal crest and sinus are hyperechoic.

**INVOICE**

96477

**DATE**

3/1/22

**Description:** Acute renal failure (ARF)—also referred to as acute kidney injury—is defined as a rapid deterioration in renal function that results in the accumulation of metabolic waste in the body. It is characterized by an impaired regulation of water and solute balances, and may be due to prerenal, postrenal, and/or primary renal causes. Prerenal azotemia reflects a reduced glomerular filtration rate (GFR), which is a consequence of renal hypoperfusion; it is not the result of structural renal damage. Immediate restoration of renal blood flow will reverse the azotemia over a period of time; however, if the hypoperfusion is severe or prolonged, or if there is prior renal dysfunction, acute primary renal failure due to ischemic acute tubular necrosis will be induced. Postrenal azotemia occurs when urine flow is obstructed or the excretory pathway is ruptured and there is subsequent urine resorption. Persistent urinary obstruction may cause irreversible renal damage. Early detection of postrenal azotemia will result in complete restoration of renal function. Acute tubular necrosis accounts for the majority of acute



**PATIENT**  
Chewbacca Ellrott

primary renal failure cases and is characterized by an abrupt and sustained reduction in GFR due to an ischemic or toxic renal insult. The conditions that incite ischemia are the same as those for prerenal azotemia; however, the duration of the ischemia is important. Nephrotoxins are a frequent cause of tubular necrosis. The high rates of blood flow and metabolic activity in the kidneys as well as their excretory function predispose dogs and cats to the toxic effects of drugs as well as endogenous or exogenous toxins.

**SPECIES**  
Canine

**BREED**  
Bichapoo

**SEX**  
Male

**AGE**  
4 years

**Clinical Signs:** The clinical course in acute tubular necrosis can be divided into three phases: an initiating phase, a maintenance phase, and a recovery phase. The initiating phase, which is marked by the onset of renal injury, is the period in which there is the greatest potential for preventing or reversing tubular damage and the progression to overt renal failure because it is during this period that renal cell damage develops. The challenge, however, is that the initiating phase may only become evident in retrospect as it generally lacks characteristic signs. The maintenance phase is characterized by the onset of oliguria (i.e., urine production is less than 1ml/kg/hour). The onset of this phase typically occurs during the first 24 hours, but may be delayed for up to 1 week. The duration of this phase is highly variable, but usually persists for up to 2 weeks. It is characterized by: fluid and electrolyte imbalances, including an alteration in hydration; hyponatremia; hyperkalemia; high anion gap metabolic acidosis; hypocalcemia; hyperphosphatemia; and azotemia. Clinical signs include gastrointestinal, hematological, and neurological manifestations of renal failure. The recovery phase commences when the GFR increases, which consequently slows down and reverses the azotemia. There is a progressive increase in urine volume, and although the tubular function begins to improve, it nevertheless remains impaired. Diuresis persists because of the diminished ability of the tubules to reabsorb sodium and respond to vasopressin. Clinical manifestations observed in the maintenance phase persist into the recovery phase. In some patients, infections and/or gastrointestinal bleeding may occur. Sites of infection include the respiratory tract, operative sites, and the urinary tract. Septicemia may also occur and is sometimes the result of intravenous and urinary indwelling catheters.

**INTERPRETED BY**  
Eric Lindquist, DMV  
DABVP, Cert. IVUSS

**IMAGING PERFORMED BY**  
Eric Lindquist, DMV  
DABVP, Cert. IVUSS

**HOSPITAL NAME**  
Andover AH

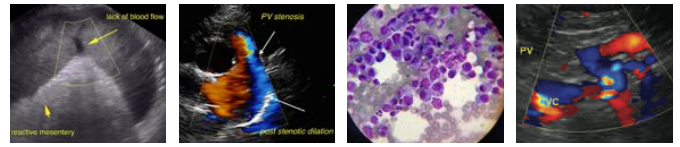
**REFERRING VET**  
Dr. Lind

**Diagnostics:** Extraordinary disorders that produce prerenal azotemia are associated with concentrated, hypersthenuric urine, which contains a relatively low concentration of sodium and high concentration of creatinine. ARF is typically characterized by enlarged or swollen kidneys, elevated hematocrit, and azotemia. Urine is isosthenuric or minimally concentrated, and contains high concentrations of creatinine. Proteinuria or glycosuria may also accompany this condition. The sediment will show casts and RTE cells. Complete anuria is usually associated with postrenal azotemia. Features that are typical for acute tubular necrosis include: anuria in the absence of a urinary tract obstruction or rupture; severe proteinuria; significant hematuria with red cell casts; and prolonged oliguria. In these cases, a diagnostic renal biopsy is indicated.

**INVOICE**  
96477

**DATE**  
3/1/22

**Treatment:** Most patients with ARF are volume depleted. Fluid therapy is indicated to correct dehydration, which will restore adequate renal perfusion and may prevent further renal damage. If the etiology was prerenal in origin, then urine volume will increase. In the maintenance phase, fluid therapy should be directed toward maintaining fluid balance and preventing both overhydration and dehydration. In cases of renal disease it is important that only maintenance needs and ongoing losses are attended to as overhydration can develop if there is reduced renal function. Insensible losses are calculated at 20 ml/kg/day. Aggressive fluid therapy during the recovery phase may perpetuate polyuria. As the urine volume stabilizes, the volume of fluid administered should be reduced correspondingly. Because dehydration may occur during this phase, one should monitor body weight and clinically assess the hydration status as fluid therapy is being reduced. Oliguric patients who are unresponsive to fluid volume replacement can be treated with mannitol, furosemide, and/or dopamine in an attempt to increase GFR



**PATIENT**

Chewbacca Ellrott

and urine volume. Hyperkalemia is commonly associated with the maintenance phase of ARF. Concentrations greater than 6 mmol/l may require treatment with sodium bicarbonate, dextrose, insulin and/or calcium gluconate. Hemodialysis should be considered in patients with severe, persistent uremia, acidosis, or hyperkalemia. It may also be used to treat overhydration and hasten the elimination of nephrotoxins.

**SPECIES**

Canine

**Conclusion:** Because ARF is frequently iatrogenic and associated with nephrotoxic drugs or inadequate fluid therapy, prevention is the best therapy.

**BREED**

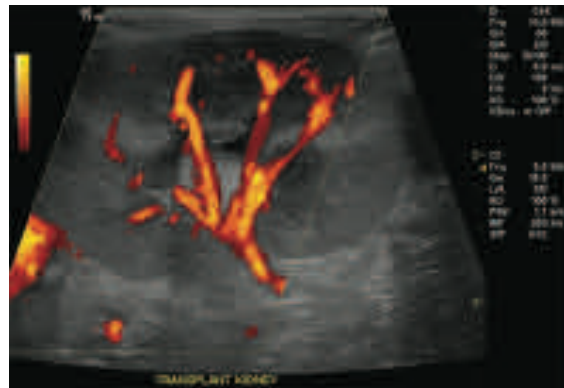Bichapoo

**SEX**

Male

**AGE**

4 years



Long axis of the kidney of the same cat as in the previous title image. Note the non-uniform power Doppler signal distribution with significant hypovascularity of the cranial pole compatible with regional infarction and transplant failure.

**INTERPRETED BY**

Eric Lindquist, DMV  
DABVP, Cert. IVUSS

**IMAGING PERFORMED BY**

Eric Lindquist, DMV  
DABVP, Cert. IVUSS

**References:**

Acierno MJ, Maeckelbergh V. Continuous renal replacement therapy. *Compend Contin Educ Vet* 2008;30:264-72.

Grauer GF. Early detection of renal damage and disease in dogs and cats. *Vet Clin North Am Small Anim Pract* 2005;35:581-96.

Labato MA. Strategies for management of acute renal failure. *Vet Clin North Am Small Anim Pract* 2001;31:1265-87.

Ross L. Acute kidney injury in dogs and cats. *Vet Clin North Am Small Anim Pract* 2011;41:1-14.

**HOSPITAL NAME**

Andover AH

**REFERRING VET**

Dr. Lind

**INVOICE**

96477

**DATE**

3/1/22