



PATIENT

Rudy Darling

SPECIES

Canine

BREED

Yorkie

SEX

Neutered male

AGE

13 years

WEIGHT

9.6 lbs

INTERPRETED BY

Eric Lindquist, DMV
DABVP, Cert. IVUSS

IMAGING PERFORMED BY

Megan Bray

HOSPITAL NAME

Taylorville VC

REFERRING VET

Dr. Earp

INVOICE

71402

DATE

2/9/26

PRESENTING CLINICAL SIGNS

- Evaluation of grade 4/6 heart murmur and anesthetic recommendations for dental cleaning.
- Newly diagnosed in June of 2025.

ULTRASONOGRAPHIC EXAMINATION OF THE HEART

The echocardiogram in this patient demonstrated enlarged **left atrial** size based on 3 different LA measurement methods. Chamber volumes and echogenicity were normal. The cranial and caudal **mitral** valve leaflets presented vegetative thickening consistent with endocardiosis. Prolapse of the anterior mitral valve leaflet was noted. Doppler indicated measurable insufficiency. The **left ventricle** presented normal thicknesses with linear contour and was not dilated nor restricted. The **myocardium** presented normal echogenicity without subjective evidence of significant fibrotic or ischemic disease. **Contractility** of the ventricular walls was adequate and in normal range for this patient evidenced by the fractional shortening measurement and subjective evaluation of the different regions of the myocardium. The **left ventricular outflow** tract demonstrated normal laminar flow and subjective structural integrity. The **right atrium** and auricle revealed normal size, structure and content. No evidence of masses was noted or chamber overload. **Tricuspid** valvular assessment demonstrated adequate linear morphology. The **right ventricle** was of normal size (1/3 diameter of LV), chordae structure, myocardial echogenicity and thickness. **Pulmonic** tract assessment revealed normal valve structure, laminar flow, and diameter (approx. 1:1 pa/ao ratio). No visible **pericardial** or free pleura fluid was noted. No echographically detectable evidence of infiltrative disease was visible. The cranial **mediastinum and pericardial regions** were free of masses in the visible window.

CANINE CARDIAC PARAMETERS	MR VMAX (m/s)	TR VMAX (m/s)	LA/AO	LA/AO (Heart Base)	FS (%)	EF (%)	EPSS (cm)
NORMAL PARAMETER	4.5-5.5	<2.7	1.3	<1.6	28-40	40-100	<0.6
PATIENT	NM	NM	1.5	1.9	50	80	0.1
CANINE CARDIAC PARAMETERS	HR (BPM)	AV VMAX (m/s)	PV MAX (m/s)	BODY WEIGHT	LA 2D short axis Base view (cm)	LVIDd Avg; 2D and m-mode short axis (cm)	LVIDs Avg; 2D and m-mode short axis (cm)
NORMAL PARAMETER	50-100	0.7-1.7	0.7-1.6	BELOW	BELOW	BELOW	BELOW
PATIENT	90	1.9	0.7	9.6 lbs	3.16	2.8	

ULTRASONOGRAPHIC FINDINGS

Stage B2 valvular disease with mitral valve prolapse.



PATIENT

Rudy Darling

SPECIES

Canine

BREED

Yorkie

SEX

Neutered male

AGE

13 years

WEIGHT

9.6 lbs

INTERPRETED BY

Eric Lindquist, DMV
DABVP, Cert. IVUSS

IMAGING PERFORMED BY

Megan Bray

HOSPITAL NAME

Taylorville VC

REFERRING VET

Dr. Earp

INVOICE

71402

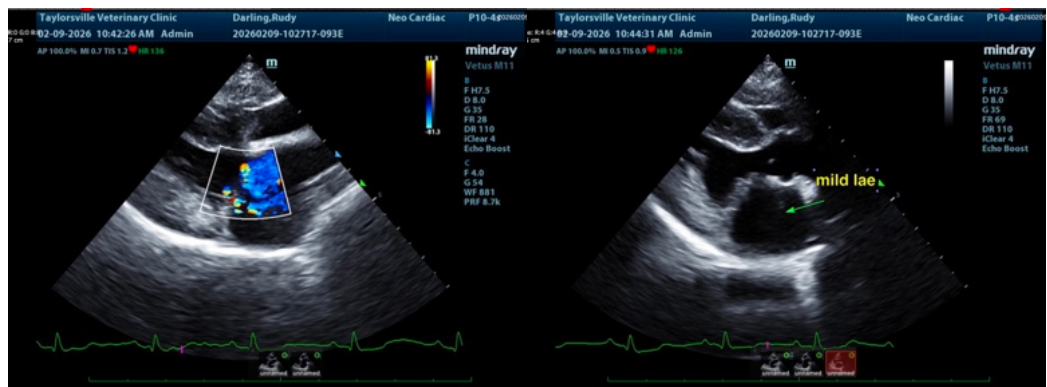
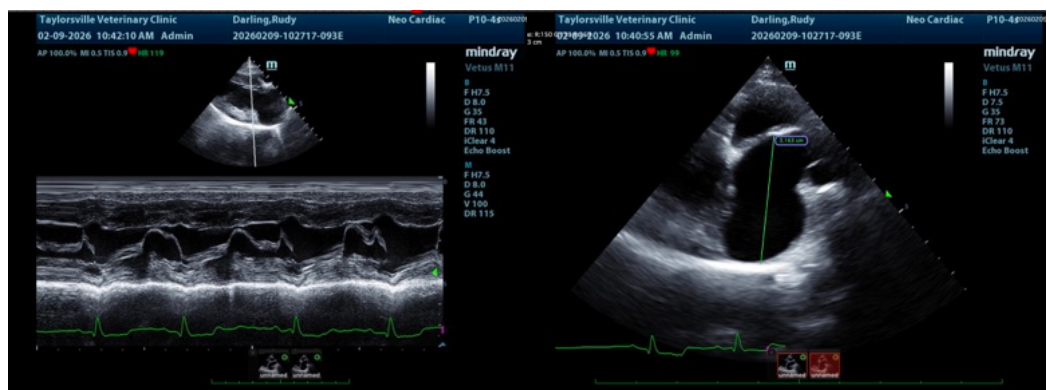
DATE

2/9/26

INTERPRETATION OF THE FINDINGS & FURTHER RECOMMENDATIONS

I recommend initiating Pimobendan at 0.3 mg/kg b.i.d. Blood pressure measurements are indicated. If systolic pressure is > 160, then ace inhibitor therapy can be considered.

The heart has minor volume overload and is working to compensate for the valvular insufficiency. Target respiratory rate is < 20 resp/minute after therapy. After initiating or adjusting therapy, I recommend recheck on the clinical exam, BUN, Creatinine, USG, Chest radiographs & Blood pressure in 5-7 days. Recheck echo in 3-6 months, earlier if clinical decompensation is occurring. Minor anesthetic risk for a brief procedure at this time. Repeat preanesthetic echo is ideal if anesthesia is eventually necessary. A suggested anesthetic combination would involve Torbutrol premed, propofol induction, Isoflurane maintenance or equivalent protocol.





PATIENT

Rudy Darling

SPECIES

Canine

BREED

Yorkie

SEX

Neutered male

AGE

13 years

WEIGHT

9.6 lbs

INTERPRETED BY

Eric Lindquist, DMV
DABVP, Cert. IVUSS

IMAGING PERFORMED BY

Megan Bray

HOSPITAL NAME

Taylorville VC

REFERRING VET

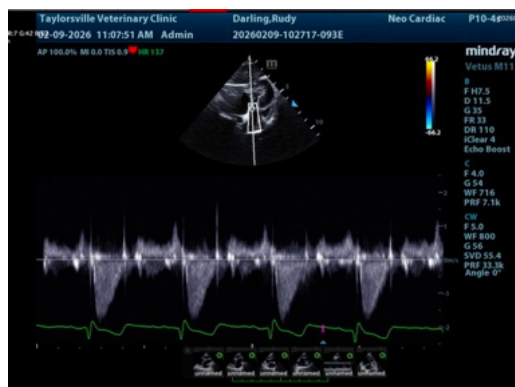
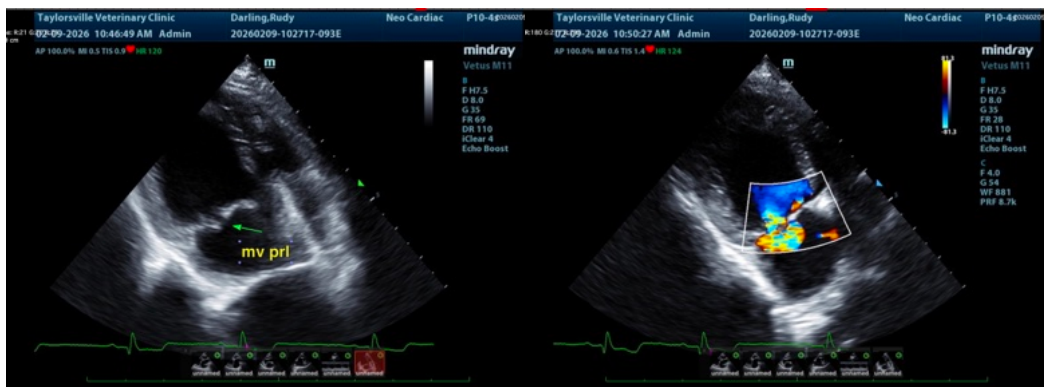
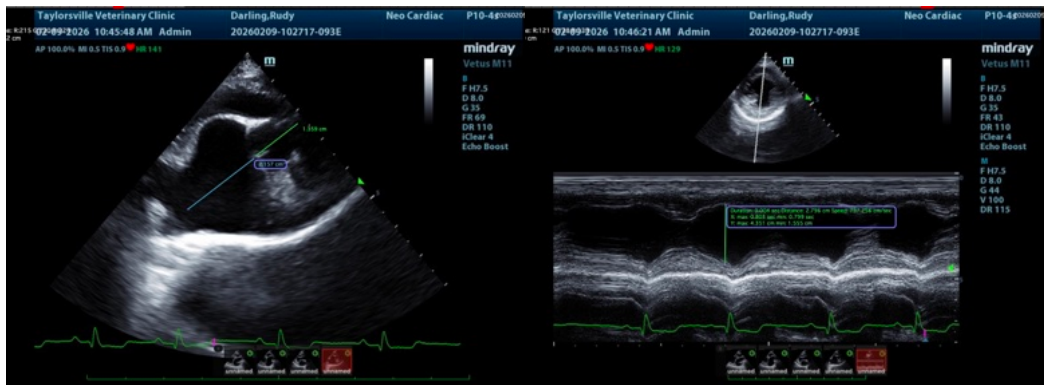
Dr. Earp

INVOICE

71402

DATE

2/9/26



The information and recommendations provided are based on the images presented by the referring veterinarian/sonographer. No evaluation can be communicated regarding pathology that was not visible in the image/video clips provided.

Thank you for this referral. If the clinical or image interpretation does not parallel your findings or if I can be of any further assistance please contact me.

Eric Lindquist, DMV, DABVP (CFM), Cert. IVUSS, CEO of SonoPath.com

info@SonoPath.com