



## PATIENT

Ruby Perry

## SPECIES

Canine

## BREED

Poodle x

## SEX

Spayed Female

## AGE

5

## WEIGHT

18

## INTERPRETED BY

Eric Lindquist, DMV,  
DABVP (CFM), Cert.  
IVUSS

## IMAGING PERFORMED BY

Jenn

## HOSPITAL NAME

Rockaway Animal  
Hospital

## REFERRING VET

Dr. Maniar

## INVOICE

72817

## DATE

2/9/26

## PRESENTING CLINICAL SIGNS

Got into garbage, Patient was fasted.

## ULTRASONOGRAPHIC EXAMINATION OF THE ABDOMEN

### Urinary System

The **urinary bladder**, trigone, and pelvic urethra presented normal thicknesses and normal tone. The ureters were not visible which is normal. No uroliths or sediment were visualized and anechoic urine was present. No evidence of inflammatory or neoplastic changes were noted. Ureteral papillae were normal.

The **kidneys** revealed normal size and structure, corticomedullary definition and ratio for this age. The cortices presented largely uniform texture with normal echogenic relationship to liver and spleen. Medullary structure differed distinctly from the cortex and no evidence of pelvic dilation was present. The capsules were acceptably uniform without significant irregularities. Right kidney measured 4.22 cm. Left kidney measured 4.71 cm.

### Adrenal Glands

Both **adrenal glands** were visualized and recognized as having normal shape, size, position and echogenicity for this breed. The phrenic vasculature, glandular echogenicity and detail were unremarkable. Capsule, cortex, and medullary definition were normal for this age patient. Right measures 1.4 cm x 0.66 cm at the cranial pole and 0.40 cm at the caudal pole. Left measured 2.5 cm x 0.49 cm at the caudal pole and 0.49 cm at the cranial pole.

### Spleen

The **spleen** presented a smooth homogeneous parenchyma hyperechoic to liver and renal cortical parenchyma. The capsule was smooth without noticeable expansion or deviation from within the spleen or adjacent pathology. The splenic vasculature demonstrated normal volume without signs of congestion or thrombosis. No sonographic evidence of acute or chronic inflammatory, neoplastic, or infarctual changes were noted.

### Liver

The **liver** images submitted revealed subjectively normal liver size, contour, and structure. Parenchymal echogenicity was naturally coarse and hypoechoic to the spleen. Vascular and biliary tracts were of normal volume with no evidence of congestion. The gallbladder presented acceptably thin walls with primarily anechoic content. The cystic and common bile ducts were normal. No pathological hepatic lymphadenopathy was evident. No overt structural evidence of inflammatory, infiltrative or regenerative pathology was evident.

### Gastrointestinal

The **stomach** revealed lumen filled with ingesta and shadowing structures measuring up to 1.1 cm. These may represent kibble or soft foreign matter. The small intestines and colon were unremarkable with normal curvilinear mural patterns and content.



**PATIENT**

Ruby Perry

**SPECIES**

Canine

**BREED**

Poodle x

**SEX**

Spayed Female

**AGE**

5

**WEIGHT**

18

**INTERPRETED BY**

Eric Lindquist, DMV,  
DABVP (CFM), Cert.  
IVUSS

**IMAGING PERFORMED BY**

Jenn

**HOSPITAL NAME**

Rockaway Animal  
Hospital

**REFERRING VET**

Dr. Maniar

**INVOICE**

72817

**DATE**

2/9/26

**Pancreas**

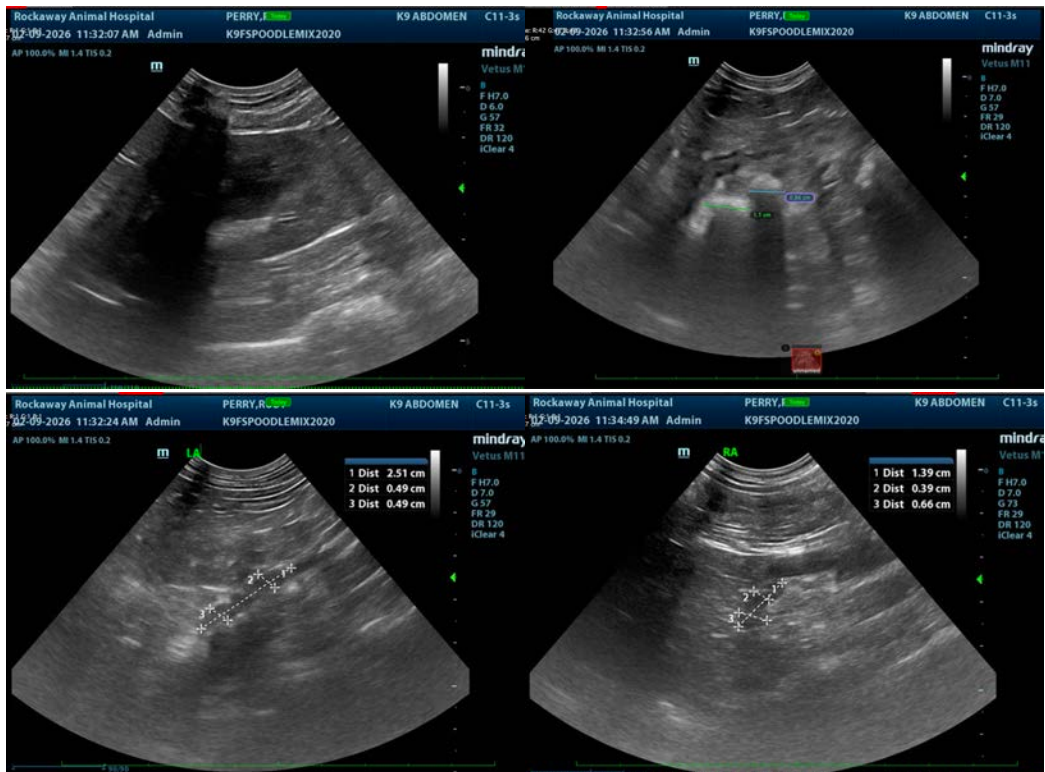
The base and limbs of the **pancreas** were observed to be largely isoechoic to surrounding omental fat. Pancreatic duct and capsular contour were acceptably normal and parenchyma respected normal curvilinear patterns. No overt evidence of active inflammatory or neoplastic disease was noted.

**ULTRASONOGRAPHIC FINDINGS**

- Full stomach with slight shadowing material, consistent with ingesta and/or possible small foreign matter.

**INTERPRETATION OF THE FINDINGS & FURTHER RECOMMENDATIONS**

Induction of vomiting would be recommended if the patient was NPO at the time of the sonogram. Medical management with recheck sonogram after 24 hour NPO recommended to assess persistence of material in the stomach.



The information and recommendations provided are based on the images presented by the referring veterinarian/sonographer. No evaluation can be communicated regarding pathology that was not visible in the image/video clips provided.

Thank you for this referral. If the clinical or image interpretation does not parallel your findings or if I can be of any further assistance please contact me.

**Eric Lindquist, DMV, DABVP(CFM), Cert. IVUSS,**  
CEO, Owner, Founder -- SonoPath.com  
[info@SonoPath.com](mailto:info@SonoPath.com)