

PATIENT

Matcho Savarino

SPECIES

Canine

BREED

German Shepherd

SEX

Neutered male

AGE

9 years

WEIGHT

91 lbs

INTERPRETED BY

Eric Lindquist, DMV
DABVP, Cert. IVUSS

IMAGING PERFORMED BY

Chelsea Pastor

HOSPITAL NAME

Fredon AH

REFERRING VET

Dr. Grau

INVOICE

71401

DATE

2/9/26

PRESENTING CLINICAL SIGNS

- Increase in vomiting, pet had GDV and splenectomy in 2022; life threatening GGI bleed with gastrectomy to resect ulcer after numerous transfusions at Oradell 3/2024.
- Unremarkable, CBC/Chem/CPL all WNL

ULTRASONOGRAPHIC EXAMINATION OF THE ABDOMEN

Urinary System

The **urinary bladder**, trigone, and pelvic urethra presented normal thicknesses and normal tone. The ureters were not visible which is normal. No uroliths or sediment were visualized and anechoic urine was present. No evidence of inflammatory or neoplastic changes was noted. Ureteral papillae were normal.

The **kidneys** revealed normal size and structure, corticomedullary definition and ratio for this age. The cortices presented largely uniform texture with normal echogenic relationship to liver and spleen. Medullary structure differed distinctly from the cortex and no evidence of pelvic dilation was present. The capsules were acceptably uniform without significant irregularities. The left kidney measured 8.3 cm. The right kidney measured 7.0 cm.

Adrenal Glands

The left **adrenal gland** was visualized and recognized as having normal shape, size, position and echogenicity for this breed. The phrenic vasculature, glandular echogenicity and detail were unremarkable. Capsule, cortex, and medullary definition were normal for this age patient. The left adrenal gland measured 0.6 cm. The right adrenal gland was not visualized.

Spleen

The **spleen** was not visualized as it was previously removed. The region of the splenic fossa was unremarkable. There was no return of prior pathology.

Liver

The **liver** images submitted revealed subjectively normal liver size, contour, and structure. Parenchymal echogenicity was naturally coarse and hypoechoic to the spleen. Vascular and biliary tracts were of normal volume with no evidence of congestion. The gallbladder presented acceptably thin walls with primarily anechoic content. The cystic and common bile ducts were normal. No pathological hepatic lymphadenopathy was evident. No overt structural evidence of inflammatory, infiltrative or regenerative pathology was evident.



PATIENT

Matcho Savarino

SPECIES

Canine

BREED

German Shepherd

SEX

Neutered male

AGE

9 years

WEIGHT

91 lbs

INTERPRETED BY

Eric Lindquist, DMV
DABVP, Cert. IVUSS

IMAGING PERFORMED BY

Chelsea Pastor

HOSPITAL NAME

Fredon AH

REFERRING VET

Dr. Grau

INVOICE

71401

DATE

2/9/26

Gastrointestinal

The **stomach** presented minor hypertrophy with pyloric outflow. Retention of ingesta was noted. The gastric wall measured 0.9 cm. There was no loss of mural detail. The pyloric angle appeared to be in proper position. The small intestines and colon were unremarkable with normal curvilinear mural patterns and content.

Pancreas

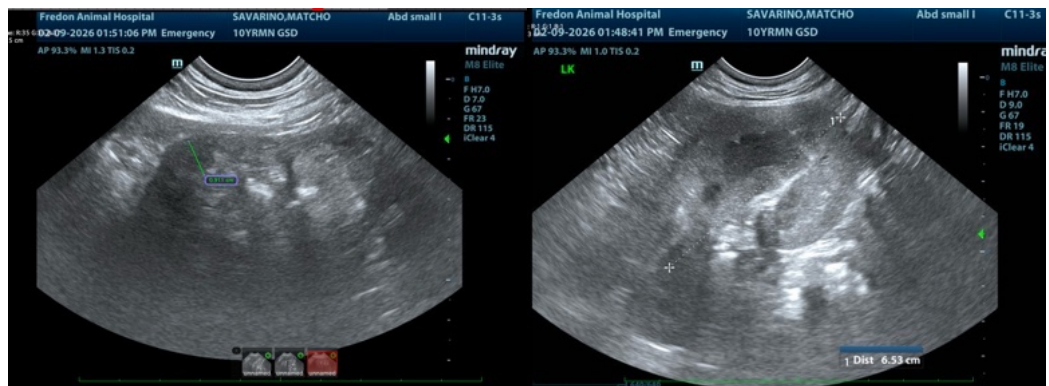The base and limbs of the **pancreas** were observed to be largely isoechoic to surrounding omental fat. Pancreatic duct and capsular contour were acceptably normal and parenchyma respected normal curvilinear patterns. No overt evidence of active inflammatory or neoplastic disease was noted.

ULTRASONOGRAPHIC FINDINGS

Structurally unremarkable abdomen.

INTERPRETATION OF THE FINDINGS & FURTHER RECOMMENDATIONS

There was no evidence of pathology.





PATIENT

Matcho Savarino

SPECIES

Canine

BREED

German Shepherd

SEX

Neutered male

AGE

9 years

WEIGHT

91 lbs

INTERPRETED BY

Eric Lindquist, DMV
DABVP, Cert. IVUSS

IMAGING PERFORMED BY

Chelsea Pastor

HOSPITAL NAME

Fredon AH

REFERRING VET

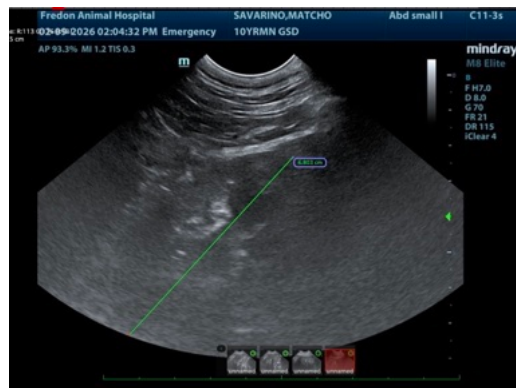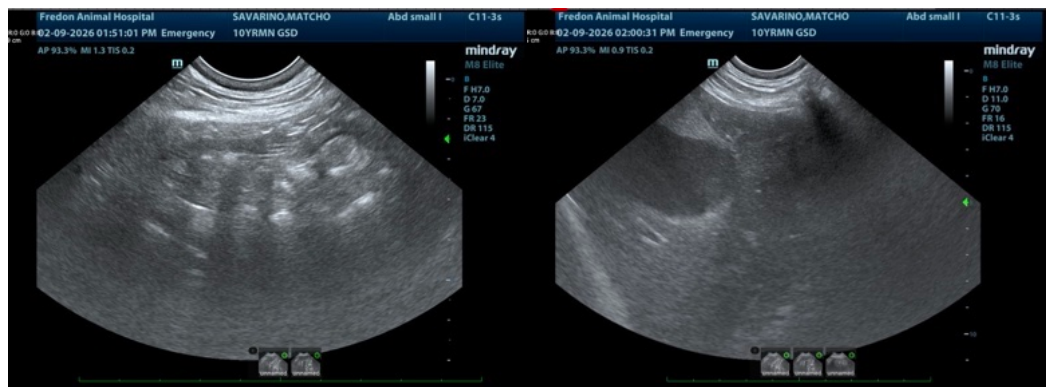
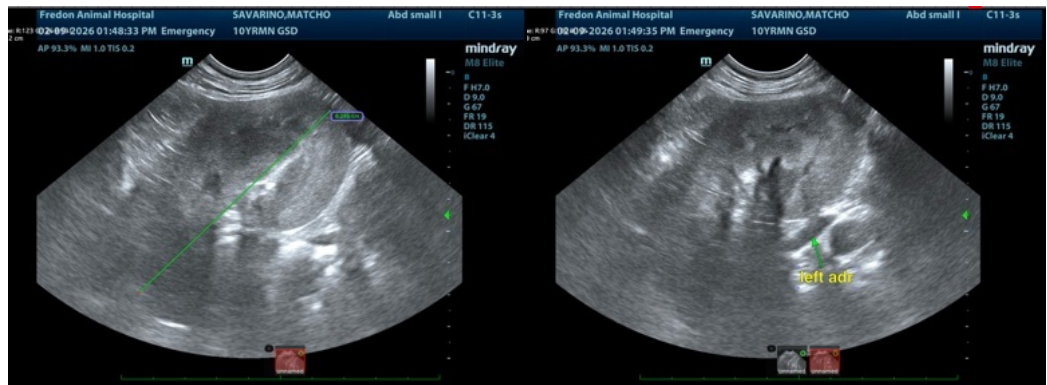
Dr. Grau

INVOICE

71401

DATE

2/9/26



The information and recommendations provided are based on the images presented by the referring veterinarian/sonographer. No evaluation can be communicated regarding pathology that was not visible in the image/video clips provided.

Thank you for this referral. If the clinical or image interpretation does not parallel your findings or if I can be of any further assistance please contact me.

Eric Lindquist, DMV, DABVP (CFM), Cert. IVUSS, CEO of SonoPath.com

info@SonoPath.com