



PATIENT

Abby Breyer

SPECIES

Feline

BREED

Domestic Shorthair

SEX

Spayed female

AGE

14 years

WEIGHT

10.8 lbs

INTERPRETED BY

Eric Lindquist, DMV
DABVP, Cert. IVUSS

IMAGING PERFORMED BY

Dr. Christensen

HOSPITAL NAME

Tranquility VC

REFERRING VET

Dr. Christensen

INVOICE

71417

DATE

2/9/26

PRESENTING CLINICAL SIGNS

- Unable to put weight on left front leg for past few months.
- No know trauma but owner reports acute swelling of left carpus a few months ago. Unable to examine because of aggression. Brought to RDVM and did x-rays and suspected heart disease and tumor on carpus.
- NO SWELLING ON CARPUS but noticeable valgus that is "frozen" in place. No murmur.
- Suspect enlarged heart on x-ray is do to pectus excavatum?
- Owner wants to be sure there is no internal disease before carpal arthrodesis or amputation is pursued.

ULTRASONOGRAPHIC EXAMINATION OF THE HEART

The echocardiogram in this patient demonstrated normal **left atrial** size based on 3 separate LA measurements. The cranial and caudal **mitral** valve leaflets presented normal linear structure and kinetics.. The **left ventricle** presented normal thicknesses with linear contour and was not dilated nor restricted. The **myocardium** presented normal echogenicity without subjective evidence of significant fibrotic or ischemic disease. **Contractility** of the ventricular walls was adequate and in normal range for this patient evidenced by the fractional shortening measurement and subjective evaluation of the different regions and angles of the myocardium. The **left ventricular outflow** tract demonstrated normal laminar flow and subjective structural integrity. The **right atrium** and auricle revealed normal size, structure and content. No evidence of masses was noted or chamber overload. **Tricuspid** valvular assessment demonstrated adequate linear morphology and kinetics. The **right ventricle** was of normal size (1/3 diameter of LV), chordae structure, myocardial echogenicity and thickness. **Pulmonic** tract assessment revealed normal valve structure, laminar flow, and diameter (approx.1:1 pa/ao ratio). No visible **pericardial** or free pleura fluid was noted or extra cardiac pathology in the visible planes. The cranial **mediastinum and pericardial regions** were free of masses in the visible window.

FELINE CARDIAC PARAMETERS	BODY WEIGHT	HR (BPM)	IVSd (cm)	LVIDd (cm)	LVWd (cm)	FS (%)	EF (%)
NORMAL PARAMETER	-----	150-240	0.3-0.6	1.0-2.1	0.25-0.6	35-67	80-100
PATIENT	10.8 lbs	NM	0.64	1.2	0.6	30	83
FELINE CARDIAC PARAMETERS	LA/AO (M-mode)	LA/AO HEART BASE (Sisson)	LAD LA MAX 4 Chamber		LVOT VEL. (m/s)	RVOT VEL. (m/s)	IVRT (m/)
NORMAL PARAMETER	<1.5	1.6	0.7-1.7		<1.6	<1.3	40-60
PATIENT	1.34	1.1	1.2		NM	NM	NM
Adapted from June Boon, Veterinary Echocardiography, 1998 Sisson D et al. JVIM 1991; 5: 232, Jacobs et al. Am J Vet Res 1985; 46:1705							



PATIENT

Abby Breyer

SPECIES

Feline

BREED

Domestic Shorthair

SEX

Spayed female

AGE

14 years

WEIGHT

10.8 lbs

INTERPRETED BY

Eric Lindquist, DMV
DABVP, Cert. IVUSS

IMAGING PERFORMED BY

Dr. Christensen

HOSPITAL NAME

Tranquility VC

REFERRING VET

Dr. Christensen

INVOICE

71417

DATE

2/9/26

ULTRASONOGRAPHIC EXAMINATION OF THE ABDOMEN

Urinary System

The **urinary bladder**, trigone, and pelvic urethra presented normal thicknesses and normal tone. The pelvic urethra was imaged 3.0 cm beyond the cystourethral junction and appeared normal. The ureters were not visible which is normal. No uroliths or sediment were visualized and anechoic urine was present. No evidence of inflammatory or neoplastic changes was noted. Ureteral papillae were normal.

The **kidneys** revealed largely normal size and structure, corticomedullary definition and ratio (cortex 1/3 of medulla) were essentially maintained with some age-related loss of curvilinear patterns regarding the capsule and C/M junction. The cortices presented largely uniform texture with some increased echogenicity expected for this age patient. Medullary structure differed distinctly from that of the cortex and no evidence of pelvic dilation was present. The left kidney measured 3.74 cm.

Adrenal Glands

Both **adrenal glands** were visualized and recognized as having normal shape, size, position and echogenicity for this breed. The phrenic vasculature, glandular echogenicity and detail were unremarkable. Capsule, cortex, and medullary definition were normal for this age patient. The left adrenal gland measured 0.43 cm.

Spleen

The **spleen** presented a smooth homogeneous parenchyma hyperechoic to liver and renal cortical parenchyma. The capsule was smooth without noticeable expansion or deviation from within the spleen or adjacent pathology. The splenic vasculature demonstrated normal volume without signs of congestion or thrombosis. No sonographic evidence of acute or chronic inflammatory, neoplastic, or infarctual changes was noted.

Liver

The **liver** images from right and left intercostal as well as subcostal views revealed subjectively normal liver size, contour, and structure. A multi-focal, hypoechoic nodule was noted measuring up to 1.6 cm in the cranial liver. Some age-related parenchymal remodeling was noted but likely not clinically significant at this time. Vascular and biliary tracts were of normal volume and no evidence of congestion was noted. The gallbladder presented some dependent debris with essentially normal contour. The cystic and common bile ducts were normal. No overt evidence of active inflammatory, infiltrative or regenerative pathology was noted but should be paired with current or past LE elevations regarding any clinical significance to this presentation. The hepatic lymph nodes were unremarkable.



PATIENT

Gastrointestinal

Abby Breyer

The **gastrointestinal tract** revealed minor variable thickening and echogenic submucosal changes most consistent with low grade end result of chronic GI disease such as IBD and may be related to malassimilation of nutrients if any weight loss is present. No obvious neoplastic patterns were noted and luminal content as unremarkable.

SPECIES

Feline

BREED

Pancreas

Domestic Shorthair

The base and limbs of the **pancreas** were observed to be largely isoechoic to surrounding omental fat. Pancreatic duct and capsular contour were acceptably normal and parenchyma respected normal curvilinear patterns. No overt evidence of active inflammatory or neoplastic disease was noted.

SEX

Spayed female

AGE

ULTRASONOGRAPHIC FINDINGS

14 years

Geriatric abdomen with undefined liver nodule. Hyperplasia, necrosis, abscessation, carcinoma, round cell neoplasia are all potentials in this patient.

WEIGHT

10.8 lbs

Normal cardiac exam.

INTERPRETED BY

INTERPRETATION OF THE FINDINGS & FURTHER RECOMMENDATIONS

Eric Lindquist, DMV
DABVP, Cert. IVUSS

FNA of the liver nodule is indicated.

IMAGING PERFORMED BY

Dr. Christensen

HOSPITAL NAME

Tranquility VC

REFERRING VET

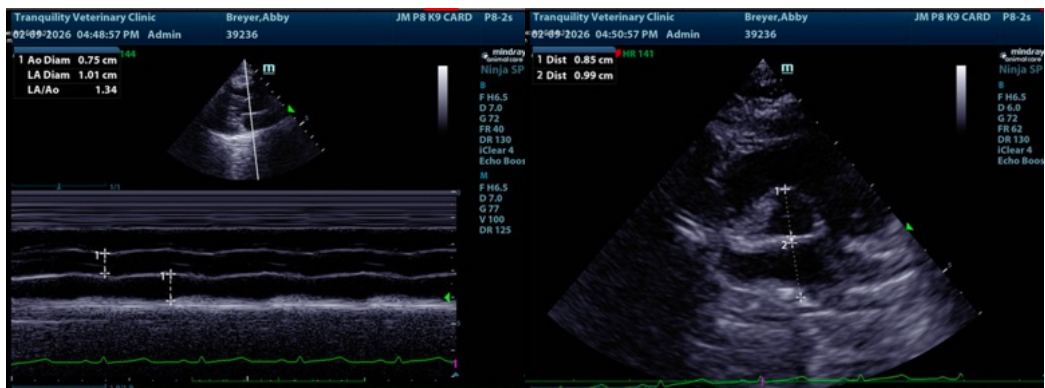
Dr. Christensen

INVOICE

71417

DATE

2/9/26





PATIENT

Abby Breyer

SPECIES

Feline

BREED

Domestic Shorthair

SEX

Spayed female

AGE

14 years

WEIGHT

10.8 lbs

INTERPRETED BY

Eric Lindquist, DMV
DABVP, Cert. IVUSS

IMAGING PERFORMED BY

Dr. Christensen

HOSPITAL NAME

Tranquility VC

REFERRING VET

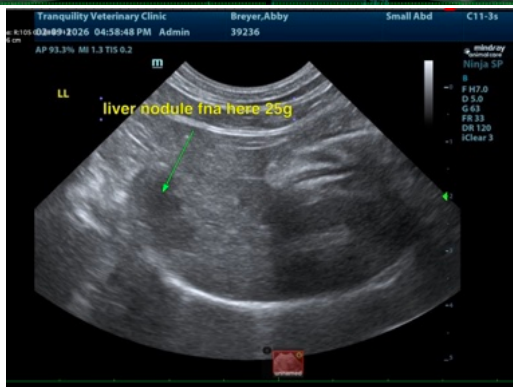
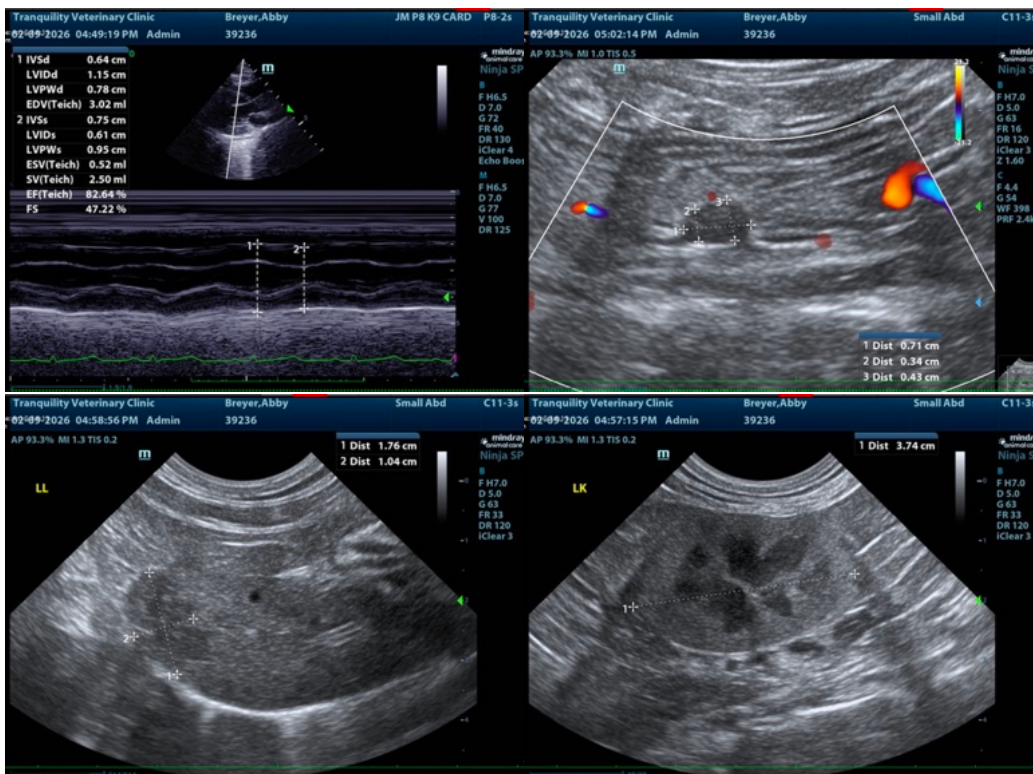
Dr. Christensen

INVOICE

71417

DATE

2/9/26



The information and recommendations provided are based on the images presented by the referring veterinarian/sonographer. No evaluation can be communicated regarding pathology that was not visible in the image/video clips provided.

Thank you for this referral. If the clinical or image interpretation does not parallel your findings or if I can be of any further assistance please contact me.

Eric Lindquist, DMV, DABVP (CFM), Cert. IVUSS, CEO of SonoPath.com

info@SonoPath.com