

**DATE**

2/9/23

PATIENT

Penny Lafleche

SPECIES

Canine

BREED

Bichon X

SEX

Spayed Female

AGE

11/8/13

WEIGHT

17 Pounds

INTERPRETED BYEric Lindquist, DMV
DABVP, Cert. IVUSS**HOSPITAL NAME**

Bayside AMC

REFERRING VET

Dr. Oliver

INVOICE

45020

PRESENTING CLINICAL SIGNS

Chronic proteinuria w/elevated UPC, elevation in ALP/ALT, history of pancreatitis, currently dog doing well and not symptomatic, has been on Benazepril and Telmisartan chronically for proteinuria, Denamarin for elevated LFTs, owner here for second opinion and AUS recommended

Current Medications: Benazapril, Telmisartan, Denamarin.

Date of Previous IntraPet Ultrasound: No previous.

Sedation: Not required to complete full diagnostic ultrasound.

Stat Report: Not requested.

Imaging Performed By: Rachel Brillhart, RDMS.

ULTRASONOGRAPHIC EXAMINATION OF THE ABDOMEN**Urinary System**

The **urinary bladder**, trigone, and pelvic urethra presented normal thicknesses and normal tone. The ureters were not visible which is normal. No uroliths or sediment were visualized and anechoic urine was present. No evidence of inflammatory or neoplastic changes were noted. Ureteral papillae were normal.

The **kidneys** revealed normal size and structure, corticomedullary definition and ratio for this age. The cortices presented largely uniform texture with normal echogenic relationship to liver and spleen. Medullary structure differed distinctly from the cortex. The capsules were acceptably uniform without significant irregularities. The right kidney measured 4.98 cm with slight pyelectasia of 0.12 cm. The left kidney measures 4.5 cm with slight pyelectasia at 0.16 cm.

Adrenal Glands

Both **adrenal glands** were visualized and recognized as having normal shape, size, position and echogenicity for this breed. The phrenic vasculature, glandular echogenicity and detail were unremarkable. Capsule, cortex, and medullary definition were normal for this age patient. The right adrenal gland measures 2.06 cm x 0.60 cm at the caudal pole and 0.60 cm at the cranial pole. The left adrenal gland measured 2.25 cm x 0.74 cm at the caudal pole and 0.72 cm at the cranial pole.

Spleen

The **spleen** presented a smooth homogeneous parenchyma hyperechoic to liver and renal cortical parenchyma. The capsule was smooth without noticeable expansion or deviation from within the spleen or adjacent pathology. The splenic vasculature demonstrated normal volume without signs of congestion or thrombosis. No sonographic evidence of acute or chronic inflammatory, neoplastic, or infarctual changes were noted.

Liver

The **liver** was uniformly swollen with minor, excessive gallbladder debris and over distension with dependent and suspended bile without evidence of overt mucocele formation. However, excessive sludge was present. The liver presented coarse architecture with mildly increased portal markings and subtle, mixed echogenic changes. This is consistent with vacuolar hepatopathy and some level of remodeling and history of inflammatory component. There was no overt suspicion of neoplasia.

Gastrointestinal

Examination of the **gastrointestinal tract** revealed a stomach and intestine free of stasis, of normal wall thickness, acceptable curvilinear mural detail, and peristaltic activity. Small and large intestine demonstrated normal luminal chyme and stool consistency respectively. No obstructive or overt infiltrative disease was noted. No associated abnormal lymphatic activity was noted.

Pancreas

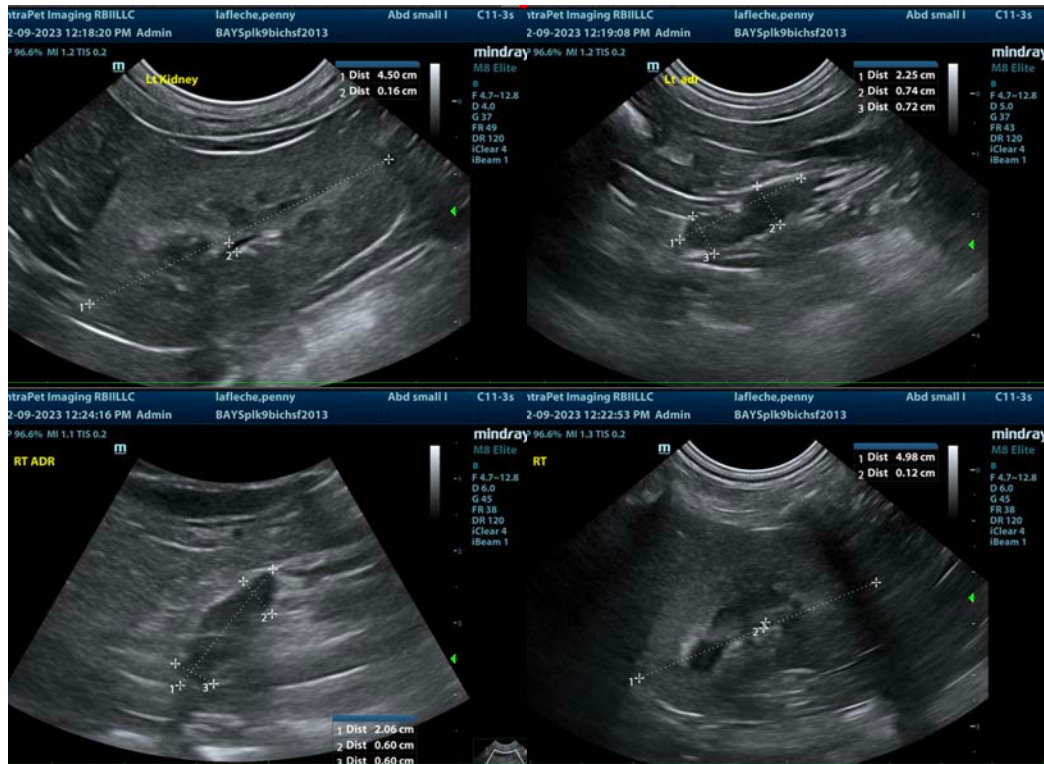
The base and limbs of the **pancreas** were observed to be largely isoechoic to surrounding omental fat. Pancreatic duct and capsular contour were acceptably normal and parenchyma respected normal curvilinear patterns. No overt evidence of active inflammatory or neoplastic disease was noted.

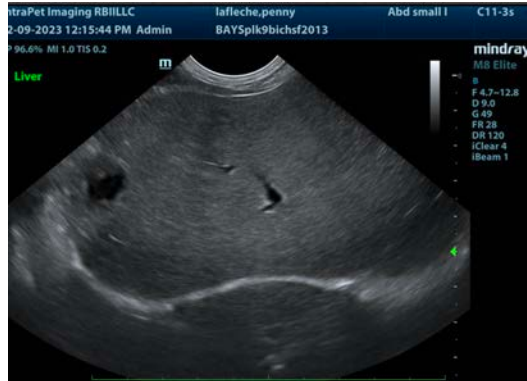ULTRASONOGRAPHIC FINDINGS

- Structurally unremarkable abdomen with non-specific age related renal and hepatic changes

INTERPRETATION OF THE FINDINGS & FURTHER RECOMMENDATIONS

Doxycycline trial could be considered. Blood pressure measurements indicated. Largely expected changes for this age and breed. Urine culture and sensitivity warranted if any inflammatory sediment is present on the urinalysis +/- Enrofloxacin trial could be considered as well as potential indirect approach with reduction of dietary antigenicity such as a hydrolyzed trial over a 6 week period and reassess. However, that intervention is completely empirical.





The information and recommendations provided are based on the images presented by the referring veterinarian/sonographer. No evaluation can be communicated regarding pathology that was not visible in the image/video clips provided.

Thank you for this referral. If the clinical or image interpretation does not parallel your findings or if I can be of any further assistance please contact me.

Eric Lindquist, DMV, DABVP, Cert. IVUSS, CEO of SonoPath.com
info@SonoPath.com